

The Official Journal of the American Academy of Cosmetic Dentistry<sup>®</sup>

# JOURNAL of Cosmetic Dentistry



---

VOLUME 25 • NUMBER 3  
FALL SPECIAL ISSUE 2009

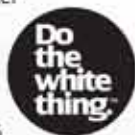# DO THE LIGHT THING

## With the World's Leading Chairside Whitening System

With 85% of patients wanting whiter teeth, Zoom answers this demand.\* People prefer light-activated treatment 10 to 1 for professional whitening.\* Give patients the results they expect – 8 shades in 45 minutes.†

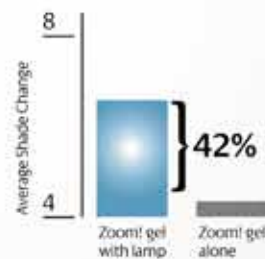
Clinical studies prove it's the most effective in-office whitening system. It gets teeth whiter, faster and keeps them whiter longer. With 2 million smiles and growing, leading dentists have made Zoom the world's leading whitening system.

Zoom. Do the light thing.

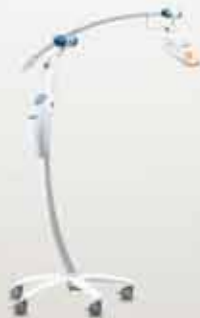

### Whiter Longer

42% whiter 30 days after treatment than with gel alone\*



**ZOOM!**  
World's Leading Chairside Whitening System



800-422-9448 | [discusdental.com](http://discusdental.com)

DISCUS DENTAL®

\*Data on file. †Not including preparation time. © 2009 Discus Dental, LLC. ADN2191100104

# JOURNAL of Cosmetic Dentistry

## EDITOR

Michael J. Koczarski, DDS, Woodinville, WA

## EDITORIAL REVIEW BOARD

Sunil Bhooralbhai, DDS, BDS, AAACD, Mumbai, India  
David R. Bloom, BDS, Watford, Hertfordshire, UK  
Michael W. Davis, DDS, Santa Fe, NM  
Hugh D. Flax, DDS, AAACD, Atlanta, GA  
Steve D. Hoofard, CDT, Hermiston, OR  
Nelson Y. Howard, DDS, AAACD, San Marcos, CA  
Ronald D. Jackson, DDS, FAACD, Middleburg, VA  
John C. Kois, DMD, MSD, Seattle, WA  
Gerard Kugel, DMD, MS, Lexington, MA  
Trevor R. Laingchild, RDT, AAACD, Burlington, ON, Canada  
Dean W. Loddington, DDS, AAACD, Elgin, IL  
Ed Lowe, DMD, AAACD, Vancouver, BC, Canada  
Michael T. Morris, CDT, FAACD, Lexington, KY  
Thomas W. Nabors, III, DDS, AAACD, Nashville, TN  
Trisha O'Hehir, RDH, Phoenix, AZ  
Christopher Orr, BDS, London, UK  
Shannon Pace Brinker, CDA, CDD, Chesapeake, VA  
Laurie Parker, Boise, ID  
Christopher Pescatore, DMD, Danville, CA  
Gary M. Radz, DDS, Denver, CO  
Christopher D. Ramsey, DMD, AAACD, Jupiter, FL  
Nelson A. Rego, CDT, AAACD, Santa Fe Springs, CA  
Alan H. Richardson, Anacortes, WA  
Dwight G. Rickert, CDT, AAACD, Indianapolis, IN  
Robert G. Ritter, DMD, Jupiter, FL  
Michael R. Sesemann, DDS, FAACD, Omaha, NE  
Trent Smallwood, DDS, Tempe, AZ  
Rhys D. Spoor, DDS, AAACD, Seattle, WA  
Thomas T. Teel, DDS, Fort Wayne, IN  
Thomas F. Trinkner, DDS, AAACD, Columbia, SC  
Dennis J. Wells, DDS, AAACD, Brentwood, IN  
Marty Zase, DMD, AAACD, Colchester, CT

## CONTRIBUTING EDITORS

Simona Cuevas, DDS, San Antonio, TX  
James H. Hastings, DDS, AAACD, Washington, IA  
Ed Lowe, DMD, AAACD, Vancouver, BC  
Rebecca K. Pitts, DMD, FAACD, Lake Mary, FL  
Sandra R. Roth, Brooksville, FL

## PUBLISHER

American Academy of Cosmetic Dentistry  
5401 World Dairy Drive, Madison, WI 53718  
800.543.9220 • 608.222.8583  
fax 608.222.9540 • info@aacd.com • www.aacd.com

## DIRECTOR OF PUBLICATIONS

Tracy Skenandore, tracs@aacd.com

## PUBLICATIONS ASSISTANT

Denise Sheriff, denises@aacd.com

## EDITORIAL CONSULTANT

Juliette Kurtz, publications@aacd.com

## DIRECTOR OF STRATEGIC PARTNERSHIPS

Jeff Roach, jeffr@aacd.com

## ART DIRECTOR

Lynnette Rogers, lynnetter@aacd.com

## 2009-2010

## EXECUTIVE COMMITTEE

### PRESIDENT

Michael R. Sesemann, DDS, FAACD, Omaha, NE

### PRESIDENT-ELECT

Hugh D. Flax, DDS, AAACD, Atlanta, GA

### VICE PRESIDENT

John K. Sullivan, DDS, AAACD, Tulare, CA

### IMMEDIATE PAST PRESIDENT

Mickey E. Bernstein, DDS, AAACD, Germantown, TN

### EXECUTIVE DIRECTOR

Ed Simeone, CMP, CMM, Madison, WI

### CHIEF OPERATING OFFICER

John Hanson, CPA, Madison, WI

## BOARD OF DIRECTORS

Thomas G. Berry, DDS, Denver, CO

John R. Calamia, DMD, New York, NY

William M. Dorfman, DDS, FAACD, Los Angeles, CA

Chiann Fan Gibson, DMD, Sugar Grove, IL

Ronald M. Goodlin, DDS, AAACD, Aurora, ON, Canada

Viviane S. Haber, DDS, Glendora, CA

James H. Hastings, DDS, AAACD, Placerville, CA

Andre Michel, CDT, AAACD, Dana Point, CA

Shannon Pace Brinker, CDA, CDD, Chesapeake, VA

Jack Ringer, DDS, AAACD, Anaheim Hills, CA

Wesley J. Ulrich, DDS, AAACD, Bayport, MN

## AMERICAN BOARD OF COSMETIC DENTISTRY

Elizabeth M. Bakeman, DDS, FAACD, Grand Rapids, MI, Chair

Rod W. Gore, DDS, AAACD, Scottsdale, AZ

Susan Hollar, DDS, AAACD, Arlington, TX

Bradley J. Olson, DDS, FAACD, Waldorf, MD

Nelson Rego, CDT, AAACD, Santa Fe Springs, CA

J.A. Reynolds, DDS, AAACD, Franklin, TN

John F. Weston, DDS, FAACD, La Jolla, CA

## BOARD OF TRUSTEES

Randy R. Mitchmore, DDS, Houston, TX, Chair

Lawrence M. Addleson, DDS, FAACD, San Diego, CA

Joyce L. Basset, DDS, AAACD, Scottsdale, AZ

Jorge R. Blanco, DDS, AAACD, South Miami, FL

Lena T. Halikias, DDS, Oak Forest, IL

Phillip A. Kemp, DDS, Brentwood, TN

Alexander H. Nguyen, DDS, AAACD, Saratoga, CA

C. Lee Wyant, DDS, AAACD, Little Rock, AR

TABLE OF CONTENTS

JOURNAL OF COSMETIC DENTISTRY • VOLUME 25 NUMBER 3 • FALL 2009

2009-2010 BOARD OF DIRECTORS AND AMERICAN BOARD OF COSMETIC DENTISTRY.....3

EDITOR'S MESSAGE ♦ BY MICHAEL J. KOZARSKI, DDS.....6

PRESIDENT'S MESSAGE ♦ BY MICHAEL R. SESEMANN, DDS, FAACD.....8

ABOUT THE COVER ♦ BY ROBERT G. RITTER, DMD & NELSON A. REGO, CDT, AAACD.....10

---

26TH ANNUAL AACD SCIENTIFIC SESSION.....14

THE LEARNING REVOLUTION AND THE DENTAL LABORATORY PROGRAM FOR 2010 ♦ BY GILBERT YOUNG, CDT, AAACD.....15

---

25TH ANNIVERSARY AACD SCIENTIFIC SESSION RECAP.....17

MAXIMIZING ESTHETIC RESULTS WITH THE USE OF PREPARATION MATRICES ♦ BY JOYCE L. BASSETT, DDS, FAGD, AAACD.....18

IN-OFFICE MODEL PREPARATION FOR COSMETIC SMILE DESIGN  
AND VIRTUAL TRY-INS ♦ BY MITCH A. CONDITT, DDS & MICHAEL L. MILNE, CDT.....24

ON TARGET: PART 1—CREATING SYSTEMS FOR SUCCESS IN A CHANGING WORK ENVIRONMENT ♦ BY CATHY JAMESON.....32

LABORATORY TECHNICIAN ACCREDITATION WORKSHOP ♦ BY TREVOR LAINGCHILD, RDT, AAACD.....36

CREATING NATURAL ESTHETIC VENEERS UTILIZING A NEXT GENERATION COMPOSITE MATERIAL ♦ BY FRANK J. MILNAR, DDS, AAACD.....40

TEACHING DENTAL ASSISTANTS TO SPEAK YOUR LANGUAGE ♦ BY SHANNON PACE BRINKER, CDA, CDD.....52

SPEAKING SKILLS FOR AACD PRESENTERS ♦ BY SANDRA R. ROTH.....58

AACD ACCREDITATION TRACK CASE TYPE II: ONE OR TWO INDIRECT RESTORATIONS ♦ BY MARTY ZASE, DMD, FAACD.....62

---

ELEARNING.....67

ELEARNING PROGRAM REVIEW: THREE-PART VIDEO SERIES—ACCREDITATION CASE TYPE I:  
SIX OR MORE INDIRECT RESTORATIONS ♦ BY JOHN F. WESTON, DDS, FAACD.....68

---

GIVE BACK A SMILE™.....78

A GLIMPSE INTO DOMESTIC VIOLENCE.....80

CAUSE AND EFFECTS OF DOMESTIC VIOLENCE.....83

A NEW SMILE, A NEW OPPORTUNITY ♦ BY IRA M. LANGSTEIN, DDS.....87



AACD MISSION STATEMENT

The American Academy of Cosmetic Dentistry is dedicated to advancing excellence in the Art and Science of Cosmetic Dentistry and encouraging the highest standards of ethical conduct and responsible patient care.

ACCREDITATION ESSENTIALS.....	92
INTRODUCTION TO ACCREDITATION ESSENTIALS ❖ BY JAMES H. HASTINGS, DDS, AAACD.....	93
ACCREDITATION CLINICAL CASE REPORTS—ACCREDITATION CASE TYPES IV & III: ANTERIOR DIRECT RESIN ❖ BY JEFFRY S. KERBS, DDS.....	94
ORIGINS OF ACCREDITATION: INTERVIEW WITH DR. JEFF MORLEY ❖ BY JAMES H. HASTINGS, DDS, AAACD.....	104
<hr/>	
CLINICAL SCIENCE .....	110
CLINICAL COVER STORY ❖ BY ROBERT G. RITTER, DMD & NELSON A. REGO, CDT, AAACD .....	111
ESTHETIC REPAIR OF THE DENTAL CONSEQUENCES OF CELIAC DISEASE: A CASE REPORT ❖ BY JAMES F. FONDRIEST, DDS & MATTHEW R. ROBERTS, CDT, AAACD.....	118
CORRECTING SOFT TISSUE DEFICIENCIES PRIOR TO ESTHETIC DENTAL PROCEDURES ❖ BY PAUL S. PETRUNGARO, DDS, MS .....	129
<hr/>	
ADVERTISING INDEX .....	142

2009 Statement of Ownership, Management and Circulation

Statement of Ownership, Management and Circulation, required by Title 39, United States Code 3685. Title of publication: *Journal of Cosmetic Dentistry*. Date of filing: October 1, 2009. Publication number: 1532-8910, USPS# 10452. Frequency of issue: quarterly. Annual subscription price: members, included in the membership dues; non-members/subscribers, \$135.00 (US and Canada), \$160.00 (all other countries) by the American Academy of Cosmetic Dentistry®, 5401 World Dairy Drive, Madison, WI 53718. 800.543.9220 OR 608.222.8583. Periodicals postage paid in Madison, WI and additional offices.

Mailing address of publisher: American Academy of Cosmetic Dentistry, 5401 World Dairy Dr., Madison, WI 53718. County: Dane. Name and address of the Editor: Mike Koczarski, DDS, 5401 World Dairy Dr., Madison, WI 53718. Name and address of the Director of Publications: Tracy Skenandore, 5401 World Dairy Dr., Madison, WI 53718. Average number of copies each issue during preceding 12 months: Total number of copies (net press run): 7,691; mailed outside-county paid subscriptions stated on PS Form 3541: 6,352; paid distribution by other classes of mail through the USPS: 1,147; Total paid distribution: 7,499. Free or nominal rate copies mailed at other classes through the USPS: 74; Free or nominal rate distribution: 38; Total free or nominal rate distribution: 112; Total distribution: 7,611; copies not distributed: 80; Percent paid: 99%. Number of copies of single issue published nearest to filing date: Total number of copies (net press run): 7,583; mailed outside-county paid subscriptions stated on PS Form 3541: 6,133; paid distribution by other classes of mail through the USPS: 1146 ; Total paid distribution: 7,279. Free or nominal rate copies mailed at other classes through the USPS: 58; Free or nominal rate distribution outside the mail: 0; Total free or nominal rate distribution: 58; Total distribution: 7,337; copies not distributed: 246; Percent paid: 99%. I certify that all information furnished is correct and complete. Signed Tracy Skenandore, Director of Publications.

POSTMASTER: send address changes to:  
Journal of Cosmetic Dentistry  
American Academy of Cosmetic Dentistry®  
5401 World Dairy Drive  
Madison, WI 53718

Peer-reviewed articles are denoted with the following symbol ❖

Statements of fact and opinion are the responsibility of the authors alone and do not imply an opinion on the part of the officers of the AACD. Materials may not be reproduced without written permission. Contents© 2009 American Academy of Cosmetic Dentistry®

The *Journal of Cosmetic Dentistry* is produced using sound publishing practices. Our text stock contains a minimum of 10 percent post-consumer waste and is certified by the Forest Stewardship Council, a nonprofit organization dedicated to ensuring that the world's forests are managed in a sustainable way. Our cover stock contains a minimum of 50 percent post-consumer waste.



## ONE-STOP SHOPPING

Why do we commit ourselves to pursuing continuing education (CE)? Why do we continually need to learn something new? Well, as the old saying goes, either you're growing or you're dying; there's no in-between. It seems like dental technology is growing and changing faster each day, and we need to continually

keep up to provide our patients with the very latest and best care possible. With that said, our horizons in knowledge are not only growing broader, but they are growing laterally as well. What do I mean by "laterally"? I used to help my older brother work on his cars...simple V8 engines, with carburetors and cables. Today's cars, however, have computers with fuel injectors, turbos, and so little room around the engine that I can't even change the oil anymore. Today's auto mechanics are no longer the "mom and pop" gas station around the corner; they're a team of specialized technicians, each with a specialized knowledge bank. Dentistry has expanded as well. No longer can one clinician provide all the services that our patients require. We need to find our niche, find our passion, and "specialize," if you will, to focus our learning so that we can assemble a team to provide our patients with the best care today's technology has to offer.

My niche is cosmetic dentistry. Why? As I explored our profession, this area seemed to come into focus time and time again. Take our varied organizations, consider all other disciplines such as implants, endodontics, orthodontics, and periodontics; think of our annual scientific session, the speakers and subjects considered and discussed. Each is critical to our patients' care, and I believe that one organization—the AACD—is integral to each of the other disciplines. We are where science meets beauty, where natural esthetics and function converge. In addition, our Accreditation program and its five case types enable all disciplines to come into play.

When considering CE, it's about gaining new knowledge, as well as refocusing our attention on what we already know. Our annual scientific session, the *Journal of Cosmetic Dentistry (JCD)*, and other journals and meetings are about re-energizing our minds with knowledge and camaraderie. Within the *JCD*, we carefully choose our topics to explore our Accreditation cases, as well as cutting-edge technology, protocols, and preparation that lead us continually down a path of excellent dentistry with conservation and beauty in mind. Take for example the once "tried and true" full-mouth rehabilitation utilizing porcelain-fused-to-metal (PFM) and gold crowns on second molars. Yes, this has stood the test

of time, but does it really meet all the criteria and demands of today's patients and our own expectations? I think not. We can do better; with newer materials and constantly improving techniques, the marriage of technology and beauty merge together as we strive to match long-lasting functionality and conservative dentistry with natural-looking and undetectable esthetics.

We can learn a great deal by reading, watching, and doing. All three methods are the best way to ingrain new skills and implement them into our daily routines. As important as it is to attend valuable meetings, however, most of us cannot travel the world chasing down every lead or new idea. But we *can* read journals in the comfort of our own home or office; and with the ever-growing media realms available to us, we can go online and educate ourselves about new techniques, procedures, and topics via eLearning. Take implants, for example. Once an exotic procedure, focusing mainly upon tooth replacement with metal collars and PFMs, it has now progressed to the point where our expectations demand a functional restoration that blends with natural dentition to the point of being undetectable. As I mentioned earlier, the only way this can happen is when we incorporate many disciplines of dentistry with every progressive technological improvement available to us today. The AACD, the *JCD* and eLearning enable us to not only stay abreast of the latest technology, but to also watch procedures, bringing us a step closer to the ultimate goal: Implementation within our practices. In this issue of the *JCD*, we are pleased to launch the new eLearning section with Dr. John Weston's article on page 68 (to see more details about this case, readers are directed online to [www.aacd.com](http://www.aacd.com) to take the course).

Also, you will find that this issue of the *JCD* has been wrapped with a paper band advising readers to go online to access a free AACD eLearning course. You will access this free course using the special code: *eGift*.

We hope you enjoy and learn from this special issue of the *JCD*, which offers various highlights of the educational content presented at the 25th Anniversary AACD Scientific Session in Hawaii this past Spring. This special issue will also have an expanded circulation, being mailed to attendees of the 6th World Congress of the International Federation of Esthetic Dentistry and other potential AACD members.

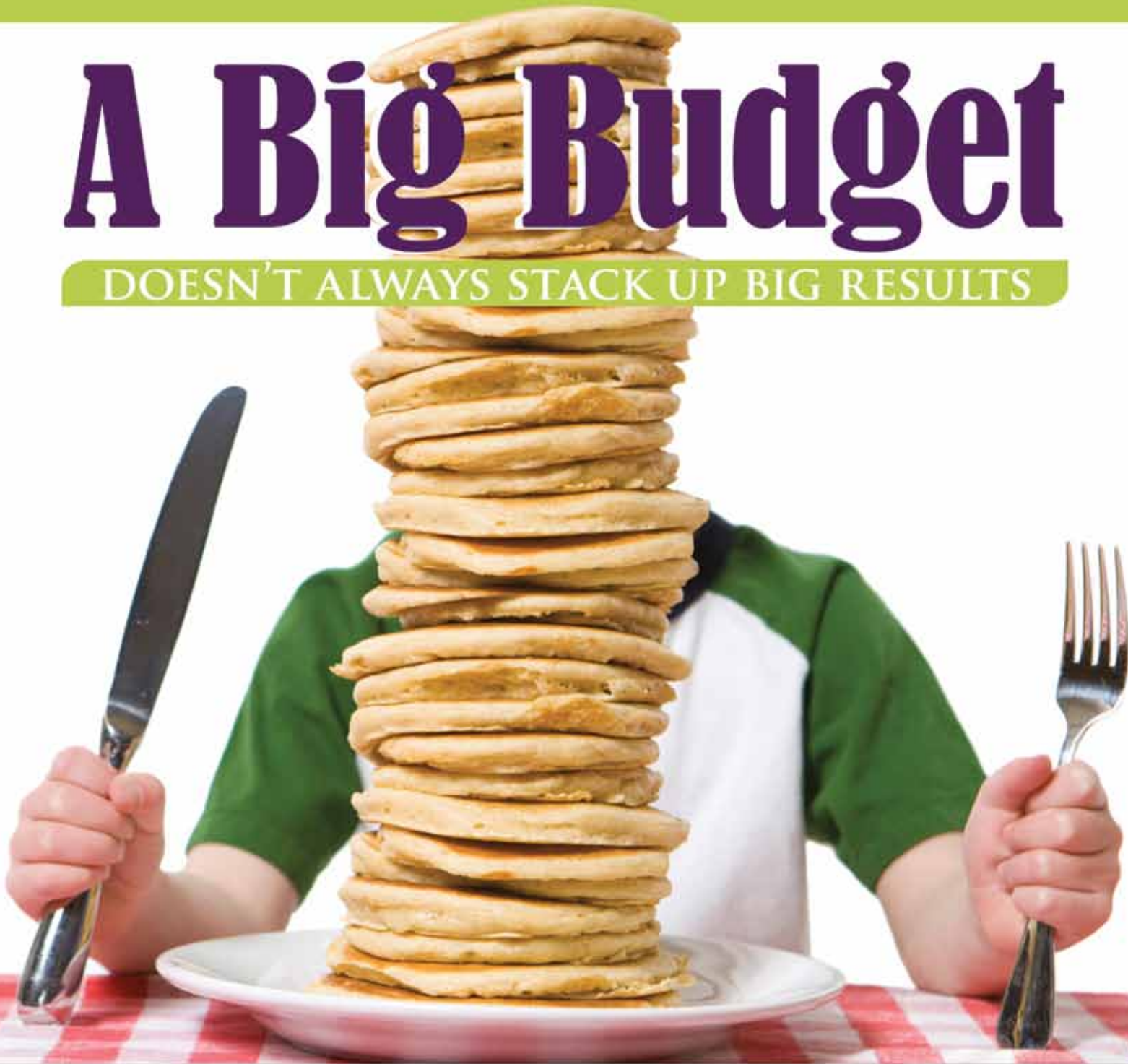In all things, may your expectations forever be exceeded. Go big or go home!

A handwritten signature in black ink that reads "Michael". The signature is fluid and cursive, with a large initial 'M'.

Michael J. Koczarski, DDS, Editor

# A Big Budget

DOESN'T ALWAYS STACK UP BIG RESULTS



What does? A hearty mix of market research, demographic studies, strategic plans, targeted media and creative campaigns . . . all served up from an experienced firm.

*At Golden Proportions Marketing, we don't believe in stacking the budget with strategies we "hope" will work. We develop comprehensive, long-term plans and carefully measure the success of your marketing initiatives. We track campaigns, measure ROI and guide you with informed advice.*

And we do it all with the most creative and talented people in the industry for marketing that'll make you flip.

**GPM** GOLDEN PROPORTIONS MARKETING

1.866.590.4476

Still think bigger is better?

Visit [www.goldenproportions.com/bigger](http://www.goldenproportions.com/bigger).

We just may change your mind *and* your practice.

VISIT [WWW.GOLDENPROPORTIONS.COM/BIGGER](http://WWW.GOLDENPROPORTIONS.COM/BIGGER)

# PRESIDENT'S MESSAGE



## ADVOCACY IS A RIGHTEOUS ACTION

Although I grew up in a metropolitan area, my family's vocation was "truck gardening." Tucked into an older part of the city by the Missouri River, our backyard consisted of 100 acres where we raised vegetables—not only to put food on the table, but also

to put clothes on our backs.

By virtue of our four-season climate, most of the work that provided our economic survival occurred during the summer months. We sold wholesale at a local fruit and vegetable commerce district, as well as to local grocery stores. However, most of our financial success came from our own retail vegetable stand next to our acreage.

A vast majority of our land was rented from the Union Pacific Railroad (UP), which commanded the respect and power granted to national economic giants of that era. A major rail line also ran by our house and carried all the coal necessary to power Omaha and parts of eastern Nebraska. Just as with our business, the summer was important to the UP, for during this time they built new lines of track, re-routed old lines, and repaired deteriorating ones.

During one summer in the early 1960s, UP decided it was the perfect time to replace the railway line by our house. Unfortunately for my family, this meant UP intended to shut down the road to our vegetable market for most of that summer. Without traffic, our business would be ruined and our income for the year would be severely endangered. Although my father lodged early protests in a politically correct manner, those requests fell on deaf ears. The well-being of a lower socioeconomic family scratching out a living in the dirt was far less important than the needs and desires of a major U.S. economic power focused on satisfying its shareholders. We were duly informed: The road was going to be closed, and that was that. Until...

...One day, when my Dad, perched high on the seat, started up the biggest of our five tractors, drove it over to the rail line, parked it square on the tracks, put the keys in his pocket, and refused to move. First, the local newspaper reporters appeared. Then a locomotive, pulling three-quarters of a mile of coal cars, came to a stop just short of my Dad's tractor. Shortly after the police were called, the radio reporters and television camera crews arrived.

Before long the entire story was laid out for all to see, and an objective examination of the issues took place.

It wasn't long before the UP work resumed—and it wasn't long before the vegetable stand in our backyard was humming with activity. How could these seemingly incompatible events occur at the same time? When confronted with the reality of what was right, UP decided it was justifiable to build a temporary road to our family's vegetable stand *before* starting the work on their new access line.

It was an easy feat for UP to accomplish and took only a couple of days, as their work crews and equipment were already on site. Why did my Dad have to park the tractor over the tracks and literally stop locomotives before UP would consider a more reasonable alternative? I believe it is because when big business charges forward with a project, they fail to understand—or, in some cases, don't even care about—the implications for those impacted by their actions.

I have thought many times about my Dad's resolve during that chapter of my life. Where did he find the strength to stand up for his best interests and for what he believed was right, especially when we leased our land from the very entity he confronted? When I asked him about it, he simply replied, "*You always have to stand up for a cause when you feel you are right.*"

Lately his words come to mind when I see our Academy fight for member rights, especially the right to inform the public and our patients of the expertise, training, and experience gained through our membership in the AACD.

One can certainly understand why the American Dental Association (ADA), in representing all dentists, has taken a position that all dentists have the right to call themselves "cosmetic dentists" regardless of any special training or unique skills. The fallout from the general population of dentists would be enormous were the ADA to adopt a different stance.

In a similar line of thinking, the AACD, in representing all our members, has taken a position that Academy members, who have pursued additional training and demonstrated skills and expertise over and above the basics, should be allowed to promote that training and accomplishment in their communities. Shouldn't the value of an objective examination process with positive results trump self-proclaimed marketing hype?

*continued on page 12*




# Want More New Patients?

**Then generate more new patients**

**with Patient News Publishing – the marketing partner that many of your AACD colleagues have chosen!**

- Target & attract high-quality patients
- Increase new patients
- Include female head-of-household name throughout (see “Cheryl”)
- No-interest payment plans available
- Free demographic analysis & mail list included – refreshed every time!



**Dr. James Reid Roberts and Dr. Beverly Roberts**


Produced for Cheryl Bishop Fall 2009

**Cheryl, Don't Wait...**  
Let us help you to lighten up that spotted smile!

It was a great photo. You were caught in the middle of a “full-on” laugh. Then you noticed the old, silver, amalgam fillings and realized that your entire dental history is on display! No need to be self-conscious any longer. There is a simple and attractive solution to the problem.

According to research, the demand for natural-looking white composite resin fillings has surpassed silver amalgam by a ratio of more than 3:1! These fillings are more natural looking than amalgam, and have the added advantage of never discoloring surrounding or neighboring teeth as older amalgam fillings have been known to do. Modern materials and processes ensure that they are also durable, reliable, and predictable.

Because of these advantages and high consumer demand, we have recently restocked one of the finest composites available. This material can be so



precisely color-matched to your teeth that it will be invisible to the casual observer.

Let's talk about concealing, once and for all, your “dental history” with composite fillings. It can usually be done in only one visit or two, and because your silver fillings could be upwards of 15 years old, your insurer may cover replacement costs.

Call us about this impressive improvement. Be laugh-out-loud confident... whether you're in front of, or behind, the camera!

**Whiten Your Smile for Fall!**

Special Price NOW! **\$300**

Call us today September 30th - 10th

**Brilliant Smiles Dental**  
Dr. James Reid Roberts  
Dr. Beverly Roberts  
2787 West Highway 54  
Peachtree City, GA 30269-1063

**Office Hours**  
Mon-Thu 8:00 am – 5:00 pm  
Friday 8:00 am – 2:00 pm  
Saturday 8:00 am – 12:00 pm\*  
\*one Saturday per month

[www.brilliantsmilesdental.net](http://www.brilliantsmilesdental.net)


**Our Services Include:**

- Family & cosmetic dentistry
- Teeth whitening
- Cosmetic veneers
- Invisalign® orthodontic treatment
- Relaxing & friendly environment
- Modern, state-of-the-art facility
- Nitrous oxide sedation
- TV, videos, and music in treatment rooms
- 0% financing available
- Visa, MasterCard, Discover Network, CareCredit and checks welcome

**WE WELCOME NEW SMILES!**

*If you presently have a dentist you are happy with, please consider this information helpful. If you are looking for a dentist, please think of*

**Call Today!**  
**(770) 486-8516**



*Cheryl... Did you know 87% of people feel they always remember an attractive smile!*

“ Working with Carrie & Patti Lou has been such a pleasant experience. We are starting to get so many calls on the newsletter/postcard combination mailing & the people coming in have been great. We made the right choice the day we called you guys for help. Thanks so much.

– Brilliant Smiles Dental



# ABOUT THE COVER

---



by

Robert G. Ritter, DMD and Nelson A. Rego, CDT, AAACD

Moriah was never very happy with her small teeth and spaces, which made her self-conscious. The patient presented with small teeth and an excessive amount of gingival display. A complete examination, periodontal examination, full-mouth x-rays, and Panorex were completed. She wanted longer teeth, not too much whiter but with better proportions. We discussed with the patient the need for her to see our periodontist and have an examination to determine if osseous recontouring could and should be performed.

After exploring all the options, Moriah agreed to the crown/osseous treatment plan. Teeth #6-12 had osseous, gingival recontouring surgery. Typical healing times range from a minimum of three to four months. However, we allowed her six months to heal to ensure that her gingival tissue health was optimal. It was now time to proceed with our restorative treatment plan.

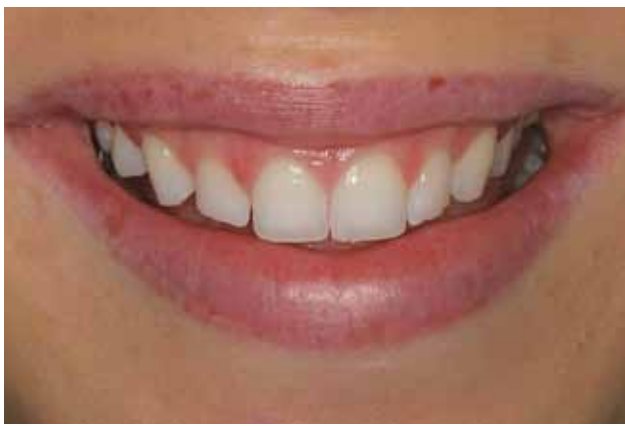One of the treatment objectives was to be as noninvasive as possible with restorations that had 100% enamel retention. Because her teeth were in the proper alignment with healthy gingival tissues that were at the correct gingival heights and zeniths, it was determined that we could do minimal-preparation restorations. The records were gathered and sent to the laboratory for an ideal wax-up. The patient began to whiten her teeth in the interim.

The patient's teeth were prepared for IPS e.max thin veneers, #4-13 (Ivoclar Vivadent; Amherst, NY). The preparations were completed; the provisionals were fabricated from the ideal wax-up out of Luxatemp shade B1 (Zenith/DMG; Englewood, NJ). The veneers were fabricated out of MO-O ingots, cut back and layered. The patient wore the temporaries for a week, an impression was taken of the approved provisionals, and sent to the laboratory to replicate the form and function. The final veneers were seated with Variolink veneer shade 0 (Ivoclar Vivadent).

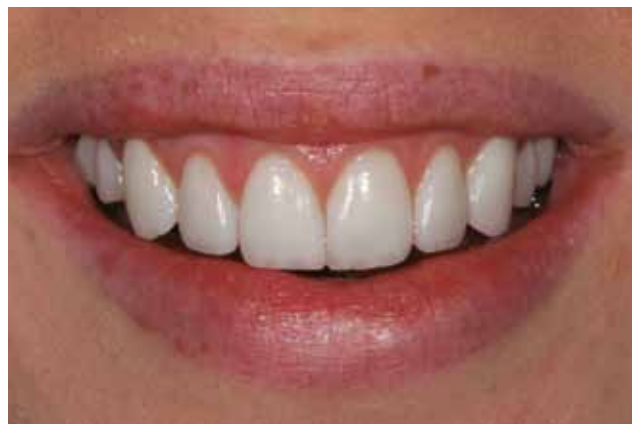Moriah was extremely happy with the final results, which gave her the dazzling smile she always wanted.

For more on this patient's story, please turn to page 111.

Dentistry and clinical photography by Robert G. Ritter, DMD (Jupiter, FL). Periodontal osseous/gingival recontouring by Karina Leal, DMD (West Palm Beach, FL). Ceramic artistry by Nelson A. Rego, CDT, AAACD (Santa Fe Springs, CA). Cover photography by Sara Kauss, Sara Kauss Photography (Tequesta, FL).



*Preoperative.*



*Postoperative.*



*Moriah was extremely happy with the final results, which gave her the dazzling smile she always wanted.*



## PRESIDENT'S MESSAGE CONTINUED

---

Here's a common scenario: A new patient comes to the practice complaining that a previous dentist's work did not meet his or her esthetic expectations. The patient reports having chosen the previous "cosmetic dentist" (or one whose advertising suggested some special expertise or skill in cosmetic dentistry), but maintains the dentist didn't appear to know how to achieve the desired results. The patient is confused, aggravated, and beginning to distrust dentistry in general.

Many State Boards have created barriers to marketing and advertising, which, by following ADA mandates and recommendations, make it difficult for patients to find a dentist with specific training and expertise in esthetics. These boards support laws and write regulations that specifically prohibit informing the public about any credentials related to specialized achievement outside the specialty areas the ADA previously identified. Therefore, a patient can readily find an orthodontist or a pediatric dentist, but has trouble sifting through those best qualified to provide sophisticated cosmetic dental procedures.

Last year, the AACD joined with the Academy of General Dentistry (AGD) and the American Board of Implantology (ABOI) in support of the American Academy of Implant Dentistry (AAID) lawsuits in Colorado, California, and Florida supporting our collective contention that the public has the right to know about legitimate credentials in dentistry that fall outside the original ADA dental specialties.

I am happy to report that those cases were settled in a manner that allows our members to publicly exhibit their AACD membership level. I am also proud to report that our board of directors has endorsed continuing these advocacy efforts. Patients deserve the right to examine and understand the difference between objective examination results and self-proclaimed expertise. A patient's right to know will ultimately decide this issue.

The AACD leadership pledges to *all* our members that we will continue to fight for the right to inform your community of your efforts to excel in the field of cosmetic dentistry. It is simply the right thing to do. We will do this through advocacy, education, and legal means, when necessary. For now, we'll "leave the tractor in the barn."

My best wishes to you and yours,



Michael R. Sesemann, DDS  
President, AACD Accredited Fellow Member (FAACD)  
GBAS Volunteer



# BE MORE.

# DO MORE.

We are energized about our profession. We strive to differentiate ourselves. We continually expand our skill sets. We give back to those less fortunate. We are connected. We are the American Academy of Cosmetic Dentistry.

[www.aacd.com](http://www.aacd.com) • 800.543.9220 • 608.222.8583

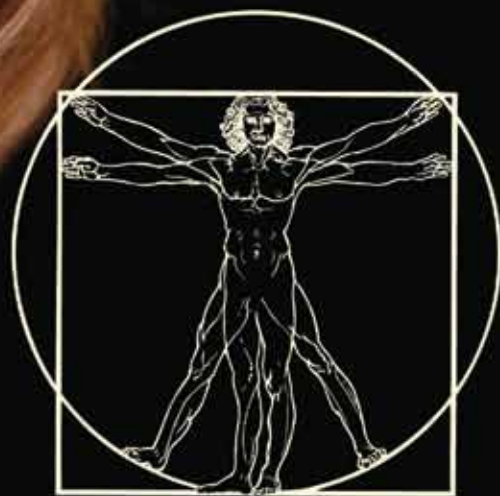


# Simply Elegant

Or, put simply:  
*glamorous, life-revolutionizing smiles.*

Put even more simply:  
*da Vinci veneers.*

da Vinci will be proud to introduce to  
you your own personal ceramist!



**da Vinci Studios®**

**Veneers by da Vinci**

Patient: Donna

Doctor: Dr. Everett E. Heringer, DDS

For more information, please call da Vinci Studios at

**800.874.7239**

or visit us on the web at [davincilab.com](http://davincilab.com)

Outstanding marginal integrity.  
Enhanced, long-lasting durability.  
Precise control of optical properties.  
Exceptional tissue biocompatibility.  
Metal-free, highly-esthetic porcelain.

# 26TH Annual AACD Scientific Session

What's the 



2010

AMERICAN ACADEMY OF COSMETIC DENTISTRY®  
TUESDAY, APRIL 27 THRU SATURDAY, MAY 1, 2010  
 GRAPEVINE, TEXAS  WWW.AACD.COM

## 26TH ANNUAL AACD SCIENTIFIC SESSION IN GRAPEVINE, TEXAS TUESDAY, APRIL 27 - SATURDAY, MAY 1

### IN THIS SECTION:

---

THE LEARNING REVOLUTION AND THE DENTAL LABORATORY PROGRAM FOR 2010 ♦ BY GILBERT YOUNG, CDT, AAACD.....	15
<hr/>	
<b>25TH ANNIVERSARY AACD SCIENTIFIC SESSION RECAP</b>	
MAXIMIZING ESTHETIC RESULTS WITH THE USE OF PREPARATION MATRICES ♦ BY JOYCE L. BASSETT, DDS, FAGD, AAACD.....	18
IN-OFFICE MODEL PREPARATION FOR COSMETIC SMILE DESIGN AND VIRTUAL TRY-INS ♦ BY MITCH A. CONDITT, DDS & MICHAEL L. MILNE, CDT .....	24
ON TARGET: PART 1—CREATING SYSTEMS FOR SUCCESS IN A CHANGING WORK ENVIRONMENT ♦ BY CATHY JAMESON.....	32
LABORATORY TECHNICIAN ACCREDITATION WORKSHOP ♦ BY TREVOR LAINGCHILD, RDT, AAACD.....	36
CREATING NATURAL ESTHETIC VENEERS UTILIZING A NEXT GENERATION COMPOSITE MATERIAL ♦ BY FRANK J. MILNAR, DDS, AAACD.....	40
TEACHING DENTAL ASSISTANTS TO SPEAK YOUR LANGUAGE ♦ BY SHANNON PACE BRINKER, CDA, CDD .....	52
SPEAKING SKILLS FOR AACD PRESENTERS ♦ BY SANDRA R. ROTH .....	58
AACD ACCREDITATION TRACK CASE TYPE II: ONE OR TWO INDIRECT RESTORATIONS ♦ BY MARTY ZASE, DMD, AAACD .....	62

## THE LEARNING REVOLUTION AND THE DENTAL LABORATORY PROGRAM FOR 2010



by Gilbert Young, CDT  
AACD Accredited Member  
(AAACD)  
Plano, TX  
[www.gnsdentalstudioonline.com](http://www.gnsdentalstudioonline.com)

### INTRODUCTION

The "Learning Revolution" will certainly echo in the American Academy of Cosmetic Dentistry's (AACD) Dental Laboratory Program for 2010.

This unique dental laboratory program will be showcased in the *26th Annual AACD Scientific Session Preliminary Guide*. The program objective is for all attendees to be able to quickly and concisely identify the laboratory technology program content. In previous preliminary guides, program content was difficult to identify. The AACD will feature at least one dental laboratory presenter every day throughout the annual meeting. Participants will further benefit from attending programs presented by dentist/clinician counterparts; for instance, Drs. John Kois, Robert Winter, Lorenzo Vanini, Newton Fahl, and Jimmy Eubank, who will focus on the restorative portion. Such a strong program would be difficult to find elsewhere. The AACD dental laboratory program promises to deliver any stand-alone dental laboratory the highest-caliber program offered anywhere in the world.

### SO WHAT IS NEW FOR 2010?

As the Professional Education Committee (PEC) member in charge of the dental laboratory program, I have given much thought to what the attendees need in terms of dental technology and the importance of improving the partnership between dentist and dental technician for achieving patient goals. This effort has led the PEC to assemble an international dental laboratory speaker roster composed of highly skilled educators and masters representing Europe, Japan, and the U.S.

We have tried to achieve a balance between teaching new technology and the fundamentals of dental technology. We believe that most dental technology deficiencies are due to the dental technician's lack of fundamental knowledge and principles, and not due to the lack of technology. The AACD leader-

YOUNG

ship has embraced dental technician needs like no other organization and provides ideal venues for learning at the annual AACD scientific sessions. Technology and materials are only as good as those who present them, and knowledge provides that driving force. We have exemplified this statement with our quality 2010 dental laboratory speaker roster and the variety of subjects offered.

I encourage our dental counterparts to attend as many dental laboratory lectures as possible. In order to provide outstanding patient restorations, it is important to gain a clear perspective and a better understanding of what dental technicians need and what they should know from the dental practitioner.

## ABOUT SOME OF OUR KEY SPEAKERS

### FROM EUROPE

One of the most interesting subjects in dental technology today is how to achieve total esthetic harmony between restorations and soft tissues. With the variety of techniques available, a multidisciplinary approach can be used. We are delighted to feature master dental ceramist, author, and teacher Patrick Rutten, MDT, from Belgium, who will demonstrate his expertise in achieving total harmony between the soft tissue and ceramic restorations, utilizing CAD-CAM technology and zirconium-reinforced restorations. Mr. Rutten and his brother, Luc, have co-authored two beautiful books on implant-esthetic dentistry, published by Quintessence. I am honored that Mr. Rutten will participate in this stellar event and thoroughly expect his teaching to inspire a great number of attendees.



*Patrick Rutten, MDT, along with his brother, Luc Rutten, MDT, maintain their own dental laboratory, the Dental Labo Rutten, in Tessenderlo, Belgium. Their lab specializes in esthetics and function on ceramic restorations and implantology. Mr. Rutten is a popular international speaker. In 1991, the Rutten brothers published their first article in Das Dental Labor; it was translated into three languages. They have also written two books, Implant Aesthetics and Crown & Bridge and Implants: The Art of Harmony (Teamwork Media Verlage GmbH/Fuchstal/German). Patrick Rutten has given lectures, table clinics, and courses on ceramic restorations, esthetics, and implantology throughout the world.*

### FROM JAPAN

We will focus on one of the most fundamental aspects of the fabrication of a dental restoration: Proper tooth form and how to achieve it. Contrary to what the bleach shade syndrome has created in dentistry, without proper form and function, a restoration is not all it should be. A higher dental ceramist skill level cannot be achieved without constant pursuit of the mastery of dental form and the ability to adapt it to today's patients' demands. From Japan, we are featuring a true master of dental anatomy—researcher, author, and teacher Shigeo Kataoka, RDT. He will share how dental form in Japan is taught and applied at the mastership level, and how to

incorporate the principles of correct dental anatomy to a variety of dental restorations available today. Mr. Kataoka has devoted his entire career to natural dental form study and observation as a requirement for excellence in dental ceramic restorations. We hope our laboratory technicians and dentists will not only learn, but will also be inspired by his passion.



*Shigeo Kataoka, RDT, is an internationally acclaimed ceramic specialist, teacher, and lecturer. He entered Osaka Dental Studio Co. Ltd. in 1969 and graduated from Yukioka Medical Technical College in 1972. He taught at the Apex Company from 1980 to 1983. In 1984, he established the Osaka Ceramic Training Centre. Then, in 1989, he founded the private laboratory Kataoka Ceramic Ltd. and in 1993 the Osseo Integration Implant Laboratory, both in Osaka. In addition, Mr. Kataoka has written various technical articles on dental ceramics and implants. His first technical book, Nature's Morphology, was published in 1993. The Japanese language edition of his second book, Harmony, was published in 2006.*

### FROM THE U.S./JAPAN

Back by popular demand, master dental ceramist and photographer Naoki Aiba, CDT, will demonstrate his A to Z approach to precise and beautiful dental ceramic reconstruction and photography. A purist in his approach, and an everyday reminder that skills are more impor-



tant than the latest material, he often utilizes conventional materials to fabricate restorations that only nature could rival. As a professional photographer, he also teaches one of the best systems of communicating with dental photography.



*Naoki Aiba, CDT, is a ceramist and professional photographer. A 1982 graduate of the Dental Technology Program at the Dental School of Aichi Gakuin University in Nagoya, Japan, he completed the post-graduate ceramics course at the Tokai Dental Technicians School in 1986. In 1992, Mr. Willi Geller selected Mr. Aiba to be a member of Oral Design. He has been*

*published in more than 30 countries on ceramics, dental photography, and dentist-laboratory communications, and has exhibited his photographs around the world. A member of the Editorial Board for QDT, he maintains his laboratory, Science Art, Inc. in Monterey, California; and offers hands-on seminars at his teaching facility, Oral Design Monterey.*

### SYNERGY SUMMIT 2010

The AACD recognizes the importance of true collaboration between dentist and dental technologist for delivering excellent restorative work. Often dentists and dental technicians lack an understanding of what the other needs.

After two consecutive years, excellence in teamwork will be showcased again at the 2010 Annual Scientific Session Synergy Summit. Pinhas Adar, MDT, Tal Morr, DDS, Matt Roberts, CDT, and John Roberts, DDS, will be featured demonstrating their innovative implant

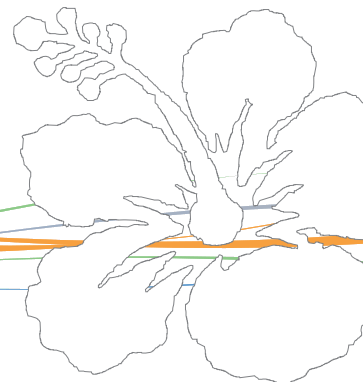
restorative techniques. This lecture will provide a unique opportunity to see firsthand how success is achieved through interacting and winning teams.

The dental laboratory speakers mentioned here are only a few of those featured at the annual AACD scientific session for 2010. We believe this combination of dental speakers and the vast array of technological offers, such as "AACD Digital World," will provide a first-class educational experience.

On behalf of the PEC, I encourage you to be part of the "Learning Revolution" and experience all aspects of this outstanding program.



THE ARTICLES THAT FOLLOW IN THIS SECTION REPRESENT SOME HIGHLIGHTS FROM THE 25TH ANNIVERSARY AACD SCIENTIFIC SESSION IN HAWAII. WE HOPE READERS FIND THEM INSTRUCTIVE AND ENJOYABLE, AND WE ENCOURAGE YOU TO TAKE ADVANTAGE OF THE NUMEROUS VALUABLE EDUCATIONAL PROGRAMS OFFERED BY THE AACD.



## MAXIMIZING ESTHETIC RESULTS WITH THE USE OF PREPARATION MATRICES



by  
 Joyce L. Bassett, DDS  
 FAGD, AACD Accredited Member  
 (AAACD)  
 Scottsdale, AZ  
[www.drbbassett.com](http://www.drbbassett.com)

*Editor's note: This article is based on a Heraeus-sponsored hands-on workshop at the 25th Anniversary AACD Scientific Session in Honolulu, Hawaii.*

### ABSTRACT

This article presents a clinical case that was prepared by combining the traditional, simplified depth cutter approach with recontouring and preparation design principles that were determined clinically by the dentist. Plastic preoperative models of this case—along with labial and incisal reduction preparation guides fabricated from the diagnostic wax-up—were used for demonstration purposes during an Annual AACD Scientific Session hands-on course. This course addressed current approaches to tooth preparation that would simplify the preparation design process for difficult space management cases and facilitate predictable and repeatable results.

---

*Although minimal preparations are ideal, laboratory ceramists can become frustrated at the prospect of trying to create restorations with the desired esthetics if an improper preparation design has been created.*

---

### INTRODUCTION

When faced with a case involving complex space management issues, it is not uncommon for clinicians to be uncertain about where tooth structure should be removed, as well as how much tooth preparation is sufficient or too aggressive. Although minimal preparations are ideal, laboratory ceramists can become frustrated at the prospect of trying to create restorations with the desired esthetics if an improper preparation design has been created.

Preparation of tooth structure requires planning and attention to detail. Traditionally, however, dentists have relied upon visualization of the anticipated outcome and prepared the teeth to those expectations, inadvertently leaving great room for error.

# DiaDent®

www.diadent.com  
1.877.342.3368

**ADVANCED TECHNOLOGY**  
Genuine Photochemical Bleaching Material

**REVAMP YOUR THINKING!**  
Teeth Whitening ≠ Sensitive Teeth

Presenting the **FUTURE** of teeth whitening technology...

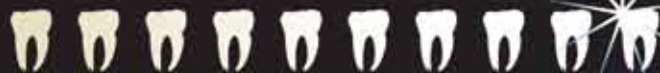# dazzle™

**NEW Advanced Teeth Whitening System**

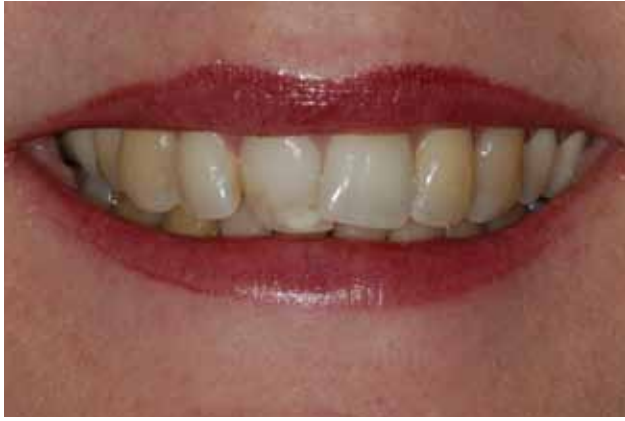

## BENEFITS:

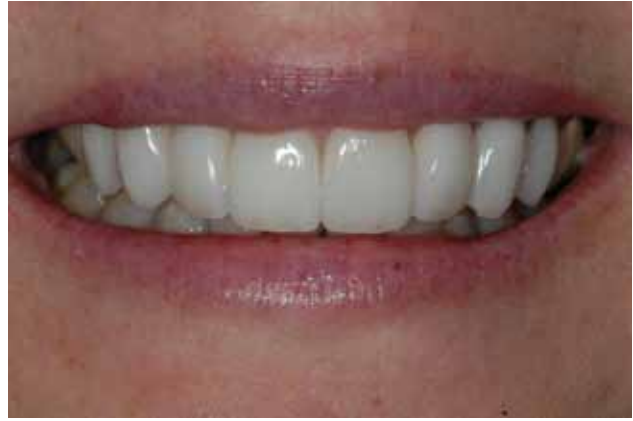- Advanced patented photochemical mediators
- No sensitivity, no pain, and no discomfort
- Superb color lightening (5-8 shades)
- Repeatable, after 6 months
- Fast and visible activation: Saves time for dentists and patients  
(30 minutes for the whole procedure)
- No need to purchase specialized lamp equipment
- Teeth stay hydrated - no rebound effect



From dullness to dazzling brilliance...



*Figure 1: Preoperative smile, showing discolored, rotated, and poorly positioned teeth.*



*Figure 2: Postoperative smile, displaying harmony and balance.*

In the evolution of preparation techniques, depth guides have historically been used to ensure proper facial reduction. However, when this technique is used, it is necessary that the teeth be in the proper arch form (i.e., not deficient facially) in order for the depth cutters to produce accurate results.

Today, conservative dentistry begins with an analysis of an accurate diagnostic wax-up developed with consideration of smile design principles (e.g., midline, canting, arch form, and buccal corridor expansion). These principles lay the foundation for visualizing the final esthetic restorative outcome and determining preparation parameters. Indices can be made based upon the diagnostic wax-up and placed to guide the dentist during tooth preparation.

Another preparation technique stemming from the creation of the diagnostic wax-up is the bonding of provisionals prefabricated from the diagnostic wax-up onto the unprepared teeth, after which depth guides are used on the facials of the provisionals to facilitate routine veneer preparation.<sup>1</sup>

Tooth preparation techniques that combine the use of reduction guides with smile design principles can help dentists to ensure predictable and repeatable results in the pursuit of conservative tooth preparations, while still satisfying today's standards for esthetic outcomes. These techniques help to simplify difficult space management cases by incorporating a systematic routine for the preparation procedure.<sup>2</sup>

### CASE PRESENTATION

The patient presented with rotated and poorly positioned maxillary teeth (Fig 1). Her chief complaint related to the esthetics of her smile; she identified color and crowding as her primary concerns. This case would best be treated with a combination of orthodontics and minimal tooth reduction restorations. However, when the patient was sent for an orthodontic evaluation, she refused the primary clinical recommendations of orthodontics and bleaching.

### RECORDS AND EVALUATION

Full records were obtained, including models, facebow, photographs, and bite registration mounted on a semi-adjustable articulator. A comprehensive history, physical examination, and occlusal analysis were performed. Temporomandibular joint and periodontal pathologies were not present, and the patient demonstrated acceptable occlusal function.

Cosmetic analysis revealed a medium to low smile line, with the papillae showing. The uneven gingival levels were concealed by her lip line. The patient's maxillary teeth covered the mandibular teeth when she smiled, but her mandibular teeth showed when she spoke.

### TREATMENT PLAN

A conservative cosmetic treatment plan was developed that included the placement of eight maxillary bonded porcelain restorations to create harmony and balance in the maxillary arch, and power bleaching (Zoom, Discus Dental; Culver City, CA) on the mandibular arch. The goal was to be conservative in preparation design while meeting

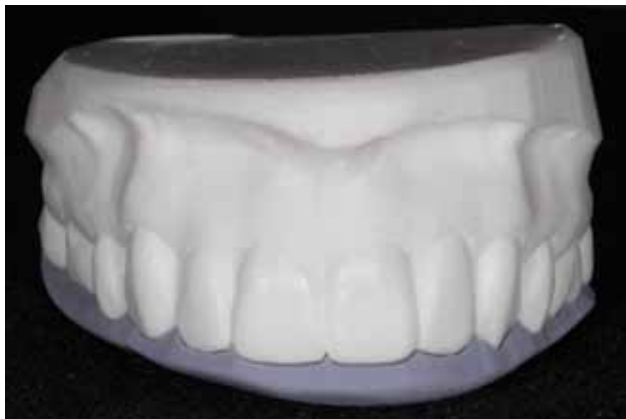

Figure 3: The incisal matrix is placed over a model fabricated from the diagnostic wax-up.



Figure 4: The facial index is seated over the preoperative model. Pencil marks indicate where tooth structure must be removed to create space for the restorative material.

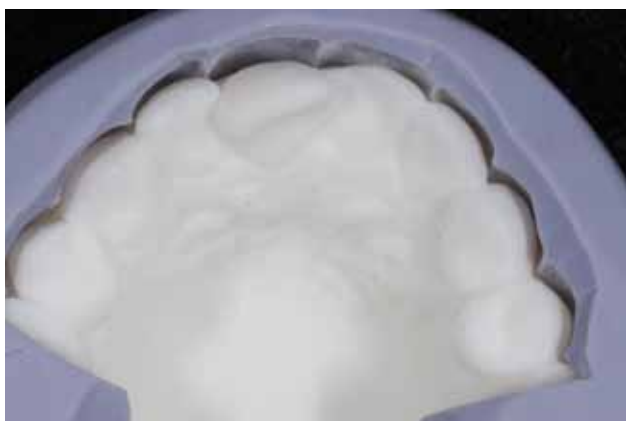

Figure 5: Incisal view of the facial index, showing uniform facial clearance for porcelain in the first slice.

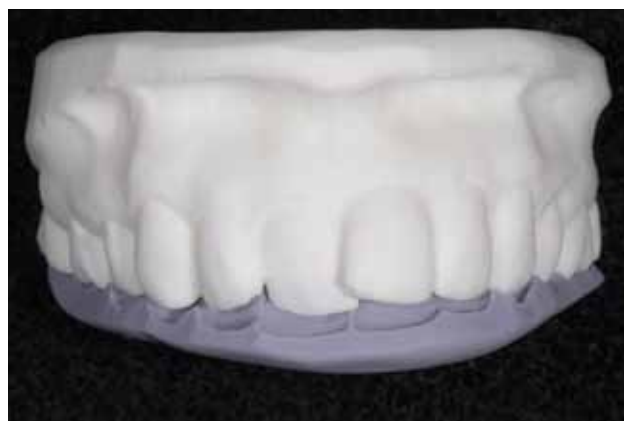

Figure 6: Incomplete seating of the incisal matrix, due to the lingually positioned incisor.

the esthetic demands of the case. This was accomplished with minimal removal of tooth structure on the fewest number of teeth necessary for creating the desired result. The definitive porcelain restorations were delivered to the patient, resulting in a harmonious and balanced esthetic outcome (Fig 2).

## TREATMENT

### CONSERVATIVE PREPARATION TECHNIQUE

The current approach to tooth preparation addresses the final volume of the teeth, as represented by an additive diagnostic wax-up,

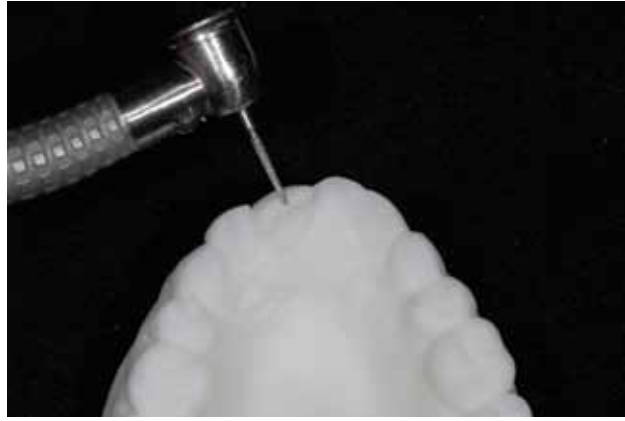with well-adapted labial and incisal silicone matrices (Fig 3). (I demonstrated this technique during a hands-on course at the 25th Anniversary AACD Scientific Session; it illustrated the step-by-step protocol for using matrices to guide the removal of tooth structure.)

First, the labial index is placed over the preoperative model, after which the teeth that are protruding facially can be evaluated (Fig 4). These areas must be brought back into proper arch form alignment by using a diamond bur (Brasseler USA; Savannah, GA). These protrusions are marked in pencil and then

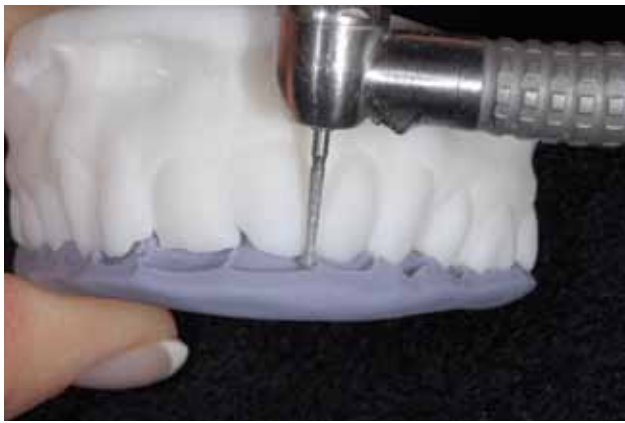trimmed away until the silicone matrix seats passively.<sup>3</sup>

Uniform facial clearance is necessary, but the amount and depth of tooth structure removal depends upon the restorative material to be used, as well as the patient's desired final shade. Therefore, the space created between the preparation and the matrix can vary from .3 mm to 1.5 mm.

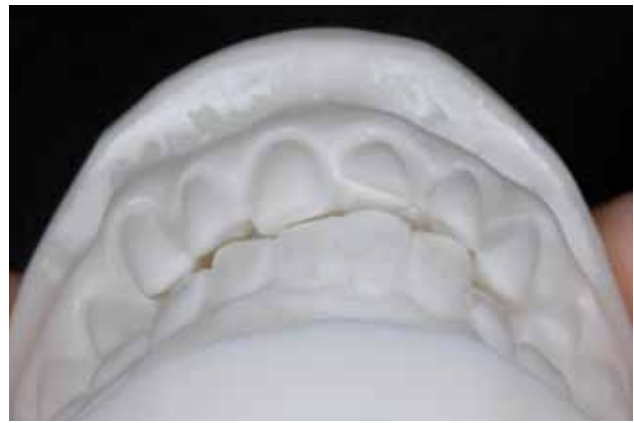
Once this parameter is achieved, the incisal portion of the index is sliced away, and the index can be used as a guide for removing the middle third of the preparation.



*Figure 7: The lingual portion of this tooth is contoured buccally using a diamond bur, until a passive seat in the matrix occurs.*



*Figure 8: Interdental preparation can be evaluated and executed.*



*Figure 9: The function and thickness of the ceramic are evaluated.*

Note that only one third of the tooth is prepared at a time, based upon the minimal requirements necessary to provide space for the restorative material in that zone. The middle third facial reduction is accomplished by removing stone in this area until a uniform clearance is achieved (Fig 5). Once the middle third is prepared, the middle portion of the index is sliced away, and the index can be used as a guide for removing the remaining cervical portion of the preparation.

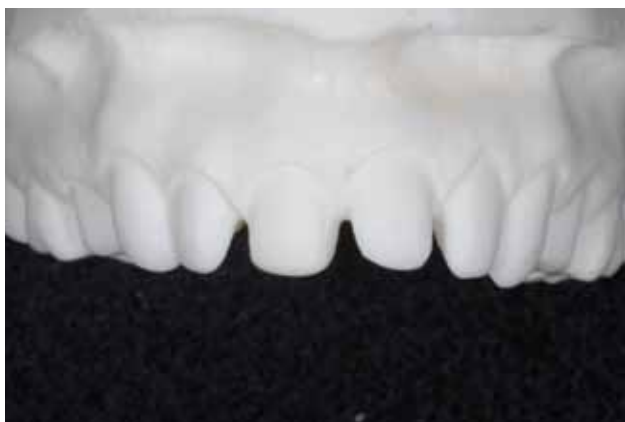The gingival chamfer margin should be placed in the enamel (i.e.,

following the contour of the soft tissue) to depths of 0.3 mm to 0.7 mm, depending upon the color desired for the final restoration. If the buccal corridor is to be expanded, the premolar preparations may require only a gingival chamfer and roughening of the enamel on the facial aspect, with an incisal overlap on the buccal cusp. The plane of the incisal third must be rolled toward the lingual to allow space for both tooth form and light transmission.

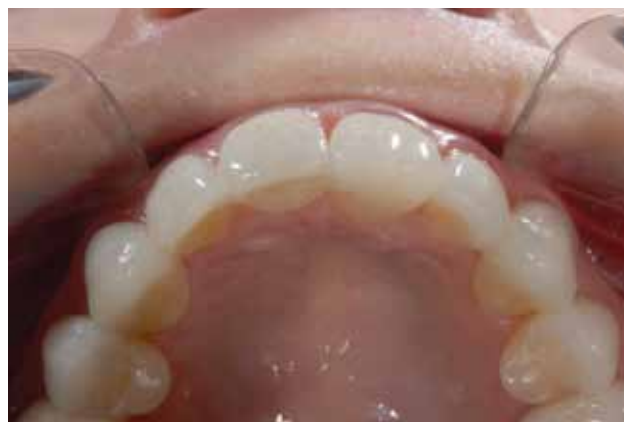When the facial preparations are accomplished, the use of the facial matrix is complete.

The next step in the process is to place the incisal guide over the prepared model. Seating was complete in this case due to the lingually positioned incisor (Fig 6).<sup>4</sup> The lingual portion of this tooth must be contoured labially until a passive seat of the model in the index is achieved (Fig 7).

At this point, interdental preparation can be evaluated and executed. When looking straight at the model, the tooth must be centered in the incisal matrix. Any portion of the tooth that is outside this boundary must be removed or recontoured. In



*Figure 10: The definitively prepared model displays rounded transition zones, angles, and corners.*



*Figure 11: The occlusal view of the completed restorations displays a symmetrical arch form and the appearance of instant orthodontics.*

this case, the central and lateral incisors require full slice preparation. However, it was only necessary to re-contour the interproximal contacts of the remaining teeth in order to center them in the matrix (Fig 8).

The exact incisal lengths should be 2.0 mm from the edge of the incisal matrix. The porcelain will overlap the remaining incisal tooth structure and terminate on the lingual surface in a butt margin, adding strength to the ceramic and providing a vertical stop during cementation.<sup>5,6</sup>

Function and thickness of the ceramic are evaluated when determining lingual margin location and palatal coverage by visualizing the remaining occlusal clearance between the preparation and opposing models (Fig 9). In this case, the left central incisor was positioned facially. When removing that portion of the tooth from the corrected arch form, a sliver of tooth thinner than 1.5 mm remained labio-lingually. This portion of the tooth was susceptible to fracture and, therefore, full palatal coverage was indicated.<sup>7</sup>

Function in all excursions must be tested; and angles, transitions,

and corners should be rounded to avoid creating internal stress fractures in the ceramic (Fig 10). When viewed from the labial aspect, the facial porcelain form should be superimposed over the preparations with equal symmetry, so that it appears that "instant orthodontics" were performed (Fig 11).<sup>8</sup>

### SUMMARY

In order to treat complex space management cases, it is necessary for dentists to master preparation design principles and the use of technical support tools such as indices. These techniques and tools will guide the dentist toward the conservative removal of tooth structure, while simultaneously ensuring the best esthetic outcome.

### Acknowledgments

*The author thanks ceramist Brad Patrick (Patrick Dental Arts; Bend, OR) for fabricating the restorations in this case; and Heraeus for supplying the Venus porcelain ceramics used in this case, as well as for sponsoring the hands-on portion of this course.*

### AACD Acknowledgment

*The American Academy of Cosmetic Dentistry recognizes Dr. Joyce L. Bassett as an AACD Accredited Member (AAACD).*

### References

1. Magne P, Belser UC. Novel porcelain laminate preparation approach driven by a diagnostic mock-up. *J Esthet Restor Dent.* 2004;16:7-16.
2. Garber DA, Goldstein RE, Feinman RA. *Porcelain laminate veneers.* Chicago: Quintessence; 1998.
3. Magne P, Belser U. Bonded porcelain restorations in the anterior dentition: a biomimetic approach. Hanover Park (IL): Quintessence; 2002. p. 240-51.
4. Terry DA, Leinfelder KF, Geller W, et al. *Principles of tooth preparation. Aesthetic and restorative dentistry: material selection and technique.* 1st ed. Stillwater (MN): Everest Publishing Media; 2009. p. 45-79.
5. Gürel G. *The science and art of porcelain laminate veneers.* Hanover Park (IL): Quintessence; 2003. p. 241-76.
6. Gürel G. Predictable, precise, and repeatable tooth preparation for porcelain laminate veneers. *Pract Proced Aesthet Dent.* 2003;15(1):17-26.
7. Crispin BJ. Full veneers: the functional and esthetic application of bonded ceramics. *Compendium.* 1994;15(3):284-94.
8. Christiansen GJ. Have porcelain veneers arrived? *JADA.* 1991;122(1):8.



## IN-OFFICE MODEL PREPARATION FOR COSMETIC SMILE DESIGN AND VIRTUAL TRY-INS



by  
 Mitch A. Conditt, DDS  
 Fort Worth, TX  
[www.drmitchconditt.com](http://www.drmitchconditt.com)

Michael L. Milne, CDT  
 Las Vegas, NV  
[sunrisedti@aol.com](mailto:sunrisedti@aol.com)

*Editor's note: This article is based on a MicroDental, a DTI Company-sponsored hands-on workshop at the 25th Anniversary AACD Scientific Session in Honolulu, Hawaii.*

### INTRODUCTION

One of the biggest challenges facing clinicians during the treatment presentation phase is helping patients visualize the actual transformation that can occur in their smiles. Computerized cosmetic imaging and snap-on plastic temporaries have helped in this endeavor to some degree. While there also is much to be said for well-crafted, laboratory-fabricated diagnostic wax-ups, none of these methods actually show the patient the final result in his or her mouth.

As we all know, patients often change their minds while they wait for the diagnostic wax-up to be fabricated in the laboratory—or spend the money on other discretionary items—and do not opt to rejuvenate their smiles. With the help of my ceramist, I implemented virtual wax try-ins in my practice four years ago in an effort to combat this dilemma. I would not use any other method today.

---

*Patients often change their minds about cosmetic dental treatments, either while waiting for the diagnostic wax-up to be fabricated in the laboratory, or because they have spent the money on other discretionary items.*

---

Creating a virtual wax try-in is a quick and simple process that takes about 30 minutes to complete. It enables clinicians to lengthen the teeth, alter tooth shape, brighten the teeth, or create shade uniformity, depending on the patient's desires. The virtual try-in is very thin and eliminates the bulky look sometimes associated with snap-on temporaries.





# WHITEST teeth. EVERY time.

## Guaranteed.

{ KÖR }  
Whitening  
Deep Bleaching™ System



*"I never believed ANY whitening system could be this effective!"*

—Dave Wolkamp, DDS, Overland Park, KS

*"Your refrigeration makes a huge difference in effectiveness."*

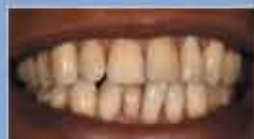—Gary Saplenza, DMD, Merchantville, NJ

*"Even my most sensitive patients are thrilled."*

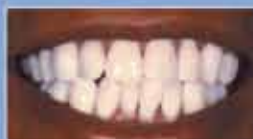—Brian Weibang, DDS, Garfield, OH

- Predictable "WOW" results
- Permanent whiteness
- Patients may still consume coffee, tea, red wine, etc.
- Low to no sensitivity
- Continuous refrigeration from manufacture to your office
- Perfect for everyone – average patients, tetracycline, fluorosis, and geriatric patients

Developed by  
Whitening Science  
Expert  
Dr. Rod Kurthy



Before



After

Call and ask about our start-up special at 1-866-763-7753.  
Satisfaction guaranteed – or your money back!

See what other dentists are saying at [www.KORwhitening.com](http://www.KORwhitening.com).





*Figure 1: Full-facial preoperative view of a patient interested in—yet still slightly unsure about—undergoing cosmetic dental treatment.*

By implementing this approach, patients can immediately see the dynamics of their new smile and how it fits with their overall look. They appreciate instantly being able to determine what they like and do not like about their new smile. This benefits clinicians by providing the opportunity to make any necessary adjustments to the proposed smile design well in advance of any official prescription or fabrication.

If patients choose to, they can wear the virtual try-in home to show their spouse, or back to work to really gain a realistic sense of what the final result could look like. As a result, they are much more receptive to accepting treatment. In fact, many have asked to initiate treatment immediately. In our experience, not only has the treatment acceptance rate multiplied exponentially from using virtual try-in, but so have referrals.

## CASE PRESENTATION

A female patient presented with a nice smile (Fig 1) that had previously been restored with four porcelain-fused-to-metal (PFM) crowns in the maxillary anterior region (Fig 2). The crowns were slightly flared

and opaque, and black triangles were becoming more evident at the gum line. Additionally, her bicuspids were slightly collapsed inward.

---

*By implementing this approach, patients can immediately see the dynamics of their new smile and how it fits with their overall look.*

---

Her overall goal was to create a more natural, lifelike look that exuded dimensional color, rather than the flat look that she currently had. She also wanted to slightly modify the size, length, and shape of her teeth and eliminate the black triangles. However, even with such clear goals in mind, she still was not entirely sure she wanted to move forward with cosmetic dental treatment.

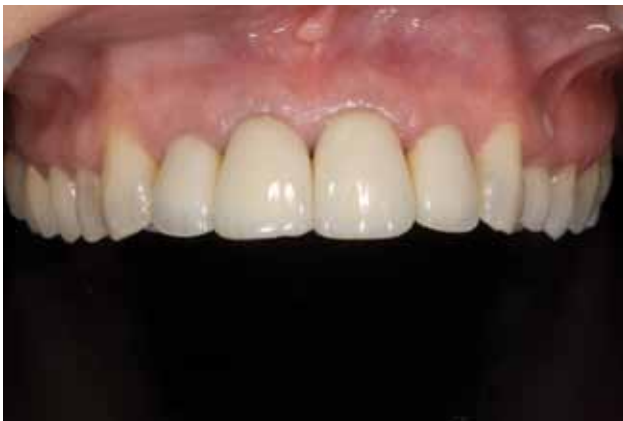In order to provide the patient with a realistic sense of what her smile could look like, a virtual try-in of teeth #4-13 was suggested, and the patient agreed.

In the dental office, the following steps were followed to create the virtual try-in:

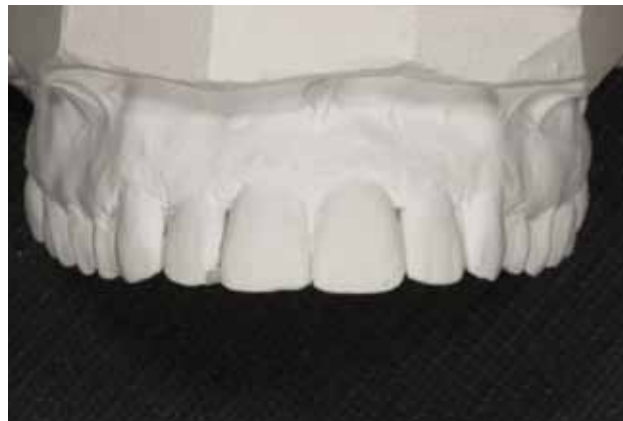1. A diagnostic impression was taken of the patient's maxillary

arch, after which a stone model was created (Fig 3). So that the virtual try-in will fit the patient's existing dentition, no tooth structure is removed from the diagnostic model. This can be performed when creating the actual wax-up for the provisional restorations after the patient accepts treatment.

2. A duplicate stone model was made (in this case, in a different color stone) for use as a guide for the virtual wax-up (Fig 4).
3. A thin to moderate layer of wax (Ultra-Waxer, Kerr Labs, Sybron Dental Specialties; Orange, CA) was applied to the model and shaped to the desired size and length (Fig 5). It was not necessary to apply wax to all areas of the teeth, particularly where the tooth shape was already ideal. Note that this step can be performed by a sufficiently experienced dental assistant.
4. A putty matrix (Sil-Tech, Ivoclar Vivadent; Amherst, NY) was created from this waxed-up model (Fig 6).
5. The putty matrix was then filled with a bis-acryl provisional crown and bridge material



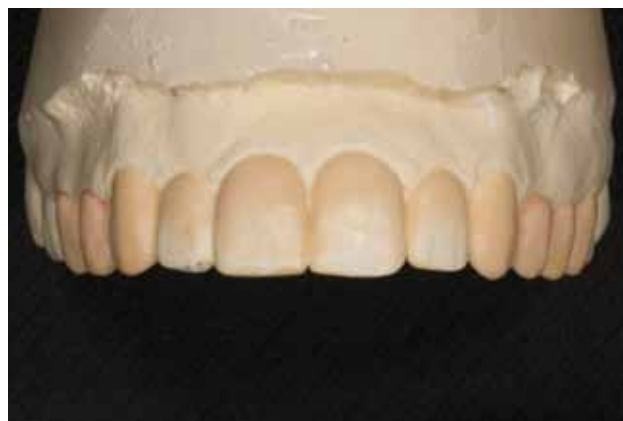*Figure 2: Close-up preoperative retracted view showing pre-existing crowns that are slightly flared and opaque, with black triangles evident at the gum line.*



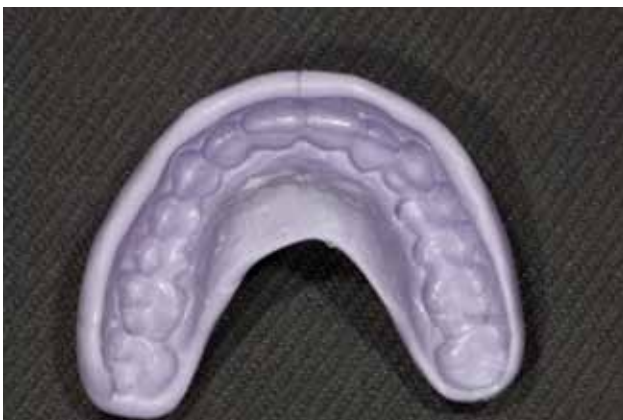*Figure 3: View of the stone model created for use in making the virtual try-in.*



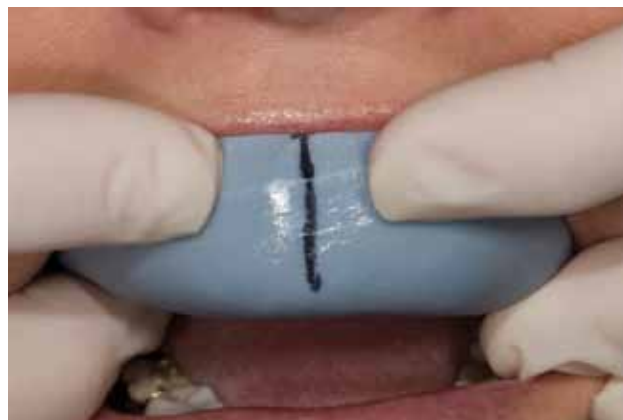*Figure 4: View of wax and waxer used for application on the stone model.*



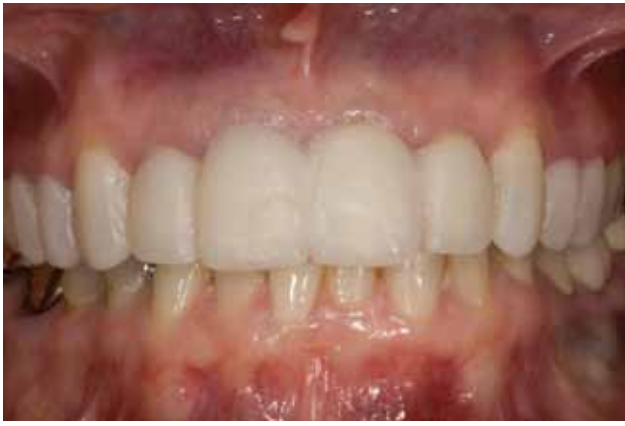*Figure 5: Wax was applied to the model to create the desired size and length of proposed restorations. It was not necessary to apply wax to all areas.*



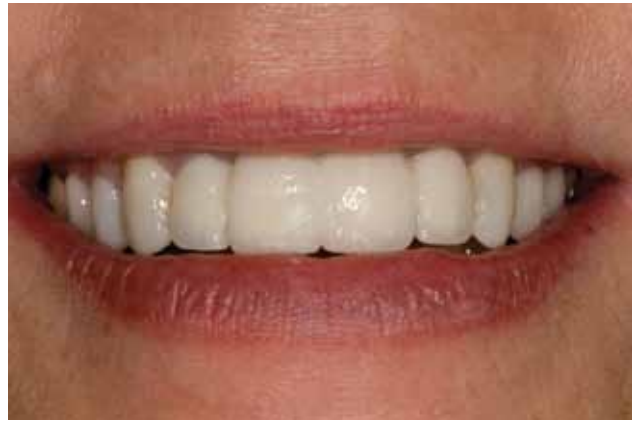*Figure 6: View of the putty matrix created from the waxed-up model.*



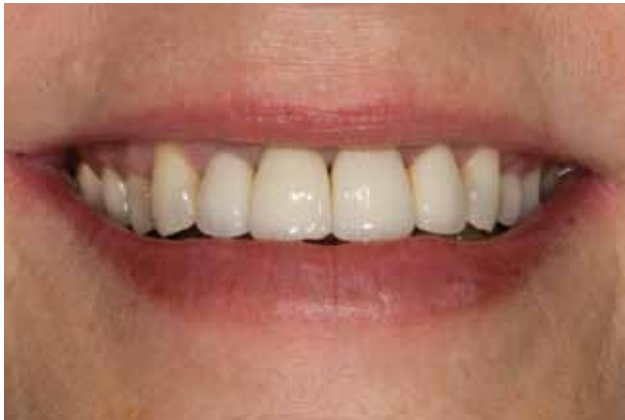*Figure 7: The putty matrix filled with provisional material was placed in the patient's mouth, with rubbing pressure applied to the gingival area to remove excess material.*



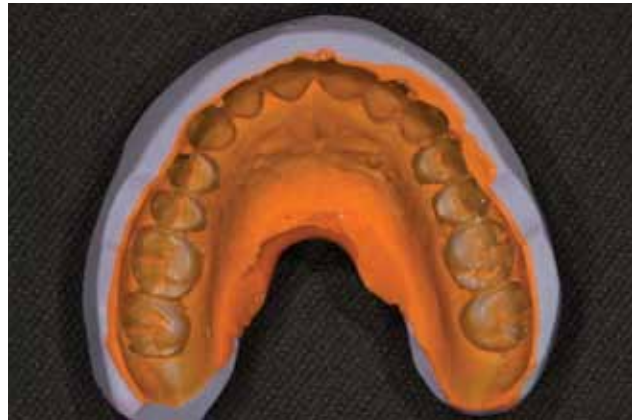*Figure 8: After removal of the matrix, the virtual try-in remained temporarily adhered to the teeth. Note that there was very little flash beyond the teeth.*



*Figure 9: View of the patient in natural smile while wearing the virtual try-in. Note the dramatic difference in the appearance of her teeth compared to Figure 10.*



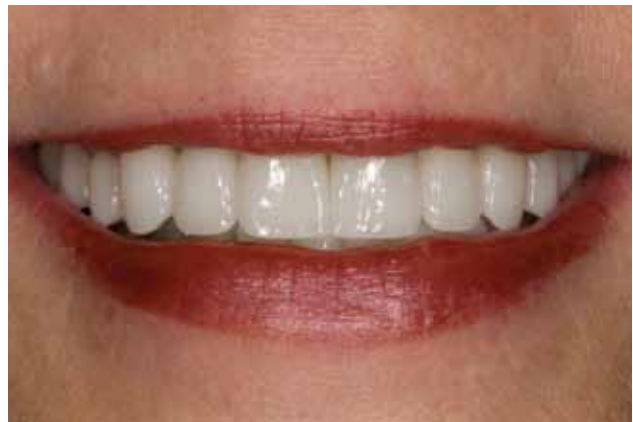*Figure 10: Preoperative view of the patient in natural smile without the virtual try-in.*



*Figure 11: The original virtual try-in matrix was used for taking an impression of the new and enhanced wax-up so that temporaries could be made.*



*Figure 12: Full-facial view of the patient in provisional restorations. Slight canting of the anteriors was corrected in the final porcelain restorations.*



*Figure 13: Close-up postoperative view of the patient's natural smile following cementation of her final porcelain restorations.*



*Figure 14: Final full-facial postoperative view of the patient following completion of her cosmetic dental treatment.*

(Venus Temporary Crown & Bridge Material, Heraeus; South Bend, IN), after which it was placed in the patient's mouth. A lubricant (Carmex Original or similar) was applied to the facial aspect of the matrix. Pressure was applied in a rubbing fashion along the border of the gingival and tooth junction to facilitate removal of any excess temporary material beyond the margins (Fig 7).

6. The putty matrix was gently removed from the mouth, leaving the virtual try-in temporarily adhered to the patient's teeth (Fig 8).

## DISCUSSION

The patient in this case requested cosmetic dental enhancement of 10 teeth. Despite the fact that the wax-up for the virtual try-in was fabricated in the dental office in a matter of minutes, the difference between her original smile and the virtual try-in is remarkable (Figs 9 & 10).

However, there are many times when patients only consider restoring six teeth. It is important to present patients who already have a high

level of interest in restoring their teeth with all appropriate options for enhancing their smiles. In such cases, the virtual try-in allows clinicians to demonstrate the esthetic value of enhancing 10 teeth instead of just six. When the patient personally sees the difference between restoring the entire smile line compared to only the front teeth, they typically choose treatment for all 10 teeth.

To proceed with treatment in this case, the wax-up used for the virtual try-in was improved by removing stone in some areas, and adding wax in others to create a more accurate wax-up. The new wax-up was used to fabricate another putty matrix (Sil-Tech) for use in making the patient's temporaries by placing a light-body impression material (Take One Advanced Light Body, Kerr Dental) inside the original virtual try-in matrix and placing it over the new wax-up (Fig 11).

Teeth #4-13 were then prepared and provisionalized using a temporary crown and bridge material (Venus Temporary Crown & Bridge Material) (Fig 12). Although there was some slight canting of the anteriors in the temporaries, this was

corrected in the final porcelain restorations with the aid of a stick bite and photography.

## CONCLUSION

The patient in the case illustrated here was so excited about the difference she saw in her smile based on the virtual try-in that she asked to begin treatment that day. Were it not for the power and instant gratification of the virtual try-in, she might not have accepted treatment so quickly. This probably would not have occurred with any other visualization technique.

Her final restorations (MACVeneers, MicroDental Laboratory; Las Vegas, NV) were tried in and cemented two weeks later using a universal adhesive resin cement (NX3 Nexus® 3rd Generation, Kerr Dental) (Fig 13). The patient hasn't stopped smiling since (Fig 14).



# WHAT'S Happening in GRAPEVINE?



**T**echnology and new media relevant in today's world will be explored. Cone beam 3D imaging, digital impressing, and computer-designed restorations are rapidly changing what we do in dentistry. These technologies, and many others, will be on display during hands-on workshops and lectures, and in "AACD Digital World," an interactive demonstration area located in the exhibit hall.



**D**eeper learning will take place through focused presentations. Writing, speaking, volunteer training, and marketing are some of the highlighted topics. Often overlooked, these extremely important professional development skills can accelerate careers. Courses are designed for a variety of skills and a variety of skill levels.



**I**nternational laboratory models will be reviewed, including those from Japan and Europe, as well as the examination of traditional laboratory techniques and refinement of these techniques. The latest technologies in the field will be revealed.



**A**n abundant array of high-energy, elegant, casual, and philanthropic social events will be available for all to enjoy. The AACD believes like-minded dental professionals offer an invaluable resource: Shared knowledge. These social events are designed to foster relationships and the sharing of knowledge in an open and friendly atmosphere.

Join thousands of passionate dental professionals and more than 80 educators, including Pat Allen, DDS, Newton Fahl, DDS, John Kois, DMD, MS, and Lorenzo Vanini, DDS, MD, in putting Grapevine, Texas on the map.

**Visit [www.aacd.com](http://www.aacd.com) for the complete program and to register today. Hurry! Course selection opens Friday, December 4, 2009.**

# Grapevine, Texas

(just 10 miles from the Dallas/Fort Worth International Airport)



December

Monday	Tuesday	Wednesday	Thursday	Friday	Saturday	Sunday
	1	2	3	Course Selection Opens	5	6
7	8	9	10	11	12	13
14	15	16	17	18	19	20

**26TH** Annual AACD Scientific Session

What's the

**BIG IDEA!**

AMERICAN ACADEMY OF COSMETIC DENTISTRY  
TUESDAY, APRIL 27 THRU SATURDAY, MAY 1, 2010

GRAPEVINE, TEXAS [WWW.AACD.COM](http://WWW.AACD.COM)



## ON TARGET: PART I—CREATING SYSTEMS FOR SUCCESS IN A CHANGING WORK ENVIRONMENT



by Cathy Jameson  
Davis, OK  
[www.jamesonmanagement.com](http://www.jamesonmanagement.com)

*Editor's note: This article is based on a lecture held at the 25th Anniversary AACD Scientific Session in Honolulu, Hawaii.*

### INTRODUCTION

One of the challenges that many dental professionals face is balancing their commitment to being a healthcare provider with being a successful businessperson. There is no question that your main purpose is serving your patients and serving them well. You went into dentistry because you wanted to be in the healthcare profession, and you wanted to make a difference in people's lives. Then you realized that running a practice takes a great deal more expertise than simply performing dental procedures. Running a business takes an entirely different set of skills.

---

*Running a practice takes a great deal more expertise than simply performing dental procedures.*

---

You have spent a great deal of time, study, and money in school—and continue to do so—to master your clinical and cosmetic dentistry skills. You will always work on improving those skills, as well as learning new and better ones. The same commitment must be given to the business aspect of your practice. A great deal of time, study, and money must be invested in learning how to effectively and successfully run a business and leading your team members, as well as patients. Both investments must and will pay for themselves multifold if done appropriately. In your clinical, management, and leadership development, there will never be a day when you “arrive”;



# Heraeus

## Venus<sup>®</sup> Temp C&B

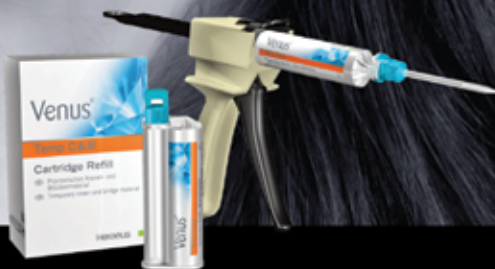Transforming Temporary  
into Extraordinary.

- Exceptional strength and wear resistance
- Duplicating nature with life-like esthetic results
- Ideal for long-span bridges due to low flexural modulus
- Low polymerization shrinkage resulting in optimal marginal adaptation

**PURCHASE 3 Venus Temp C&B cartridges,  
RECEIVE 1 FREE!** 1000802630

“The temporaries literally come to life in the mouth. I need proper form, function, and esthetics during the provisional period and Venus Temp C&B gives me all of this.”

**Mitch Conditt, DDS**  
Member, AACD



Venus<sup>®</sup> is a trademark of Heraeus Kulzer GmbH. © 2009 Heraeus Kulzer, LLC 300 Heraeus Way, South Bend, IN 46614 Phone: (800) 431-1785 Fax: (877) 271-5211  
www.heraeus-kulzer-us.com www.smilebyvenus.com

**TO REDEEM FREE PRODUCTS:** Purchase products from an authorized Heraeus dealer in one transaction on one invoice between 10/1/09 and 12/31/09. Fax dealer invoice to (877) 271-5211 or mail to Heraeus, 300 Heraeus Way, South Bend, IN 46614, Attn: Free Goods Fulfillment. Not to be combined with any other offers. All offers subject to change. Heraeus reserves the right to limit quantities. Please allow 6-8 weeks from receipt of invoice for delivery. Dealer invoice and must be received by 1/31/10. **OFFER EXPIRES 12/31/09.**

**Venus<sup>®</sup>**  
The New Esthetics

rather, you will always be “arriving.” The objective of successful people and of successful business owners is to be in a constant state of improvement.

### CHANGES IN THE WORKPLACE AND THE WORKERS

This improvement involves improvement not only in clinical expertise, but also in leadership, as well as management. People in the workplace today are not the same and do not have the same wants and needs as workers in the past. While the “Baby Boomers” (born between 1946-1964) are the predominant employers today, they are working mostly with “Generation X”ers (1965-1980). The “Millennials” (1980—) are entering the workplace now in large numbers. While the research does not indicate a significant difference in work ethic, there is a major difference in work style. In order for the different generations to work well together, there must be an understanding and appreciation of those differences.<sup>1,2</sup>

Major changes have occurred in the worker and in the workplace from the past to the present. People in the workforce today are educated, experienced, highly skilled, and interested in being treated with well-earned respect for the skills that they have developed.<sup>3</sup> Drucker determined that nearly half of all workers in America are what he calls “knowledge workers.”<sup>3</sup> The number of knowledge workers in other countries is increasing substantially as well. Knowledge workers “own” their skills, says Drucker, and can pick up those skills and move to an organization where they can flourish. They can—and will—move if the situation is not ideal for them.<sup>3</sup>

Therefore, the challenges for the leaders of organizations have changed. These knowledge workers want to maximize their potential, find satisfaction in the workplace, and be respected by colleagues and employers alike. In order for employees to be ultimately productive, they cannot be treated as the employee of the past was treated; they can—and will—leave. In the past, the employer or “boss” had the upper hand and employees were, in a sense, “held captive.” Now the tables have turned. The employer/leader benefits from serving the employee, rather than the other way around. This leader understands the differences between the employee of times past and the new, knowledge workers of today and responds accordingly.

---

*The outstanding dental leader understands that his or her practice comprises numerous systems, and that those systems must reflect the changing work and workplace.*

---

### SYSTEMS: THE STRUCTURE OF A HEALTHY ORGANIZATION

Your practice is made up of a series of systems—systems that make it possible for you to practice dentistry in the manner you desire. If you are having problems or challenges or if you feel that your practice is not functioning at maximum capacity, the reason may be that you have one or more systems that are not functioning as well as possible. On the other hand, you may have a thriving, successful practice but want to take it to the next level. When systems improve, the performance of your team members can improve. Your productivity will be

a direct reflection of the success of your systems and of your team’s ability to administer those systems.

It is systems that give organizations strength, structure, and the ability to produce in a stable manner. Evolution and refinement of systems is imperative if a business is to remain viable.

Unique qualities within an organization determine the systems that are appropriate. The purpose of system development is to ensure that the people within the organization have the structure and support they need to be successful. There is no one method of management that is appropriate for all businesses or practices. While the major principles of management are the same, the individualization within each unique setting is what makes the difference.

Predetermined goals and clarity of desired end results must be aligned with carefully developed systems that support the achievement of these goals. Solid teamwork and a congenial group of people working together make this possible. Without order, peoples’ energies can be misdirected; this leads to chaos. However, without employees’ energy and desire, nothing occurs and inertia sets in.<sup>4</sup>

Leaders and managers have the responsibility and challenge of making sure that the systems support the people working the systems. Systems alone are not the answer to success. Systems managed by enthusiastic employees or knowledge workers who feel that they are contributing to the success of the whole are the answers. “One does not manage people. The task is to lead people. And the goal is to make productive the specific strengths and knowledge of each individual.”<sup>3</sup>

## SYSTEMS THINKING

Senge<sup>5</sup> believes in “systems thinking” and says that it is a discipline through which people grasp the vision of the entire company and the processes of that company. Systems thinking allows people to go beyond their own space and duties to a place where they realize the value of their role to the success of the whole. He calls his systems thinking the “Fifth Discipline,” and feels that it is because of systems thinking that organizations become progressive and long lasting. The five disciplines are as follows:

- personal mastery
- mental models
- building shared vision
- team learning
- systems thinking.<sup>5</sup>

Senge says that, “*For the first time in history, humankind has the capacity to create far more information than anyone can absorb, to foster far greater interdependency than anyone can manage and to accelerate change far faster than anyone’s ability to keep pace.*”<sup>5</sup>

While the intricacies of organizations today are becoming more and more complex, the requirement for accelerated leadership becomes more imperative. As he outlines systems thinking, Senge addresses the “*shift of mind from seeing parts to seeing wholes, from seeing people as helpless reactors to seeing them as active participants in shaping their reality, from reacting to the present to creating the future. Without systems thinking there is neither the incentive nor the means to integrate the learning disciplines once they have come into practice. Systems thinking is a conceptual framework, a body of knowledge, and tools that have*

*been developed over years to make the full patterns clearer and to help us see how to change them effectively.*”<sup>5</sup>

## SUMMARY

Set a goal for yourself and for your organization whereby you have all your major management systems in order. Be a “systems thinker.” Employ outstanding, enthusiastic team members to administer those systems. Have monitors in place that allow you to identify when one or more of your systems are not functioning to capacity. Then, as a leader, make necessary adjustments when necessary or desired to bring those systems into alignment. You will find that even the smallest, constructive adjustments, when added together, will lead to substantial improvement and measurably increased productivity.

Many doctors tell me that they just want to come in and do dentistry. They feel that the management of the business and of personnel is the most stressful part of the practice. Some doctors say that they would love dentistry if it weren’t for the challenges related to business and personnel. However, these challenges are real. And they will always be a part of an evolving organization. If you do not run your business as a healthy, profitable business, you will not be able to stay in business. If you are not in business, you certainly cannot serve patients.

Most of you do not have advanced degrees in business or in management. However, you expect to be masters at these skills even though you have not had formal training in these advanced level areas. Great people and great busi-

nesses reach out to coaches—experts in various fields—to provide assistance and training in skills that are necessary but heretofore not mastered. With this kind of advanced training in the intricate area of management and leadership, you will create your “ideal” practice. You can make it happen!

## References

1. Lord R, Farrington P. Age-related differences in motivation of knowledge workers. *Eng Mngmnt J*. 2006;18(3):20-6.
2. Ryan R. Live first, work second: getting inside the head of the next generation. Madison (WI): Next Generation Consulting; 2007.
3. Drucker P. Management challenges for the 21st century. New York: HarperCollins; 1999.
4. Durkheim E. The rules of sociological method. New York: The Free Press; 1982.
5. Senge P. The fifth discipline. New York: Doubleday; 2006.



## LABORATORY TECHNICIAN ACCREDITATION WORKSHOP



by Trevor R. Laingchild, RDT  
AACD Accredited Member  
(AAACD)  
Burlington, Ontario, Canada  
[www.burlingtondentalstudio.com](http://www.burlingtondentalstudio.com)

*Editor's note: This article is based on a workshop held at the 25th Anniversary AACD Scientific Session in Honolulu, Hawaii.*

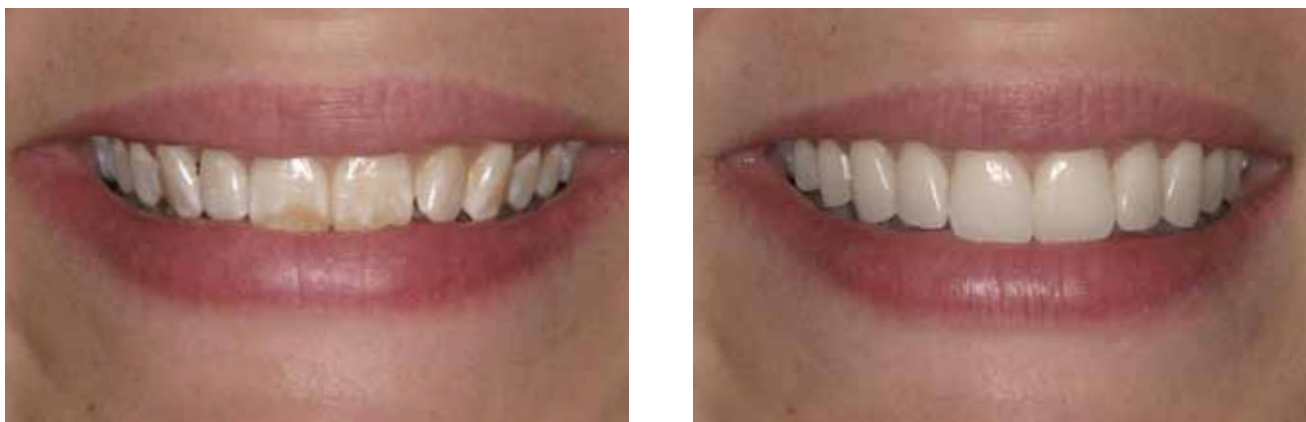### THE VALUE OF ACCREDITATION

The American Academy of Cosmetic Dentistry (AACD) is the largest cosmetic dental organization in the world. As part of its goal to be the preeminent resource to the profession and the public, it offers the most rigorous and respected credential in cosmetic dentistry. Accreditation is the credential that sets the standard for excellence in cosmetic dentistry.

Laboratory technicians should remember that Accredited laboratory technicians are considered a pool of talent within the AACD; and with over 7,000 members worldwide, these members often turn to them for services. This allows for unlimited opportunities, both nationally and internationally. Dentists want and need laboratory technicians to be Accredited. Dentists are well aware that providing excellent cosmetic dentistry for their patients often requires the skill and expertise of a talented technician. If the restorations are a work of art, it is a positive reflection on the dentist.

Accreditation teaches us that professional advancement is a continuous journey, which brings self-awareness, enabling us to challenge ourselves with a sharper eye, to a higher level of personal satisfaction and sense of accomplishment. As we travel on this journey, dentistry becomes more enjoyable, especially given an increased credibility within an Academy that offers comradeship and friendship second to none.

Undoubtedly, financial rewards can be achieved, which can be a catalyst to further personal and professional achievement.



**Figure 1: Passed case, preoperative and postoperative.**

*Dentistry and photo by Arthur I. Shapiro, DMD.*

*Restoration fabricated by Jenifer L. Wohlberg, AACD Accredited Member (AACD).*

## THE ACCREDITATION PROTOCOL

The Accreditation protocol is the process that individuals must undertake to achieve the Accreditation credential. The foundation consists of attending Annual AACD Scientific Sessions and specific workshops; along with submission of digital RAW, clinical, and bench-top photography; and supporting written reports as detailed within the protocol. Clinical cases are submitted by mail and are followed by a live oral examination after all cases are passed. The 12 AACD views for digital photography are demonstrated with helpful suggestions in *Photographic Documentation and Evaluation in Cosmetic Dentistry* (available from [www.aacd.com](http://www.aacd.com)). "A Zone of Excellence" describes the criteria by which cases are examined for meeting Accreditation standards. Members who begin the Accreditation program by passing the written examination start a five-year "time clock" in which to complete the process, or they must begin the process again.

## ACCREDITATION REQUIREMENTS

The requirements for the Accreditation process in the AACD are as follows:

- pass written examination
- attend required workshops
  - Accreditation workshop
  - Criteria workshop
- attend half of the annual scientific sessions since passing the written examination
- pass clinical case examinations
- pass oral examination.

**Written Examination:** The written examination tests fundamental knowledge in cosmetic dentistry and is administered at the annual scientific session. Sample examinations, along with suggested study materials, are available at [www.aacd.com](http://www.aacd.com). After passing the written examination and attending two scientific meetings, the member in the process obtains "sustaining member" status. The examination typically has a 90% pass rate and is consistently updated to maintain integrity with current knowledge, materials, and techniques.

### Clinical Case Examinations for Laboratory Technicians:

- Case Type I: Six or More Indirect Restorations
- Case Type II: One or Two Indirect Restorations

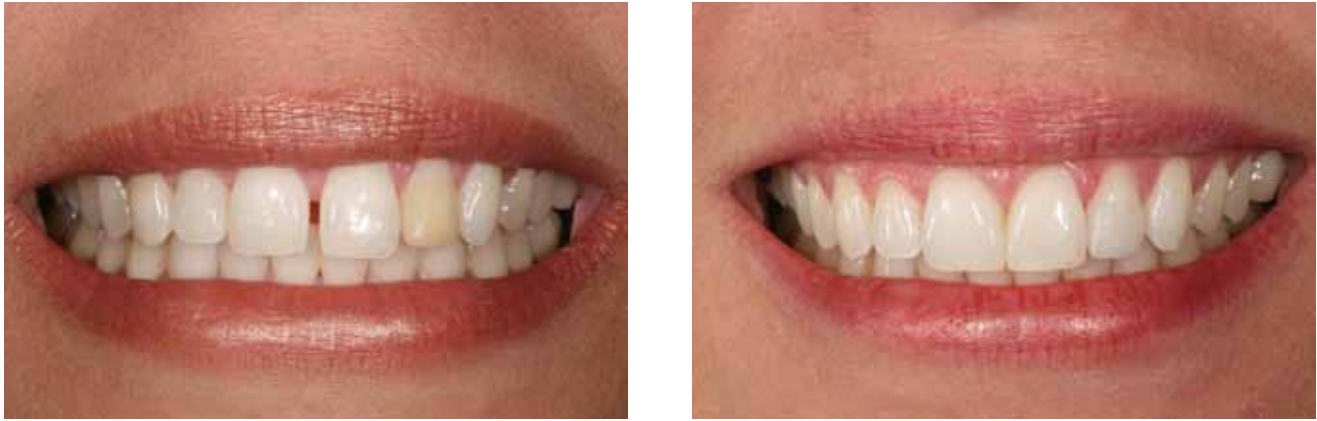- Case Type III: Tooth Replacement (Bridge or Implant).

### Case Type I (Six or More Indirect Restorations)

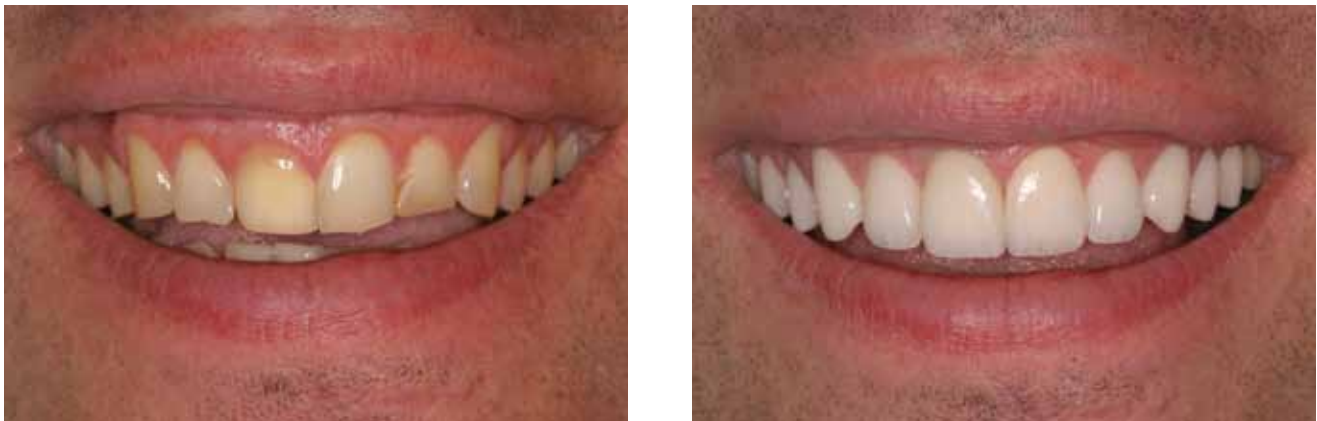This clinical case requires treating six or more indirect restorations, treating maxillary incisors and canines (Fig 1). Using any combination of crowns and veneers, this case type requires the use of smile design principles and tests an individual's ability to create restorative dental excellence with the dentist. The principles of smile design are outlined in *Guide to Accreditation Criteria* (available from [www.aacd.com](http://www.aacd.com)).

### Case Type II (One or Two Indirect Restorations)

This clinical case requires one or two indirect restorations, treating maxillary incisors (Fig 2); adjacent teeth should have no indirect restorations, although they may have direct restorations. Using crowns or veneers, this case type tests the individual's ability to match the natural surrounding dentition. Smile design principles play a lesser role in this scenario, with elements of color, anatomy, and luster carrying a heavier weight in the examination. The treatment alternatives are: One



**Figure 2: Passed case, preoperative and postoperative.**  
Dentistry and photo by John C. Roberts, DDS, AACD Accredited Member (AAACD).  
Restoration fabricated by Jeffery D. Bennett.



**Figure 3: Passed case, preoperative and postoperative.**  
Dentistry by Steve Gorman, DDS, AACD Accredited Member (AAACD).  
Implant placement by Paul S. Petrungaro, DDS.  
Restoration fabricated and photo by Edgar Jimenez, AACD Accredited Member (AAACD).

or two centrals, one or two laterals, or one central and one lateral.

#### *Case Type III (Tooth Replacement (Bridge or Implant))*

Using either a bridge or implant, this case type tests the individual's ability to handle the tissue in an edentulous space (Fig 3). Smile design may or may not play a role in the examination, depending on the number of teeth treated.

**Bridge:** The bridge requires at least one pontic replacement of a maxillary incisor or canine.

**Implant:** In addition to the required photography, the implant submission requires a preoperative x-ray showing a space or failing tooth prior to implant placement.

**All Case Types:** It should be remembered that all required restored teeth are permanent maxillary anteriors; any additional treated teeth will also be judged on submission. All clinical restorative treatment should be included in detail within the written report.

**Clinical Case Submissions:** The following are required for all case submissions:

- completed AACD case submission form
- completed AACD photo release form
- completed AACD member in process agreement
- compact discs with Raw and JPG folders of the AACD 12 preoperative and postoperative views, including technique photography for all three cases

- radiographic documentation
- three completed written reports following AACD protocol and template (sample report provided at [aacd.com](http://aacd.com)).

**Oral Examination:** This is the candidate's verification of the clinical case submissions, with discussions on techniques and materials that were used to treat the case. The process also consists of a component to test diagnostic skills and problem-solving abilities. The candidates bring copies of submitted passed cases and reports as they were submitted for examination to AACD headquarters in Madison, Wisconsin.

#### ACCREDITATION AWARD

The award for achieving Accreditation is given at the AACD's Annual Scientific Session. Newly Accredited

dentists and laboratory technicians are recognized and receive medallions symbolizing their accomplishment; to the rousing applause of their colleagues. They then receive their Accreditation awards at the Celebration of Excellence Gala. With the culmination of this achievement there is an incomparable excitement about and passion for cosmetic dentistry—this is a moment and a journey you must not miss.

#### CONCLUSION

It is my hope that all members attend the AACD Accreditation workshops, gain knowledge and clarity regarding the required protocol, and receive the motivation and empowerment to begin the journey to Accreditation.

Accreditation teaches us that professional advancement is a continuous journey that brings

self-awareness, enabling us to challenge ourselves to a higher level of personal satisfaction and sense of accomplishment.

My heartfelt best wishes to all who travel the Accreditation path.

#### Acknowledgment

*The author expresses gratitude to the AACD Accreditation Committee; and especially to Mr. Michael Morris, CDT, AACD Accredited Fellow Member (FAACD), for their assistance with this article.*

#### AACD Acknowledgement

*The American Academy of Cosmetic Dentistry recognizes Mr. Trevor Laingchild as an AACD Accredited Member (AAACD).*



## Show Us Your Skills!



Publishing your best clinical case on the cover of the *Journal of Cosmetic Dentistry (JCD)* is an incredible way to showcase your skills to dental colleagues, the dental profession, and your patients. AACD's publication team is consistently accepting cover cases and manuscript submissions for future publication in the *JCD*. Imagine your case in print. Send us your cover and manuscript submission today.

[www.aacd.com](http://www.aacd.com) • 800.543.9220 • 608.222.8583 • [publications@aacd.com](mailto:publications@aacd.com)



AMERICAN ACADEMY  
OF COSMETIC DENTISTRY

## CREATING NATURAL ESTHETIC VENEERS UTILIZING A NEXT GENERATION COMPOSITE MATERIAL



by Frank J. Milnar, DDS  
AACD Accredited Member  
(AAACD)  
St. Paul, MN  
Frank@milnardds.com

*Editor's note: This article is based on a GC America, Inc., sponsored hands-on workshop at the 25th Anniversary AACD Scientific Session in Honolulu, Hawaii. The author receives material and financial support from GC America. The article was also co-written and partially subsidized by GC America.*

### ABSTRACT

The direct composite veneer is among the more minimally invasive treatment modalities available for the rejuvenation and restoration of a patient's smile. However, placing a direct composite veneer in a naturally esthetic manner requires the clinician to enhance his or her skills with an understanding of polychromicity; the different thicknesses of dentin and enamel in different parts of the tooth; and how to alter the hue, chroma, and value of the sequentially layered veneer restoration. This article will help the reader understand how to use a composite system with ease, particularly when employing different opacities and translucencies, as well as increase his or her confidence when restoring composite veneer cases by utilizing predictable methods. The article also describes how to impart ceramist-like surface texture to composite veneer restorations using various finishing and polishing techniques.

---

*The techniques [addressed here] are representative of the minimally invasive and responsible esthetics paradigm.*

---

Note: The images featured in this article were generated from those used during a hands-on workshop conducted by the author at the American Academy of Cosmetic Dentistry's 25th Anniversary Scientific Session in Honolulu, Hawaii. The techniques taught during the workshop are representative of the minimally invasive and responsible esthetics paradigm. These concepts guide



**“e.max LITHIUM  
DISILICATE IS THE  
MOST ROBUST  
CERAMIC SYSTEM  
TESTED TO DATE.”\***

**e.max<sup>®</sup>  
IPS**

**e.max<sup>®</sup> changes everything.<sup>™</sup>**

The durability of lithium disilicate glass-ceramic crowns is higher than that of veneered zirconium oxide. Lithium disilicate is now the material of choice for single crowns: strong, esthetic, economical. Experience the benefits of **IPS e.max<sup>®</sup>** today.

**\*Mouth Motion Fatigue and Durability Study**

Petra C. Guess, Ricardo Zavanelli, Nelson Silva and Van P. Thompson, NYU

<sup>1</sup> 90% failure by 100,000 cycles

<sup>2</sup> No failures at 1 million cycles

**[emaxchangeseverything.com](http://emaxchangeseverything.com)**


**all ceramic  
all you need**

**100% CUSTOMER SATISFACTION  
GUARANTEED!**

**[www.ivoclarvivadent.com](http://www.ivoclarvivadent.com)**

Call us toll free at 1-800-533-6825 in the U.S., 1-800-263-8182 in Canada.  
©2009 Ivoclar Vivadent, Inc. IPS e.max is a registered trademark of Ivoclar Vivadent.

**ivoclar  
vivadent**  
passion vision innovation



Accreditation candidates through Case Types IV and V, according to the AACD Accreditation guidelines.

## INTRODUCTION

Of paramount importance in providing patients with minimally invasive treatments that demonstrate the practice of "responsible esthetics" is the recognition of the optimal path for patient oral health. This inherently mandates a thorough examination, diagnosis, risk assessment, and treatment planning before initiating the removal of any tooth structure. Too often, aggressive preparations are seen for composite veneers that could otherwise be completed with only slight removal of tooth structure or a conservative form of enamelplasty.<sup>1</sup>

As an Accreditation Examiner for the American Academy of Cosmetic Dentistry (AACD), it is discouraging to see too much tooth structure sacrificed unnecessarily for the sake of esthetics, particularly when more conservative preparations can be completed. As part of the Accreditation evaluation for direct composite veneers, the removal of tooth structure will be judged critically if it is overly aggressive. Such an approach is consistent with the AACD's core value of encouraging dental treatment that minimizes the loss of healthy human tissue.

Once the scope of necessary treatment is determined based on clinical/esthetic needs and patient expectations, the AACD's core values further challenge esthetic dentists to develop treatment decisions based on a foundation of evidence-based protocols, sound clinical judgment, and the use of innovation in technology and materials to deliver dentistry that is predictable and long-

lasting. It is only then that we can undertake the task of esthetically restoring a patient's smile using minimally invasive treatment protocols, when and where appropriate, that are consistent with the long-term health and needs of the patient.

Clearly, the direct composite veneer is among the more minimally invasive treatment modalities available to rejuvenate and restore a patient's smile. In many instances, it can be a reversible alternative, but it is one that requires the clinician to enhance his or her skills with an understanding of polychromicity; the different thicknesses of dentin and enamel in different parts of the tooth; and how to alter the hue, chroma and value of the sequentially layered veneer restoration.

---

*The direct composite veneer is among the more minimally invasive treatment modalities available to rejuvenate and restore a patient's smile.*

---

## UNDERSTANDING THE NATURAL TOOTH

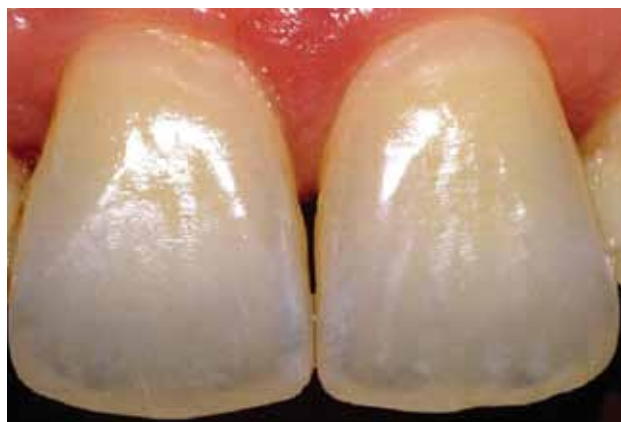It is possible to create the illusion of the different translucencies and opacities that occur in natural dentition when using direct composite resin. However, it is incumbent upon the clinician to artfully select composites that inherently mimic tooth structure and then build up or layer those composites in such a way that they interplay with light to recreate the effects of natural teeth. The landmark publication on the topic by Ubassy can be referenced by baseline clinicians and junior ceramists alike as a starting point for a more involved examination of tooth structure.<sup>2</sup>

Before composites can be selected, the clinician must understand the manner in which natural tooth structures (i.e., dentin, enamel, adjacent teeth) interact with each other to create optical effects.<sup>1,3</sup> Dentin demonstrates high points and low points to enable light to reflect and refract differently. In natural teeth, the dentin will be deeper into the tooth in those areas where the translucent enamel layer is thicker. Conversely, the dentin will be closer to the tooth's surface in those areas where the translucent enamel layer is thinner. This generally is observed at the gingival half, especially the gingival third. These anatomical and morphological concepts become more apparent with observation of tooth structure through clinical experience, especially in hands-on educational courses.

Therefore, when layering direct composite resin, it is important that clinicians ensure that the dentin area is reestablished using dentin composite, being careful to bring it closer to the surface when working near the gingival area, in order to deliver a natural-looking restoration.<sup>1,3</sup> Additionally, clinicians should avoid the use of too much translucent composite to replace what was removed during preparation. Doing so could produce a restoration that is too low in value, too translucent, and not natural-looking.

## SELECTING A COMPOSITE

An anatomically correct and esthetically pleasing restoration with realistic depth of color (Fig 1) can be achieved by logically building up carefully selected shades, tints, and opaques that incorporate differing optical properties.<sup>1</sup> When properly applied, they produce the illusion



**Figure 1:** Three-dimensional veneer restorations can be created with direct composite resin in morphologically correct and minimally invasive ways.

of different translucencies and opacities that are visible in natural tooth structure.<sup>4</sup> In particular, when producing a direct veneer restoration, it is essential to use a comprehensive restorative system that provides all the necessary shade opacities, translucencies, and dentin and enamel colors, which are the so-called “maverick colors”<sup>1</sup> (Kalore, GC America, Inc. [Alsip, IL]; Premise, Kerr [Orange, CA]; 4 Seasons, Ivoclar Vivadent [Amherst, NY]; Filtek Supreme, 3M ESPE [St. Paul, MN]).

Kalore is a microfilled resin hybrid composite that demonstrates high chameleon effects, enhanced polishability, greater flexural strength, better wear resistance, low shrinkage stress for greater restorative longevity and marginal adaptation, and high radiopacity. Aspects of these clinically significant characteristics are made possible as a result of the composite’s exclusive monomer technology licensed from DuPont. This enhances handling and sculptability. The filler technology provides exceptional gloss, easy polishability, and sustained luster.

What contributes to Kalore’s chameleon effect are the different light refractive indices of the fillers.

These have different light-scattering properties, and colors from the surrounding teeth are matched perfectly (i.e., demonstrating a chameleon effect). It is light scatter inside the composite material that provides high chameleon effects to mimic tooth structure and enable the creation of a lifelike restoration.

---

*It is incumbent upon the clinician to artfully select composites that inherently mimic tooth structure and then build up or layer those composites in such a way that they interplay with light to recreate the effects of natural teeth.*

---

This composite also includes three types of filler particles. Pre-polymerized fillers (e.g., strontium glass, 400 nm; 100 nm lanthanoid fluoride) exhibit a special surface treatment for enhanced bonding, as well as better hardness. They also contribute to the composite’s radiopacity. Nanosilica fillers (e.g., 1.6 nm fillers) are dispersed throughout the composite for enhanced wear resistance and polishability. Fillers (e.g., 700 nm strontium glass and 700 nm glass ionomer filler) are also incorporated and contribute to the

composite’s property of enhanced physical strength.

Of importance in the creation of polychromatic restorations, this next generation composite is available in a variety of opacities and translucencies. Opaque shades include AO2, AO3, and AO4, as well as OBW (Opaque Bleach White) and OXBW (Opaque Xtra Bleach White). Universal shades include A1, A2, A3, A3.5, and A4; B1, B2, and B3; C2, C3, D2, and CV=B5 (Cervical), CVD=B7 (Cervical Dark), and BW and XBW. Translucent shades include WT (White Translucent), DT (Dark Translucent), CT (Clear Translucent), NT (Natural Translucent), GT (Gray Translucent), and CVT (Cervical Translucent).

## METHODS FOR SELECTING AND PLACING DENTIN AND ENAMEL COMPOSITES

Prior to initiating treatment with direct composite veneers, clinicians should develop a very solid shade diagram that shows how the shades vary within the tooth itself.<sup>1</sup> Performing such a shade mapping can facilitate material selection and placement.<sup>1,5</sup> Essentially, shade mapping enables the dentist to draw

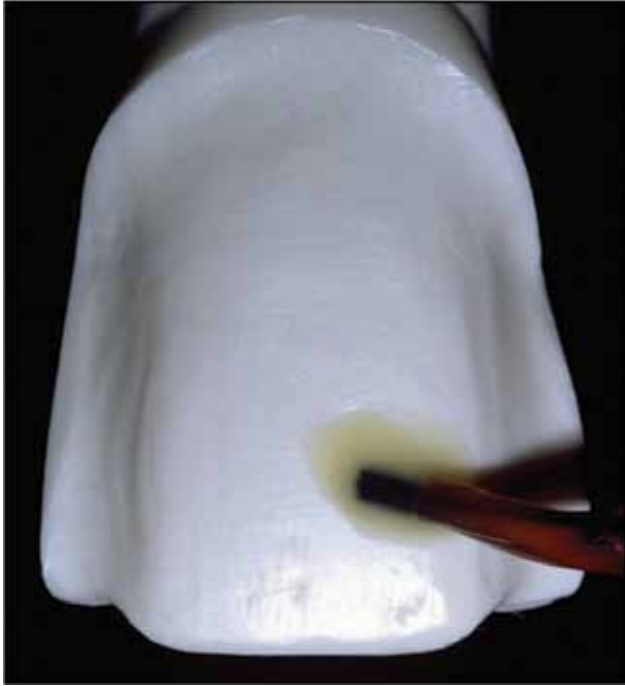


Figure 2: After conservative reduction, a single component, self-etching bonding agent (G-Bond, GC America) is applied for 10 seconds, air-thinned, and light-cured for 10 seconds.

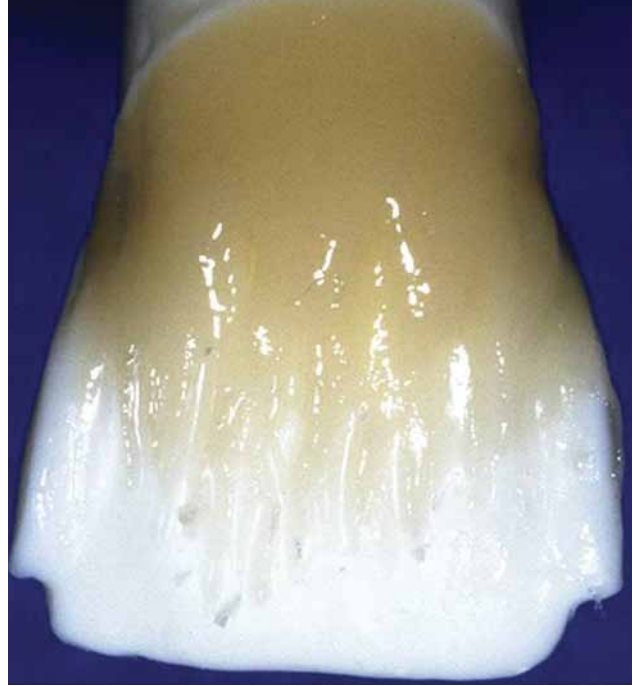


Figure 3: An initial high chroma dentin replacement layer is placed using an A3 Opaque shaded composite.

the tooth and indicate specific shade names in the zones of the tooth where they are observed. To verify the accuracy of the shade mapping, small increments of composite can be placed preoperatively—before any irreversible tooth reduction is completed—on the teeth and light-cured to enable the dentist and patient to determine if it is the right choice.<sup>1</sup>

Note that there may be a learning curve involved when using some composite systems. For example, some composites may appear very different when polymerized than when initially removed from the tube.<sup>6</sup> Additionally, a polymerized resin exhibits different esthetic qualities compared to when it is unpolymerized.<sup>7</sup> A small test increment of polymerized resin can be helpful, even after preparing the teeth, to ensure that the proper shade will be placed in a given region of the tooth.

Once the appropriate composite shades are selected, conservative tooth reduction can be accomplished. A reduction guide (i.e., polyvinyl matrix positioned against the lingual aspect of teeth) is invaluable for this task. After the preparations are appropriately pumiced, rinsed, and dried, a suitable etching and adhesive bonding protocol can be performed (Fig 2).

---

*Individuals seeking AACD Accreditation...must now incorporate a philosophy of responsible esthetics into their mindset and their dentistry when creating direct composite veneer restorations.*

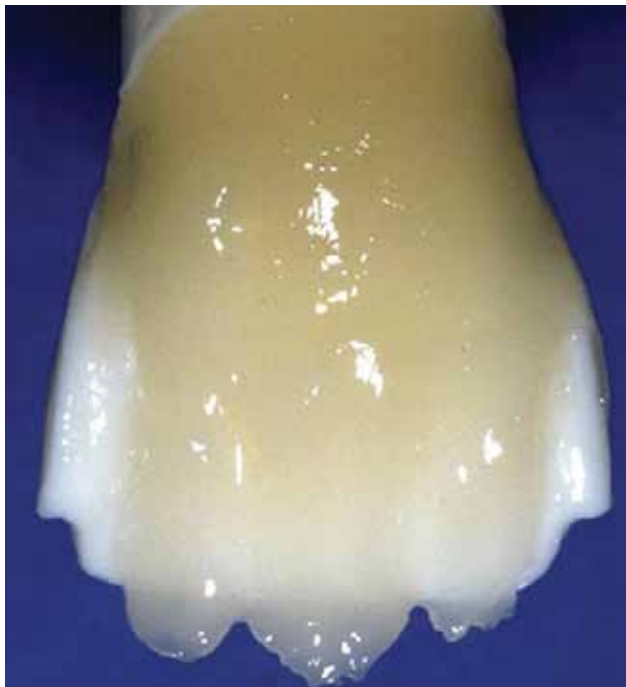---

Direct composite veneer build-up and layering techniques reflect the principles used by ceramists when making ceramic materials interact with light to imitate the hues, chromas, and values of color inher-

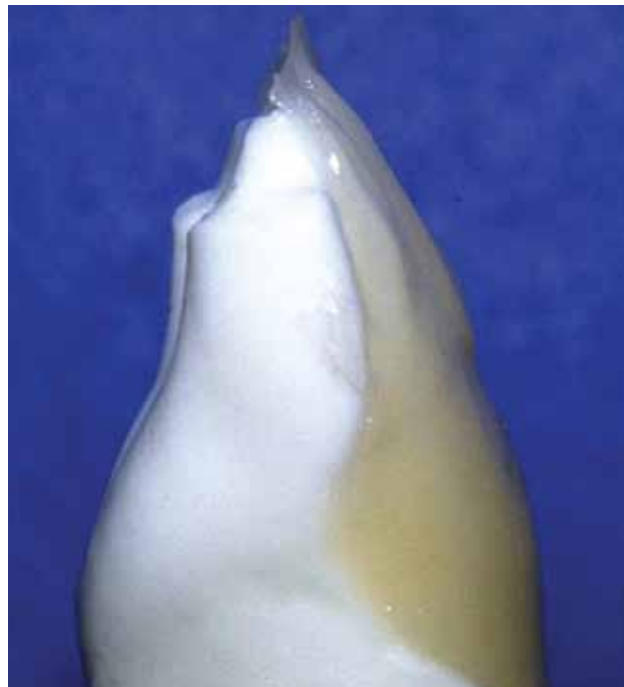ent to the tooth structure being replaced.<sup>8</sup> Building up direct composite restorations is similar to layering a ceramic restoration in how the dentin, enamel, dentin lobes, and characterization are replaced. Interestingly, mastering this endeavor also enhances the dentist's ability to communicate with the laboratory ceramist for future all-ceramic restorations.

#### DENTIN REPLACEMENT

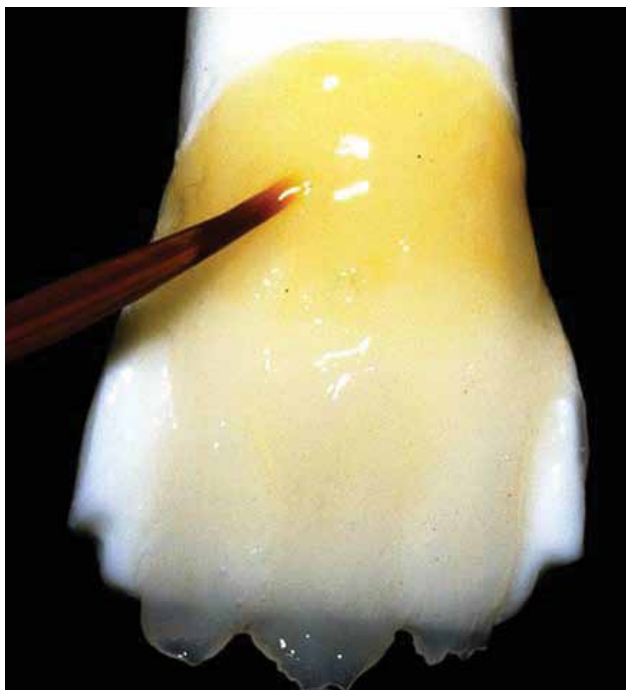
The initial dentin replacement layer should be placed using the highest chroma shaded composite for the tooth (e.g., Kalore A3 Opaque). Begin by placing the composite at the gingival third of the tooth and taper it into the middle third, almost to full contour, in order to anticipate the future thin enamel resin overlay. The composite can then be light-cured as directed by the manufacturer (e.g., 20 seconds) (Fig 3).



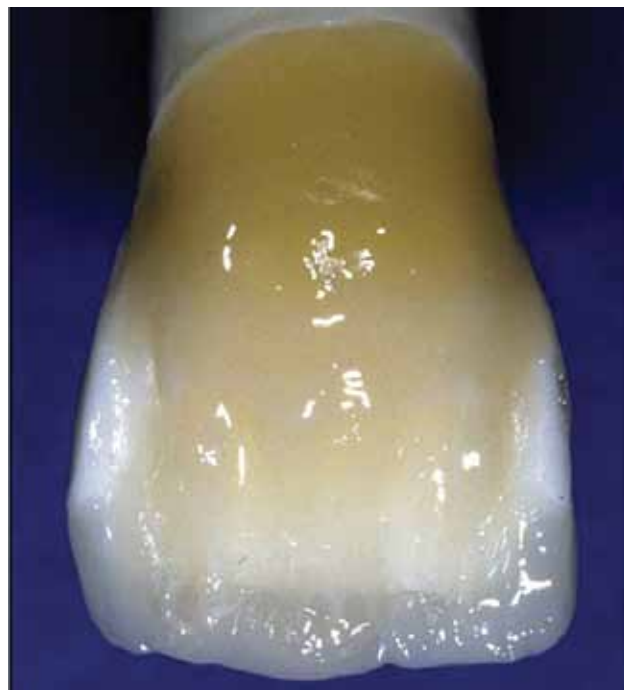*Figure 4: The second dentin replacement layer in an A1 Body shade of composite is placed in the middle third of the tooth and extended into the incisal third.*



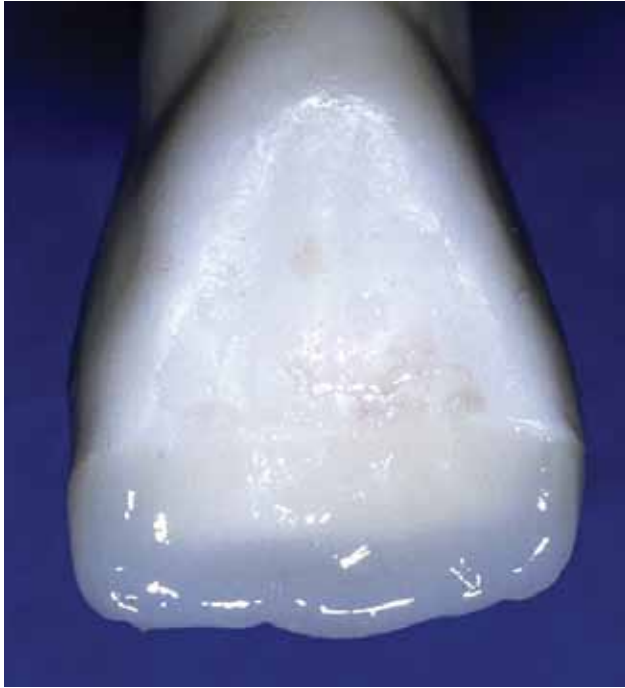*Figure 5: Labial curvature is created by sculpting concavity between the cervical and middle third of the tooth.*



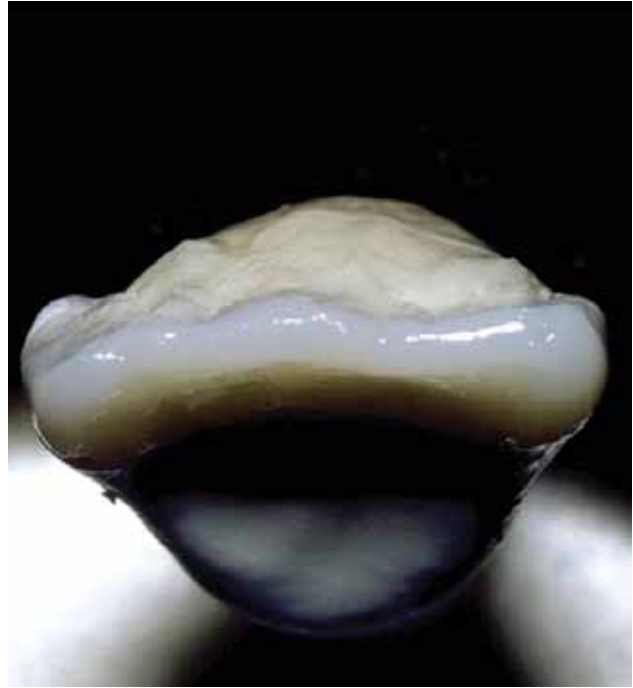*Figure 6: The chroma of the cervical third can be increased by applying a thin layer of cervical composite, or applying brown and yellow tints.*



*Figure 7: The incisal-lingual edge is replicated by applying a Natural Translucent composite, being careful to avoid mammelon overlap.*



*Figure 8: Palatal anatomy is created using the Natural Translucent composite.*



*Figure 9: The key elements of the dentin layers have been built up. Note the depth of color and enhanced trapping and scattering of light that have so far been produced.*

The second dentin replacement layer is placed using a body shade of composite (e.g., Kalore A1 Body). This composite layer is applied in the middle third of the tooth and extended into the incisal third, enabling the creation of the mammelon tips to begin. It is important to note that sufficient room should be left on the facial aspect for the application of the enamel layers. This increment is also cured (e.g., 20 seconds) (Fig 4).

At this point, clinicians can sculpt concavity between the cervical and middle third of the tooth to create labial curvature. The composite applied for this purpose can then be cured (e.g., 20 seconds) (Fig 5).

If it is necessary to increase the chroma in the cervical third (e.g., to A4), a thin layer of Cervical Composite (e.g., Kalore CV) can be applied, sculpted, and cured for 20

seconds. Alternatively, brown and yellow tints also can be applied to the cervical area and cured (Fig 6). In either case, room should be left for the final enamel layer.

### CREATING INCISAL/LINGUAL/ PALATAL ANATOMY

To recreate the remaining lingual contour and incisal edge of the veneer restoration, a layer of composite Natural Translucent (e.g., Kalore NT) composite is applied, being careful to avoid mammelon overlap. Room should be left for final enamel layer placement, and anatomical correctness should be verified. This composite layer is then cured (e.g., 20 seconds) (Fig 7).

Similarly, to create palatal anatomy, the same Natural Translucent (e.g., Kalore NT) composite is applied, after which the anatomical correctness is verified. After ensur-

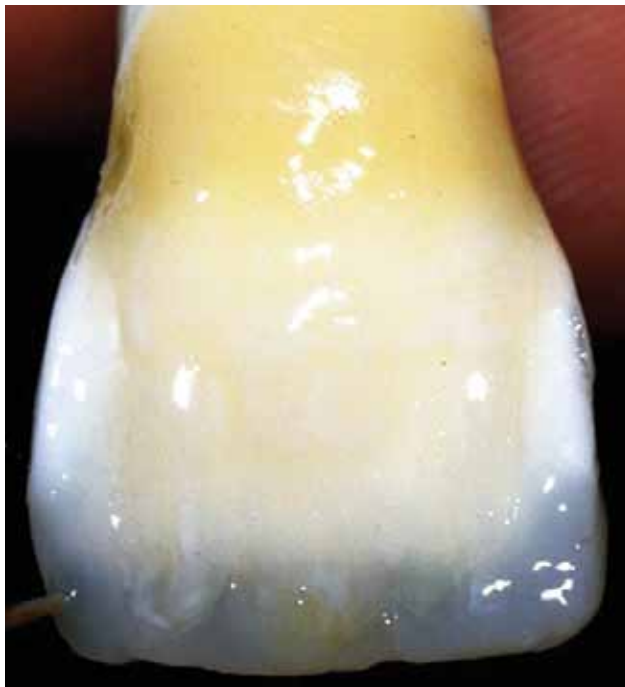ing room has been left for the final enamel layer, the palatal composite can be cured (e.g., 20 seconds) (Fig 8).

At this point, the dentin anatomy of the restoration has been built up, resulting in an undulating effect that produces depth of color and enhances the trapping and scattering of light (Fig 9).

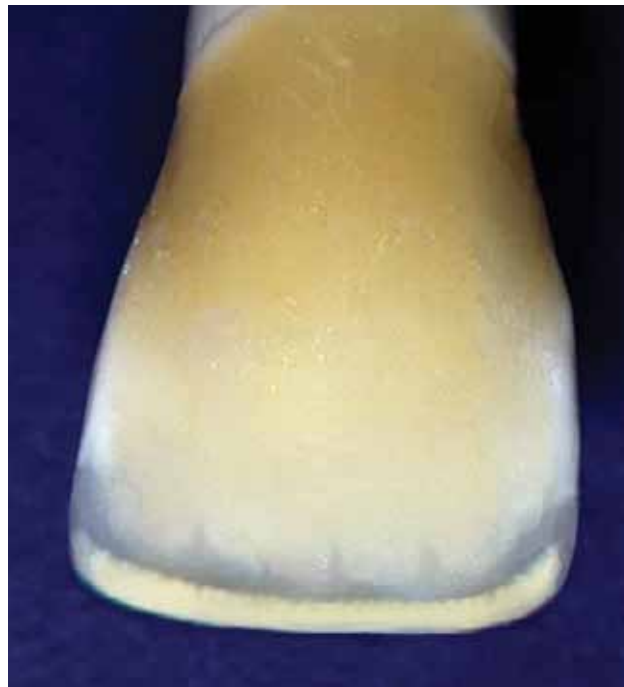### REPLACING INCISAL TRANSLUCENCY AND EFFECTS

To create incisal edge translucency and impart incisal effects, the clinician can choose from two different techniques. One uses composites that are inherently colored or tinted (e.g., Kalore Gray Translucent [GT]), while the other necessitates the use of tints.

If the incisal third requires a reduction in value, apply a Gray Translucent Composite (e.g., Kalore



*Figure 10: To replicate incisal translucency and reduce the value of the incisal third, apply Gray Translucent composite to the incisal third.*



*Figure 11: A halo effect can be created by applying Bleach White or Xtra Bleach White composite to the incisal edge of the tooth.*

GT) to the incisal third, being sure to avoid mammelon overlap and leaving sufficient room for the final enamel layer. Light-cure the composite (e.g., 20 seconds) (Fig 10). Alternatively, apply Blue and Clear tints and light-cure.

To create an incisal halo effect of 1.0 mm to 1.5 mm, as depicted in Figure 1, apply Bleach White (e.g., Kalore BW) or Xtra Bleach White (e.g., Kalore XBW) composite, sculpt into place, and light-cure (e.g., 20 seconds) (Fig 11). Note that usually the incisal halo in natural tooth structure is not this thick. Often, a .5-mm halo is more prevalent. Then, apply Opaque Bleach White (e.g., Kalore OBW) composite to simulate diffuse hypocalcifications and fluorosis on the mammelon tips and sculpt into place. Alternatively, apply Crack Liner and Clear Tint and

cure. In either case, ensure that sufficient room is left for the application of the final enamel layer.

#### **FINAL ENAMEL PLACEMENT**

After the appropriate incisal effects have been created, the restorations can be completed by replacing the enamel layer. The final enamel shade of composite will provide a translucent effect and properly disperse light. Clinicians can apply Cervical Translucent (e.g., Kalore CVT) to the cervical third, White Translucent (e.g., Kalore WT) to the middle third, and Clear Translucent (e.g., Kalore CT) to the incisal third, then light-cure (e.g., 20 seconds) (Fig 12). The final enamel layer must be slightly overbuilt prior to finishing (Fig 13).

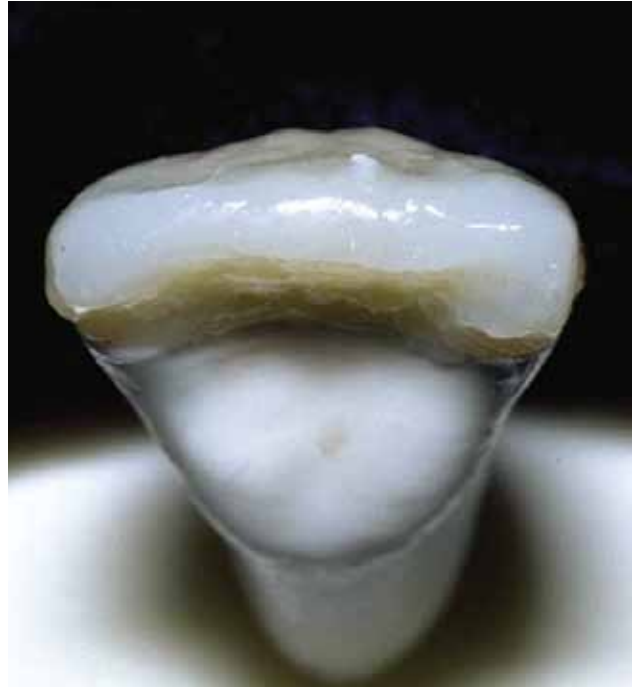#### **IMPARTING AXIAL CONTOURS, REFINING ANATOMY, AND FINISHING**

After the direct composite veneer restoration has been successfully layered and anatomically constructed, clinicians should ensure that they have achieved a similar harmony and balanced width and length with the adjacent dentition. Additionally, after the overall gross contours of the veneer have been confirmed, it is then time to impart texture and fine-tune the tertiary anatomy (Fig 14).

At this time, line angles should become more well-defined. Faint lines can be scribed on the composite to outline transition line angles. Texture then can be carried to and beyond the line angles to replicate nature. In particular, draw a line between the cervical and middle third. Draw another line between the mid-



*Figure 12: Different enamel composites (Cervical, White, and Clear Translucent) are applied as the final enamel composite layer and cured.*



*Figure 13: The final enamel layer of composite must be slightly overbuilt prior to finishing.*

dle and incisal third (Fig 15) to outline the axial contours. To outline the secondary anatomy, mark the proximal line angles, long bisecting angle, and developmental grooves (Fig 16). These scribed anatomical landmarks can also be seen in an incisal view.

Integrated products and materials, beginning with coarse anatomy trimmers and progressing to intermediary diamond polishers, then advancing to more refined polishers, should be used in a sequential manner as part of the finishing and polishing protocol. A goat hair brush with .5- $\mu$  diamond polishing paste; and high shine points, cups, and wheels (Jiffy, Ultradent Products; South Jordan, UT; or Groovy and Shape and Shine, Clinician's Choice; New Milford, CT) could be used for this sequence. The tertiary

anatomy then can be created using a fine flame-shaped diamond bur (Brasseler USA; Savannah, GA) to add surface texture in the cervical third, as well as between the proximal and bisecting line angles (Fig 17). To achieve the appropriate luster and polish, a good polishing system that includes polishing paste, points, cups, and wheels is recommended for esthetic direct composite restorations.<sup>1</sup>

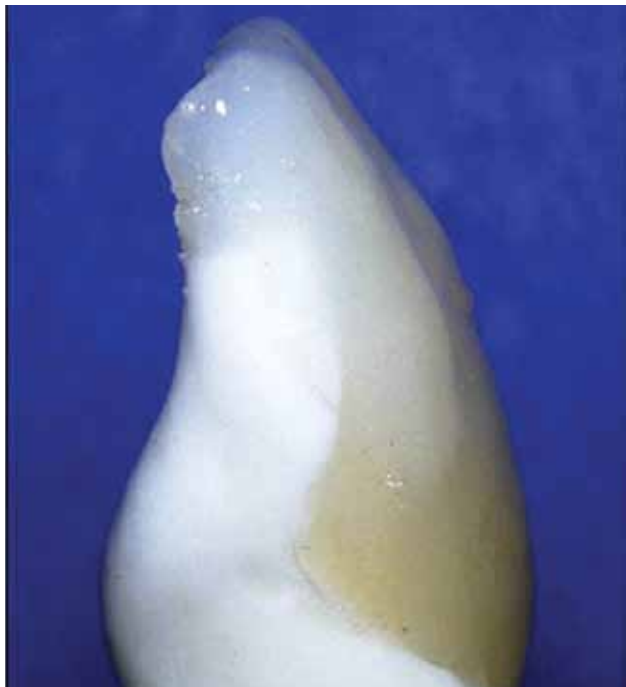## CONCLUSION

Compounding the challenges faced by clinicians in the pursuit of creating lifelike direct composite veneers, is delivering such restorations in as minimally invasive and esthetically responsible ways as possible. Today's esthetic dentists must consider the patient's needs alongside

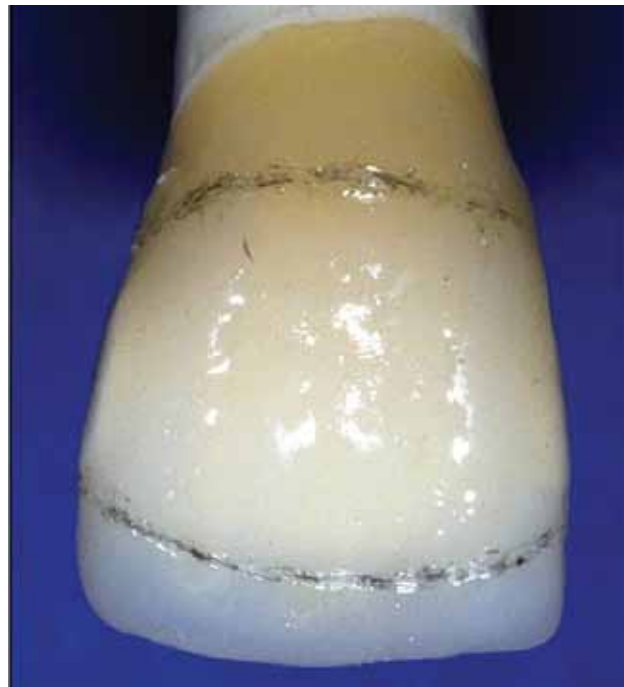the best evidence-based treatment alternatives and restorative modalities. Thankfully, manufacturers have increasingly provided dentistry with restorative materials that not only mimic nature esthetically, but also in terms of durability. Further, the handling and physical properties of such materials—combined with clear treatment planning—can enable clinicians to place direct composite veneers in a conservative and naturally esthetic manner (Fig 18) as replicated from the prerestorative photo (Fig 1). In this author's opinion, observation of tooth structure is invaluable as a tool to precede the layering of the composite materials. This creates consistency and predictability in the esthetic outcomes.

This will be beneficial for individuals seeking AACD Accreditation, who must now incorporate a

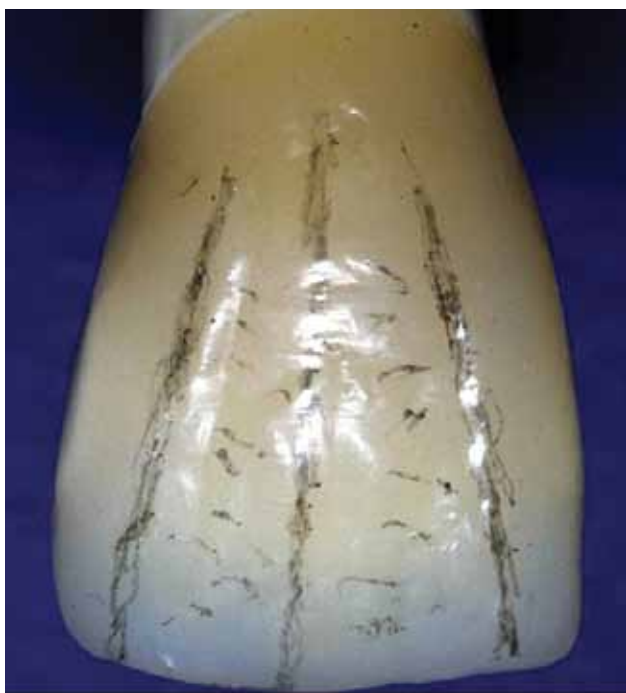



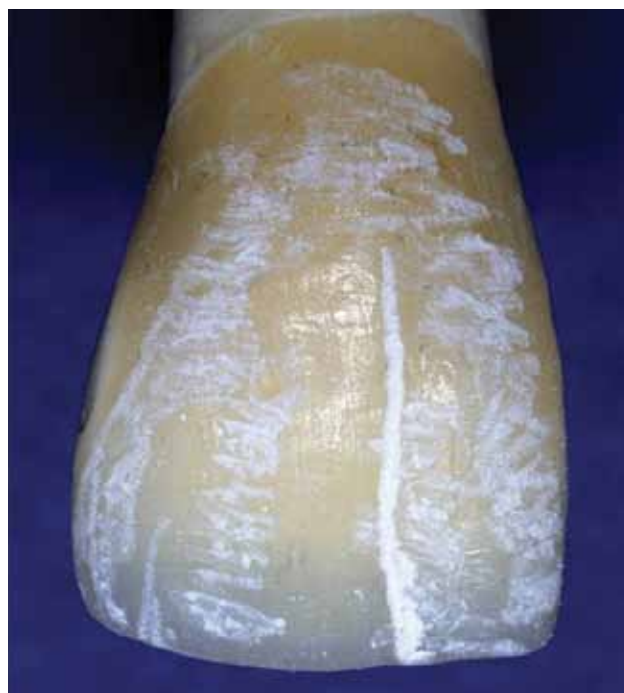*Figure 14: The axial planes of curvature of the direct composite veneer include incisal, cervical, and middle planes.*



*Figure 15: Axial contours are outlined by drawing a line between the cervical and middle third, as well as a line between the middle and incisal third.*



*Figure 16: To outline secondary anatomy, mark proximal line angles, long bisecting line angles, and developmental grooves.*



*Figure 17: To create tertiary anatomy, a diamond bur is used to create surface texture.*



*Figure 18: The final esthetic dimensions of the restoration should be evaluated in terms of color, opacity, fluorescence, and opalescence, as in Figure 1.*

philosophy of responsible esthetics into their mindset and their dentistry when creating direct composite veneer restorations. To that end, this article has described the benefits of using a composite system with different opacities and translucencies, as well as a predictable method for creating layered direct composite veneers. Additionally, ways to impart ceramist-like surface texture to composite veneer restorations were addressed.

#### **AACD Acknowledgment**

*The American Academy of Cosmetic Dentistry recognizes Dr. Frank J. Milnar as an AACD Accredited Member (AAACD) and Accreditation Examiner.*

#### **References**

1. LeSage B, Milnar F, Wohlberg J. Achieving the epitome of composite art: creating natural tooth esthetics, texture, and anatomy using appropriate preparation and layering techniques. *JCD*. 2008;132-41 (special issue).
2. Ubassy G. *Analysis: the new way in dental communication*. Carcina, Italy: Teamwork Media Villa; 2000.
3. Terry DA, Geller W, Tric O, Anderson MJ, Tourville M, Kabashigawa A. Anatomical form defines color: function, form, and aesthetics. *Pract Proced Aesthet Dent*. 2002;14:59-67.
4. Blank JT. Simplified techniques for the placement of stratified polychromatic anterior and posterior direct composite restorations. *Compend Contin Educ Dent*. 2003;24 (2 Suppl):19-25.
5. Terry DA, Leinfelder KF. An integration of composite resin with natural tooth structure: the Class IV restoration. *Pract Proced Aesthet Dent*. 2004;16(3):235-42.
6. Lee YK, Powers JM. Color and optical properties of resin-based composites for bleached teeth after polymerization and accelerated aging. *Am J Dent*. 2001;14:349-354.
7. Yu B, Lee YK. Differences in color, translucency and fluorescence between flowable and universal resin composites. *J Dent*. 2008;36:840-46. Epub 2008 Jul 14.
8. Jackson RD. Understanding the characteristics of naturally shaded composite resins. *Pract Proced Aesthet Dent*. 2003;15(8):577-85.



# Large Close More Cases

Payment plans up to \$40,000

Rates as low as 5.99% APR\*

Terms from 3 to 84 months

Let's talk.



*designed for high end dentistry*

**Call 800-630-1663**

**Visit [springstoneplan.com](http://springstoneplan.com)**

\* Rates subject to change. Terms available based on amount financed and credit history. Please visit [springstoneplan.com](http://springstoneplan.com) for current rates.

## TEACHING DENTAL ASSISTANTS TO SPEAK YOUR LANGUAGE



by Shannon Pace Brinker, CDA, CDD  
Virginia Beach, VA  
[www.thedawsonacademy.com](http://www.thedawsonacademy.com)

*Editor's note: This article is based on a Heraeus-sponsored hands-on workshop at the 25th Anniversary AACD Scientific Session in Honolulu, Hawaii.*

### INTRODUCTION

Today's cosmetic dental practices are challenged to provide comprehensive treatments to esthetically demanding patients in ways that cater to their functional and emotional needs. Although many dentists have come a long way in enhancing their chairside manner—as well as how they empower their staff (e.g., dental assistants), it might still be fair to say that when it comes to communication, dentists still speak a “different language.”

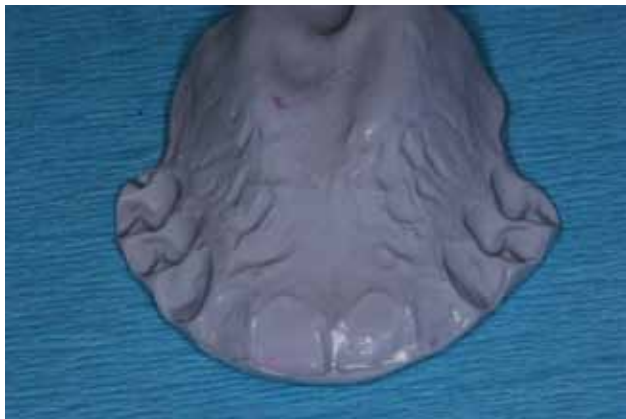Savvy cosmetic dentists can capitalize on the inherent interpersonal and communication skills of their dental assistants. By helping to expand their dental assistants' knowledge and proficiency in different technical aspects of restorative practice, dentists can empower them to accept greater responsibility for communicating detailed case information to patients and laboratory technicians.

---

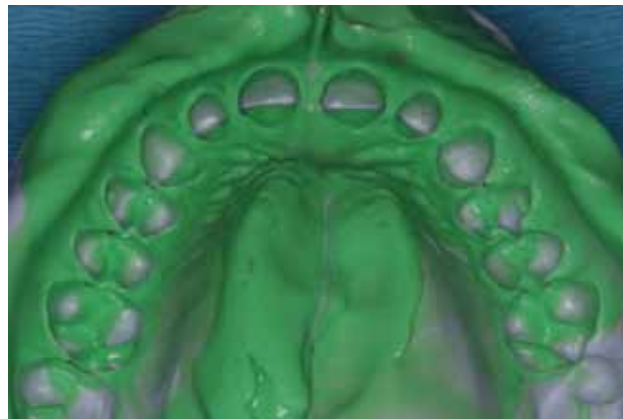
*Savvy cosmetic dentists can capitalize on the inherent interpersonal and communication skills of their dental assistants.*

---

Cosmetic dental practitioners can use the training concepts from a lecture at the 25th Anniversary AACD Scientific Session to help their dental assisting staff better understand records appointment procedures, smile design principles, and mock-up and provisionalization techniques. In particular, when dental assistants understand and are trained in the use of mounted diagnostic models for visualizing the necessary functional



*Figure 1: The task of creating an accurate and quality preparation reduction guide can be delegated to the dental assistant.*



*Figure 2: Dental assistants should be instructed that quality diagnostic impressions include details well beyond the free gingival margins of the teeth, the entire buccal and lingual vestibules, and the hard palate.*

and esthetic changes through smile design, as well as how to create a diagnostic mock-up based on the Golden Proportions and proper ratios, they will be well-equipped to support the dentist in the creation of preparation reduction guides (Fig 1) and provisional matrixes.

This article outlines how cosmetic dentists can involve their dental assistants in the planning procedures required to provide comprehensive cosmetic dental treatment; enhance their understanding of the technologies and materials necessary to ensure predictable results; and broaden their familiarity with smile design principles. Such knowledge will enable the dental assistant to support the restorative team with the diagnostic and procedural skills necessary to help satisfy patient expectations.

### EXPLAINING HOW TO OBTAIN THE NECESSARY RECORDS

Dental assistants can play a significant role during the records appointment by taking quality diagnostic impressions, pouring casts, mounting models on the articulator, and obtaining facebow and other records.

### TAKING QUALITY DIAGNOSTIC IMPRESSIONS

Caution your dental assistant that diagnostic impressions should be handled with the same attention to detail as impressions taken for a final crown or bridge. The dental assistant should understand the level of scrutiny with which diagnostic impressions will be examined, as they will be used for diagnosis, treatment planning, diagnostic waxing, and eventual provisional fabrication.

Emphasize the need to obtain extremely accurate impressions. Dentists might consider recommending the use of an alginate replacement polyvinyl siloxane impression material with a light-body wash (e.g., Flextime Putty, Heraeus; South Bend, IN) (Fig 2). Explain that this material category will enable multiple pours, if necessary, and eliminate the need to pour the model immediately.

Additionally, dentists can provide specific instructions about this procedure, including the need to dry the teeth prior to placing the impression material to ensure that all of the surfaces of the teeth are captured. Explain that a quality

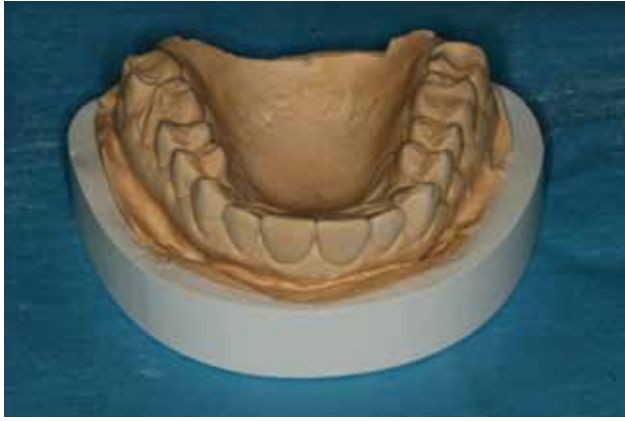impression includes the details well beyond the free gingival margins of the teeth, the entire buccal and lingual vestibules, and the entire hard palate.

### CREATING QUALITY CASTS

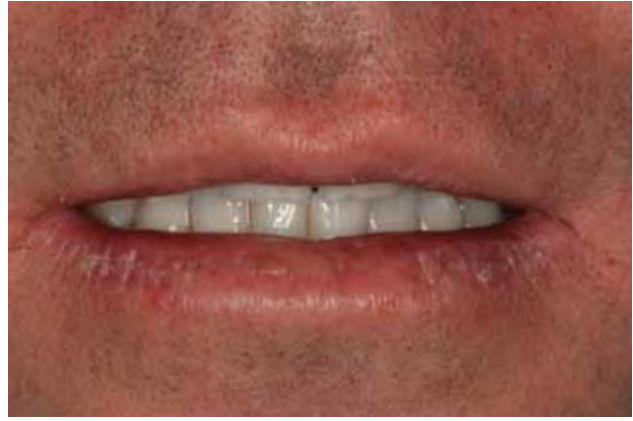Be sure that your dental assistants understand the need to follow the water-powder ratio for the specific stone being used (e.g., Fujirock, GC America, Inc.; Alsip, IL) when pouring casts (Fig 3). The use of a vacuum-mixing machine also is recommended to eliminate air in the mix. Explain that this results in bubble-free, dense casts for maximum accuracy.

### WORKING WITH ARTICULATORS

Although the use of articulators may be part of everyday routines in the cosmetic practice, that does not mean that dental assistants understand why. To fully involve them in the process, cosmetic dentists can educate their assistants about the purpose and function of articulators, as well as emphasize why a quality articulation system is worth its weight in gold to the cosmetic restorative practice. Demonstrate why such features as an ability to accept a facebow transfer and con-



*Figure 3: Image of an accurate, bubble-free and dense stone cast that dental assistants should strive to obtain.*



*Figure 4: Dentists should explain to their assistants that while the rest position is important for smile design, it reveals little about incisal edge position, or its effects.*

dyle guidance that can be altered when necessary are most important to cosmetic dentists. To facilitate the staff's ability to use the instrument, dentists might consider selecting an articulator that their laboratory uses, that their staff can be taught to use on a daily basis, and that feels right in their hands. One of the simplest articulators available was designed by Dr. Peter Dawson (Combi 2 Articulator, Whip Mix Corp.; Louisville, KY).

#### **USING A CORRECTED FACEBOW TRANSFER**

Similarly, the importance of ensuring accuracy when obtaining a facebow transfer may not be fully understood by dental assistants until the rationale for its use is explained. Therefore, cosmetic dentists can ensure their dental assistants' understanding of why facebow transfers are needed by explaining that their purpose is to enable the maxillary cast to be mounted on the articulator in the exact same orientation to the skull that the maxilla is when the patient is standing up straight. Dentists should also explain that the distance from the maxillary inci-

sal edge to the axis of rotation of the mandible should also be duplicated when the facebow is mounted in the articulator.

However, simply understanding the purpose of these tools does not guarantee successful outcomes. Therefore, dentists can help ensure that their dental assistants will be successful by providing instruments that enhance the predictability of the facebow process. For example, a simple earbow type of facebow (Slide-o-matic, Whip Mix Corp.) can be used in combination with a rigid bite registration material (Venus Bite, Heraeus) to mount the maxillary cast. Additionally, dental assistants can be made aware that some patients' ears are not level, which can lead to the incorporation of a cant to the maxillary incisal plane. As a result, dentists may recommend that they use a bubble level (Great Lakes Orthodontics; Tonowanda, NY) to ensure that the facebow is level with the floor when the patient is standing upright.

#### **RECORDING CENTRIC RELATION**

Although there are several methods for recording centric

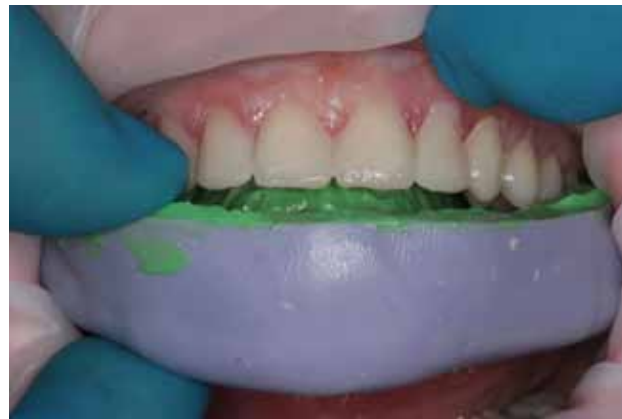relation (CR), dentists may want to instruct their dental assistants in their preferred method for finding, verifying, and recording CR. One such method is bimanual manipulation, as described by Dawson.<sup>1</sup> Taking the time to teach dental assistants this technique will add predictability to the diagnosis and treatment of occlusally driven restorative treatment. Therefore, consider teaching dental assistants how to position the patient, properly position the hands, and employ the proper pressure when using this technique to record CR.

#### **MOUNTING THE MODELS**

The independent procedures previously described—taking accurate impressions and making quality cases, working with articulators and using a corrected facebow transfer, and recording CR—make even more sense when the cumulative results of their use are brought into unified context for the dental assistant. Therefore, cosmetic dentists can explain the significance of mounting the models to their dental assistants, as well as how to use all of these collected



*Figure 5: The nuances of lip support and lip closure path can be explained to dental assistants, so they understand the impact that incisal porcelain thickness can have on smile esthetics.*



*Figure 6: The task of making putty matrixes after the creation of an intraoral mock-up can be delegated to the dental assistant.*

“information tools” during the diagnosis and treatment-planning process.

Additionally, dental assistants should be instructed in how to mount the models to ensure that the precise maxillo-mandibular relationship is recorded clinically. Such training can begin with a demonstration of how contemporary facebow systems enable the mounting jig to be separated from the ear-bow—which allows easy mounting of the maxillary cast on the articulator—so that the corrected facebow technique previously described can be employed to position the maxillary cast on the instrument. Then, dentists can provide instruction in how to stabilize the maxillary cast using a rubber band and mount it with mounting stone.

Finally, the importance of CR can be translated for dental assistants by relating the mandibular cast to the maxillary cast and stabilizing it using a hot glue gun with four nails. Dentists can further instruct their assistants to mix and place stone between the cast and the mounting plate, without fear of inadvertently rocking the lower model.

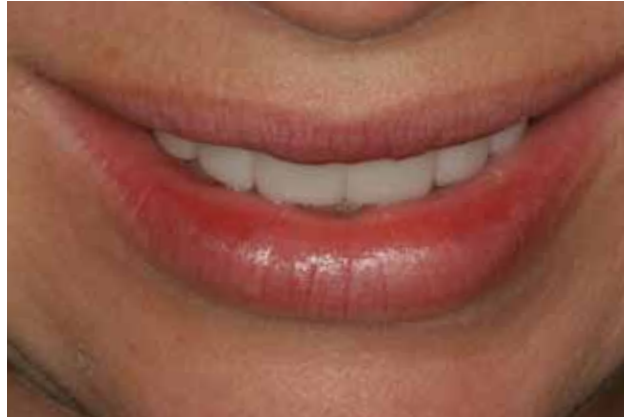#### TEACHING THE PRINCIPLES OF SMILE DESIGN

The dental assistant’s education in cosmetic restorative procedures now can segue into the important decision-making process regarding optimum esthetics and function. This can begin by addressing the precise position of the maxillary incisors. They should learn why finding the correct incisal edge position from a vertical and horizontal perspective ensures not only beautiful restorations, but also functional harmony.

For example, cosmetic dentists can explain that the “rest position” (Fig 4) and “E” sound are excellent and important considerations for designing a smile, but that they do little to indicate whether the incisal edge is too far forward (i.e., infringing on the patient’s lip) or too far to the lingual (i.e., interfering with the patient’s occlusion). When dental assistants understand the parameters that can affect the envelope of function, they will be better able to support cosmetic dentists in providing functional and esthetic elective procedures.

Then, dental assistants also can be instructed to work with patients in identifying potential problems with lip support and lip closure path which, as described by Dawson, allows the lower lip to comfortably close around the incisal third of the maxillary incisors.<sup>2</sup> For example, if dental assistants know that the maxillary teeth should be far enough forward to provide proper lip support—as well as have the proper two-plane contour to allow proper closure of the lips—they will be able to help dentists work with their patients to assess whether the provisional and/or final restorations feel and function as expected (Fig 5). Therefore, dentists may want to advise their assistants that telltale signs and complaints from patients with lip closure path problems include the following:

- teeth that feel too long (so they should always check the horizontal position of the maxillary incisal edge)
- anterior teeth that feel dry (so they should ask patients if they feel they cannot close their mouth easily, which could cause dry facial surfaces of the maxillary incisors)



*Figure 7: With practice, dental assistants can fabricate full-arch provisional restorations to the dentist's specifications, such as those seen here, with a purposely thick incisal edge for proper contouring.*

- tired facial muscles; and difficulty saying "F" or "V" sounds, which—during the provisional stage—may suggest an incorrect horizontal and vertical incisal position.

#### **DELEGATING MOCK-UP AND PROVISIONAL FABRICATION**

Dentists also can instruct and empower their dental assistants to perform intraoral diagnostic mock-ups using either diagnostic wax (Whip Mix Corp.) or composite (Venus, Heraeus), depending on what works best in their hands. Then, they can lend further support to the cosmetic restorative team by making putty matrixes and taking impressions (Flexitime Putty/light body wash) for their later use in fabricating provisional restorations (Fig 6).

However, before undertaking this task, dental assistants should understand that today's provisional restorations are no longer regarded as just temporaries. Rather, they should know that they serve specific functions and purposes (e.g.,

working out the correct vertical and horizontal incisal edge position) (Fig 7). Dental assistants therefore should be instructed to consider anterior guidance that is in harmony with the envelope of function so that they can ensure that the lingual contours are sufficiently steep to disclude the posterior teeth, but still in harmony with the envelope of function. They should be reminded that the provisional restorations—and the impressions of them—are often the only way to predictably communicate this information to the dental laboratory, so this information must be accurate.

#### **CONCLUSION**

Today's dental assistants are more than just chairside assistants. When educated and trained in different technical aspects of restorative practice, dental assistants become partners to the dentist and laboratory technician, as well as better communicators and advocates on behalf of the dental patient. From

providing invaluable support during the records appointment to facilitating treatment planning using an esthetic mock-up, the dental assistant of today enjoys expanded duties and the satisfaction that comes from fulfilling greater expectations. By empowering their assistants with knowledge of mounted diagnostic models, smile design principles, preparation reduction guides and provisional matrixes, and the technologies and materials necessary to ensure predictable results, cosmetic dentists can ensure they stay well supported in their endeavors.

#### **References**

1. Dawson P. Functional occlusion: from TMJ to smile design. St. Louis (MO): Mosby; 2007.
2. TheDawsonAcademy.com [Internet]. St. Petersburg (FL): The Dawson Academy.© 2009. Available from [www.TheDawsonAcademy.com](http://www.TheDawsonAcademy.com).







# IT ALL STARTS WITH Artistry

Dentistry by Dr. Chris Hammond. Ceramics by Utah Valley Dental Lab Artisans.

**“e.max LITHIUM DISILICATE IS THE MOST ROBUST CERAMIC SYSTEM TESTED TO DATE.”\***

– visit [emaxchangeeverything.com](http://emaxchangeeverything.com) for study results

**IPS e.max<sup>®</sup>**  
all ceramic all you need  
[emaxchangeeverything.com](http://emaxchangeeverything.com)



It's time to expect more from your lab.

At Utah Valley Dental Lab, we know your patients have high expectations. For nearly half a century, the artisans at UVDL have focused on building VALUE for their clients by building strong personal relationships and solving problems TOGETHER with our dentists. Helping change lives through dentistry is what we do!

UVDL is proud to offer IPS e.max... through the years, we've fabricated THOUSANDS of lithium disilicate restorations and have found them to be the most durable, fracture-resistant restorations we've ever made. Its versatility for inlays, crowns, veneers and three-unit anterior bridges makes it our material of choice for outstanding esthetics and durability.

IPS e.max offers:

- “Monolithic” composition – provides higher resistance to chipping or fracturing as compared to “two-part” (veneered) restorations
- Outstanding esthetics
- Conventionally cemented or bonded
- “Model-less” lab fabrication through Cerec®-Connect

\*Mouth Motion Fatigue and Durability Study  
Pavia C. Giansi, Ricardo Zaveroni, Nelson Saba and Vani P. Bionquist, NYU

 **UTAH VALLEY DENTAL LAB**

36 South 300 East | Provo, UT 84606  
**800.927.6967**  
[uvdl@uvdl.com](mailto:uvdl@uvdl.com)

## SPEAKING SKILLS FOR AACD PRESENTERS



by Sandra R. Roth  
Speaker and Presentation Coach  
Co-Chair Professional Education  
Committee 2009-2010  
Brooksville, FL  
[www.prosynergy.com](http://www.prosynergy.com)

*Editor's note: This article is based on a lecture offered at the 25th Anniversary Scientific Session in Honolulu, Hawaii.*

Each year, the AACD's annual scientific session provides a plethora of programming to provide our members the best education in dentistry. Much of this programming is offered in lecture format supported by an amazing array of hands-on workshops sponsored by our corporate supporters. The Professional Education Committee (PEC) works hard to create a balanced program that meets the needs of all our members, whether they are attending for the very first time or have not missed a meeting in 25 years. Our presenters often are full-time practitioners who have committed themselves to educating others over and above their practice responsibilities. Over the years, more of our members have aspired to the platform as their insights, abilities, and desire to teach have developed. To that end, the PEC has committed a portion of the annual AACD scientific session to providing members speaker training, and I was honored to offer the program at our 25th Anniversary AACD Scientific Session in Honolulu in 2009. While it is not possible to replicate a training session in our Journal, I can give an overview of the program and encourage you to attend Dr. Gary Genard's full-day speaker training program in Texas at our 26th Annual AACD Scientific Session next April. In addition, Dr. Genard will offer a half-day program for accomplished speakers on what *not* to do with PowerPoint. We welcome your participation in these programs in Texas.

In the meantime, here are some important aspects of putting together a program that will help everyone who aspires to the speaking platform.

## HOW TO ASSEMBLE YOUR PRESENTATION

Many dentists begin their presentations by launching PowerPoint™. This is a mistake and can cause the presentation to become mired in too much detail very quickly. The proper place to begin is with the “big picture.” Here are the three questions to ask yourself to get started:

1. What *specifically* is my topic?
2. Who *specifically* is my target audience?
3. What *specifically* is my take-home message?

Consider how important these three questions are to framing your ideas and getting you focused on what will make your presentation effective. You will, of course, create a very different program when you force yourself to select a narrower topic than when you opt to provide a survey or broadly defined topic. Most novice presenters err in trying to cover too much ground. By spending significant time honing and sharpening your topic, you can avoid this mistake. Consider the following options:

- composite restorations in the esthetic practice
- direct restorations in the esthetic practice
- conservative direct restorations in the esthetic practice
- adhesion and conservative direct restorations in the esthetic practice
- adhesion and conservative anterior direct restorations in the esthetic practice
- fundamentals of adhesion and conservative anterior direct restorations in the esthetic practice.

As the topic narrows, the student becomes clearer about what will be

offered and whether the program is appropriate for his or her learning objectives. In many cases, the topic statement can be substituted for the title or sub-title of the program. When you reach this point, you have likely narrowed your topic sufficiently.

The second narrowing challenge is to identify your target audience. Clearly, AACD Accredited Fellows are a different demographic than first-time attendees or dental hygienists. It is important to envision your target audience so you can create a program that serves their specific interests, needs, and educational objectives.

Finally, identifying the take-home message is a significant challenge. Having done so, however, you will be able to drive all of your content toward that one goal. Another mistake often made by the novice speaker is drifting off topic, following tangents that fail to contribute to the ultimate purpose of the presentation, or engaging in self-indulgent mental diversions.

### CHOOSE THREE OR FOUR KEY POINTS

Your key points must add up to your take-home message, so you must test each one by this criterion. As a dentist, this logical progression should be relatively easy since most dentists are linear thinkers. In choosing your points, you must attend to the following issues:

1. Select the strongest points to be made.
2. Make sure the points add up to the take-home message.
3. Keep the points simple, clean, and clear.

The best speakers are able to resist choosing too many points for their presentation. “The 75 things you must do to become a great lead-

er” gives students a sense that they will be overwhelmed, and this approach rarely results in any significant learning. The best speakers are able to focus their presentation on vital points rather than reverting to a “shotgun” approach that rains a buckshot-load of ideas around the room. Restricting yourself to key points takes discipline, and this step may take more time than any other in the process. It will, however, be time well spent, and you will definitely reap rewards down the line.

### WRITE YOUR OPENING

The quality and content of your opening will set the stage for the balance of your presentation. Consider the following two openings:

*“Good morning everyone, I am especially glad to be here considering how I almost missed my connection in Atlanta. I’d like to thank the committee for inviting me and I’m hoping to have a good day today. We have a lot of material to cover and I usually have a full day for this presentation so we’ll have to go rather quickly in order to get everything into the three hours I’ve been allotted. We won’t be taking a break and there probably won’t be time for any questions but we’ll do our best. I’d like to begin by showing you some pictures of my practice and family.”*

Versus

*“Many dentists are faced with the challenge of creating treatment plans for patients who have already expressed a concern with finances. How can you meet your clinical standards yet work within the economic restraints imposed by the patient? Today we will hit this question straight on by outlining the clinical standards you must address in your examination, diagnostics, and treatment planning, as well as the way you can discuss options with patients without disregarding their unique circumstances.”*

ROTH

Which presentation would you opt to sit through? Case closed. The opening must adhere to the following guidelines:

1. It should be strong, to capture the audience's attention from the beginning. Consider using a story, quote, or rhetorical question.
2. It must be relevant to the topic, target audience, and take-home message. Ice-breakers are for Moose Lodge meetings, not professional presentations, so avoid lame jokes or bland and pointless beginnings.
3. Get to it immediately. You can thank the meeting organizers and attendees at the end. Limping into your presentation begins to lull people into a dreamlike state that detracts from the "meat" to follow.

#### WRITE YOUR CLOSING

I'm taking you to the closing before you put together your presentation's body because you have to know where you intend to end up. Your closing is a recap, summary,

and final stroke of the pen. Consider the following two closings:

*"Gosh, the time has flown. We won't be able to hit the last three points other than to say they are 'create a Web site,' 'make sure your logo is strong,' and 'train your staff in internal marketing.' It has been a pleasure to speak with you all today and I hope you got a lot out of the program. Thank you."*

Versus

*"Today we have looked at the three factors that ensure proper implant placement by the oral surgeon. Working with a specialist requires the general dentist to be clear in his or her thinking, precise in his or her analysis, and exceptionally clear in conveying his or her expectations. By following the guidelines we have set in place today, you can more easily avoid the type of mistake we saw with Mrs. X, the malpractice claim brought by Mr. Y, and the heartbreak experienced by Miss Z. I am happy to stay and respond to your further questions. Thank you so very much for joining me today and I look forward to hearing how successful your cases are from here on."*

Giving the students a recap of your presentation—in simple terms—and sending them off to greatness is supportive, encouraging, and exactly what a good educational experience requires.

#### ADD THE DETAILS

From your big picture, key points, opening, and closing, your details are now readily apparent. The presentation almost writes itself at this point. Now you can build your PowerPoint around your key points by putting "the meat on the bones." Having completed these preliminary steps, you can easily avoid drifting, irrelevancies, and the tendency to broaden the presentation to a stream of consciousness.

The AACD prides itself on bringing to the platform dentistry's best presenters. We encourage our members to build on their clinical skills by sharing the wealth of their knowledge with others. Will we see you sometime in the future?




**AACD**  
*comes to*  
**EUROPE**  
*London, England*

## THE AACD IS COMING TO EUROPE!

**THURSDAY, SEPTEMBER 23 – SATURDAY, SEPTEMBER 25, 2010**

*This special event is brought to you by the AACD, the British Academy of Cosmetic Dentistry, the Dental University of Paris Study Group, the European Society of Cosmetic Dentistry, the German Society of Cosmetic Dentistry, and the Swedish Academy of Cosmetic Dentistry.*





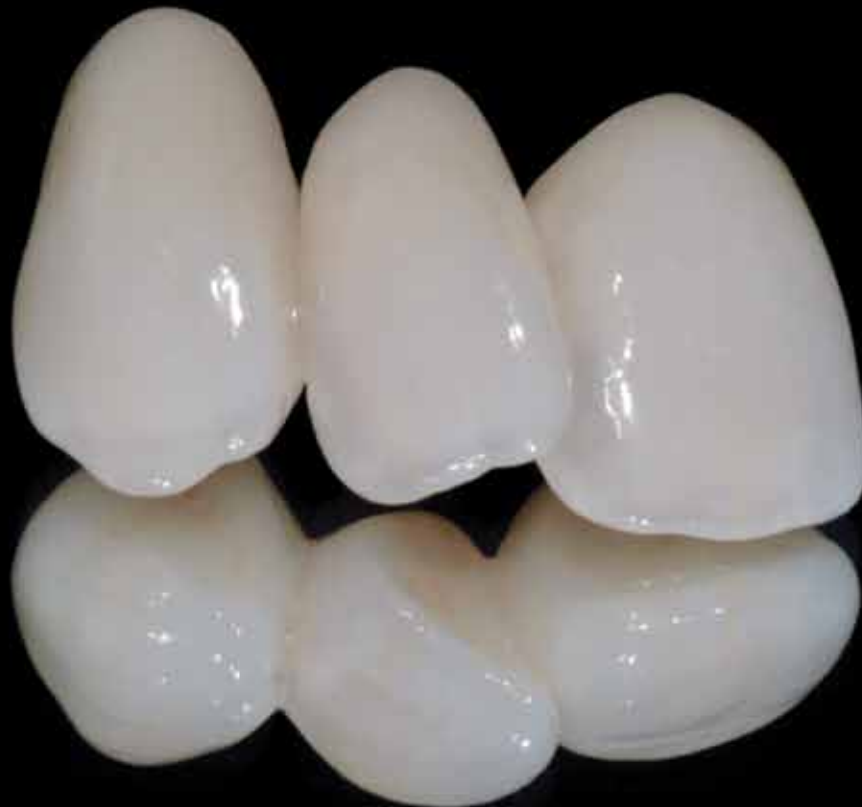

www.aacd.com • info@aacd.com • 608.222.8583



**AMERICAN ACADEMY OF COSMETIC DENTISTRY**

# HOW PERFECTION LOOKS



Ceramics and photography courtesy of Jenny Wohlberg, AACD Accredited Member

**“e.max LITHIUM DISILICATE IS THE MOST ROBUST CERAMIC SYSTEM TESTED TO DATE.”\***

– visit [emaxchangeseverything.com](http://emaxchangeseverything.com) for study results

**IPS e.max<sup>®</sup>**  
all ceramic all you need

[emaxchangeseverything.com](http://emaxchangeseverything.com)



For some, perfection is not an option. For us, it isn't optional.

With the same precision, innovation and attention to detail that has made Valley Dental Technologies one of the premier laboratories for aesthetic and advanced restorative dentistry, Valley Dental Technologies serves as a resource for other laboratories, handling even the most complex and demanding cases with the highest levels of perfection. That is why discerning dental laboratories nationwide are turning to Valley Dental Technologies for the support

they need to deliver exceptional results to the clients. When you work with us, you know the case will be done right. It will be done on your schedule. And it will be done with complete discretion, without compromising your relationships with your dentists.

Our team is here to help you with the products, services and problem-solving consultation you need to serve your clients perfectly.

Now offering IPS e.max:

- Monolithic crowns (one material throughout the entire restoration)
- More durable results than layered zirconia restorations
- Outstanding esthetics
- Conventionally cementable restorations
- Efficiently produced restorations, providing rapid turnaround
- Ability to fabricate a digitally customized restoration

\*Mouth Motion Fatigue and Durability Study  
Petra C Guest, Ricardo Zaccarelli, Nelson Silva and Van P Thompson, NYU



**VALLEY DENTAL  
ARTS**

Valley Dental Arts, Inc | Stillwater, MN

[www.valleydentalarts.com](http://www.valleydentalarts.com) | [info@valleydentalarts.com](mailto:info@valleydentalarts.com)

**1.800.328.9157**

©2009 Valley Dental Enterprises IPS e.max is a registered trademark of Ivoclar Vivadent.

## AACD ACCREDITATION TRACK CASE TYPE II: ONE OR TWO INDIRECT RESTORATIONS



by  
Marty Zase, DMD  
AACD Accredited Member  
(AAACD)  
Colchester, CT  
[www.colchesterdentalgroup.com](http://www.colchesterdentalgroup.com)

*Editors note: This article is based on a lecture held at the 25th Anniversary AACD Scientific Session in Honolulu, Hawaii.*

The overall goal of the Accreditation process is to demonstrate an understanding of and the ability to deliver excellence in cosmetic dentistry. Matching existing natural front teeth with crowns or veneers is one of the most difficult challenges we face in cosmetic dentistry. Accreditation Case Type II tests this skill by requiring the member in the process to provide one or two indirect restorations on maxillary anterior teeth. It requires the dentist to display commanding skills in the following areas:

- case selection and preparation
- communication with the laboratory technician
- laboratory work
- delivery and finishing.

It also requires exceptional patient cooperation and first-rate photography. It therefore is a true test of excellence in cosmetic dentistry; passing this case is a major step in climbing the staircase in the pursuit of Accreditation (Fig 1).

### GOAL OF CASE

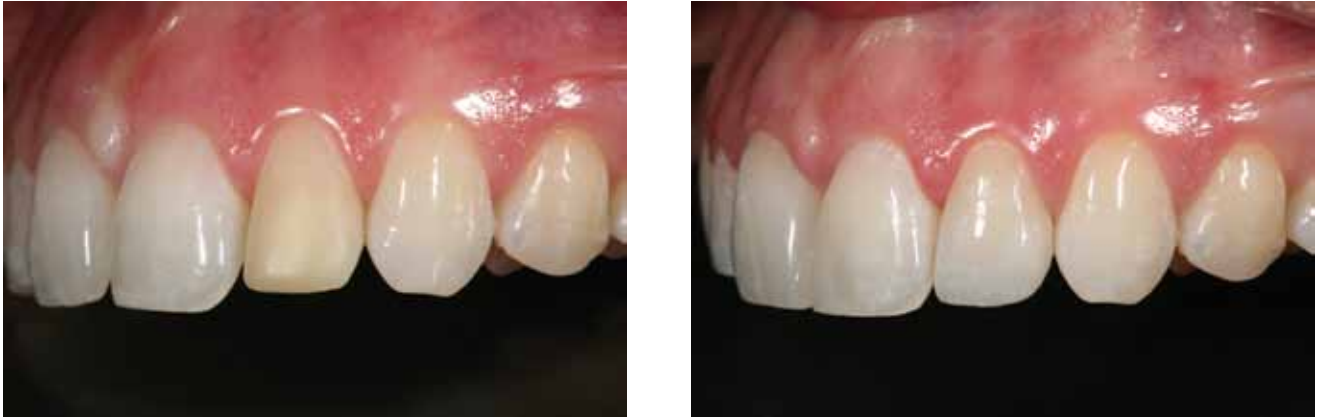The goal of Case Type II is to deliver excellent restoration(s) in a healthy environment while demonstrating the ability to blend the restorative work with adjacent natural teeth so it looks like no dentistry has been done at all.

### THE PROTOCOL (RULES)

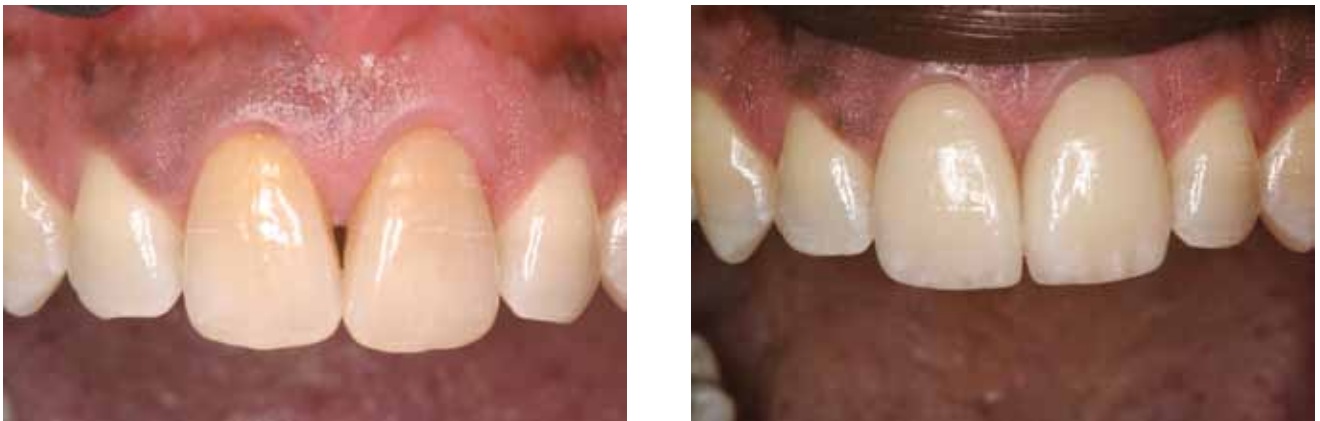One or two indirect restorations are to be done on upper incisor teeth.

No indirect restorations can be present or delivered on the adjacent teeth, although composite is allowed on them.

"If you touch it, it shall be judged." (This rule is very important to understand. For example, if you add some composite on the incisal edge of the adjacent tooth to make it look better, the quality of that composite will be judged at the same standards as the required indirect work.) Figure 2 shows how nicely the incisal edges were added to the lateral incisors, and the excel-



*Figure 1: Passed case, preoperative and postoperative.  
Dentistry and photo by John C. Roberts, DDS, AACD Accredited Member (AAACD).  
Restoration fabricated by Jeffery D. Bennett.*



*Figure 2: Composite added to incisal of laterals is also judged (passed case, preoperative and postoperative).  
Dentistry and photo by Steven A. Gorman, DDS, AACD Accredited Member (AAACD).  
Restoration fabricated by Edgar Jimenez, AACD Accredited Member (AAACD).*

lent blend with the indirect restorations on the central incisors.

All submissions and documentation must follow all rules of the published Accreditation protocol for dentists and laboratory technicians.

## ERRORS

The two most common errors in Case Type II are the result of poor case selection or lack of periodontal health. Case selection errors include an unhealthy environment, a very dark tooth, and challenges that require multidisciplinary ap-

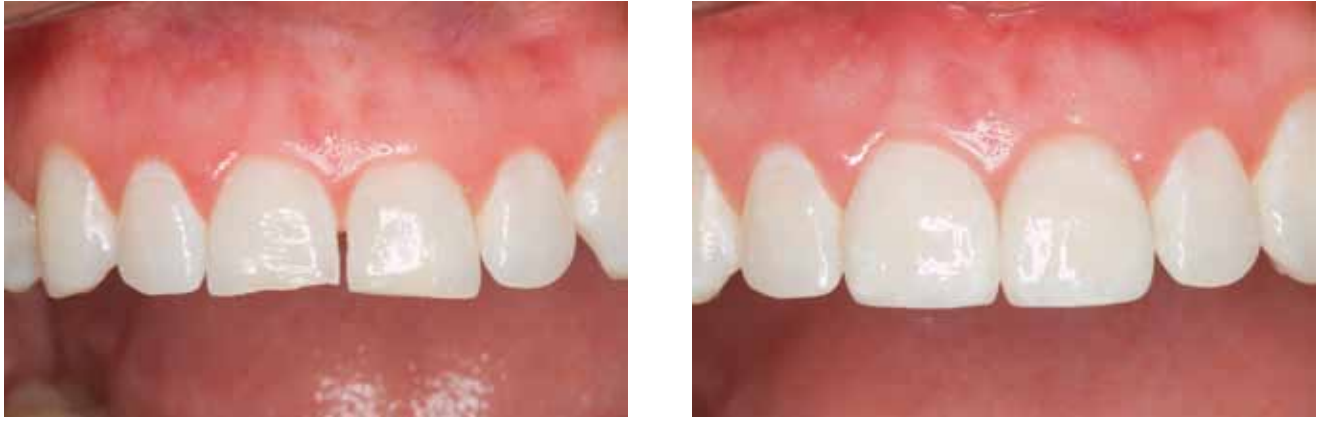proaches in order to succeed. A lack of periodontal health can be a result of less-than-ideal restorative work, inadequate patient cooperation, less-than-ideal supporting structures to start with, or insufficient time after completion to allow for natural healing. All give the same result: The images the examiners have to judge do not reflect ideal cosmetic dentistry because the restorative work is not in a healthy environment.

The next most common error is contralateral tooth disharmony, which, unfortunately, can be demonstrated in many ways. Two central incisors should look very much

alike. Two lateral incisors should look somewhat alike. Some of the ways in which these contralateral pairs could look mismatched include mismatches of shade, size, position, value, gingival height, gingival contour, shape (line angles), texture, characterization, and incisal edges.

Mismatches, as described above, do not have to be contralateral; they can also be related to the rest of the anterior teeth, especially value, opacity, texture, and degrees of facial anatomy.

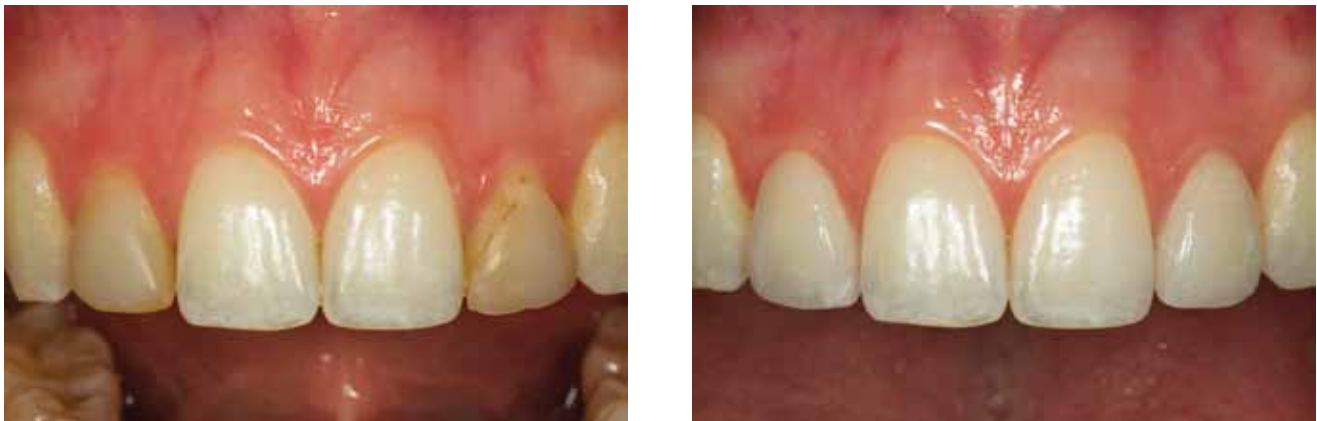Other common errors include an inappropriate midline (either



**Figure 3: Passed case, preoperative and postoperative.**

*Dentistry and photo by James R. Predmore, DDS.*

*Restoration fabricated by James E. Morehead, CDT.*



**Figure 4: Teeth #7 and #10: Characterization makes the case (passed case, preoperative and postoperative).**

*Dentistry and photo by Leslie A. Barrilleaux, DMD.*

*Restoration fabricated by Rick Sonntag, RDT.*

irregular or canted), black triangles (open cervical embrasures), exposed margins, and inappropriate characterization (either too much or too little), insufficient quality of composite added to adjacent teeth, and a reverse smile line or other forms of a lack of central dominance.

Photography errors and omissions can have a negative impact on scoring. All views and radiographs must be included as delineated in the protocol. Improper exposures and moisture or debris on the teeth can make it impossible for the examiners to accurately judge a case.

### TIPS

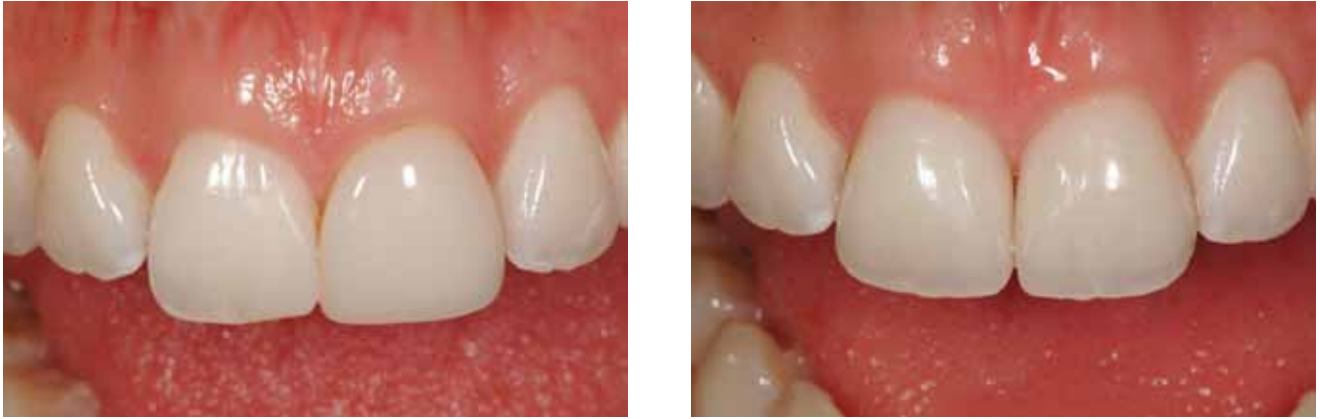There are more than 40 examiners, and they all have suggestions on how to increase the odds for success. Listen to them. However, the very best advice is to learn what each case is supposed to demonstrate, and then do excellent cosmetic dentistry to show that you both understand it and can produce it.

The examiners are calibrated semi-annually and they judge cases anonymously. They are very objective. There are degrees of errors: Minor, major, and catastrophic. Increase your odds—aim higher than borderline (Fig 3).

### CASE SELECTION

Pick straightforward cases; there are no extra points for selecting difficult cases, just extra challenges. Great improvement does not matter; creating excellence does. Avoid teeth with dark roots or coronal tooth structure. It is usually easier to achieve excellence with one or two laterals or two central incisors than by treating a single central incisor. If there is an existing lack of balance in gingival architecture, either fix it or do not select the case—the fact that they do not show in a smile view is not an excuse for gingival discrepancies (they do show in retracted views,





**Figure 5: Passed case, preoperative and postoperative.**  
Dentistry and photo by John F. Weston, DDS.  
Restorations fabricated by Todd Cochran.

and this is a test of understanding what excellence is, whether or not it shows). Do not select patients who are non-compliant in their home care routine for Accreditation; optimal periodontal health is critical to the final result.

#### MATERIALS

Metal or zirconia core-supported restorations increase the difficulty in duplicating the natural translucency seen in natural teeth. Situations that are suitably restored with feldspathic or pressed porcelain have a greater opportunity for an optimal esthetic result. Likewise, tooth-colored posts are also preferable to metal posts. If there is a need to close open cervical embrasures, it is preferable to add to the contour of the teeth on either side of the embrasure. Consider adding composite at the cervical of the adjacent tooth.

#### LABORATORY COMMUNICATIONS AND PHOTOGRAPHY

Develop excellent communication skills with your laboratory technician partner. Be sure you understand the normal distribution of shade changes in natural teeth. Become observant enough so you can make an accurate color map of

the tooth or teeth you are trying to match, including incisal edge shade, translucence shade, body shade, and gingival shade. Photograph and describe well the characterizations you desire. Consider black-and-white or sepia-tone photographs to help showcase value, texture, and anatomy. When photographing shade tabs, have the shade tab in the same plane as the tooth and at the same distance from the camera. Do not forget to include the shade tab label in your photographs. And perhaps most important, take your photographs at the beginning of the procedure, before the teeth dehydrate.

Excellent Accreditation images require that the teeth and tissue be clean and dry. It is helpful if an assistant blows air lightly across the entire photographic field just prior to each photograph. This should eliminate moisture getting caught between the teeth, especially at the cervical.

#### GENERAL

Use a midline and incisal edge transfer device to provide maximum information on those two properties to your laboratory technician.

If there is significant characterization, plan on a separate try-in visit, when you can take photographs of the restoration in place; if necessary, you can send the case back for fine-tuning of the characterization. See Figure 4 for an example of excellent characterization.

Allow plenty of time for gingival healing before the submission deadline. Give the patient an oral hygiene aid and make sure they use it.

And, once more, aim for excellence. If you produce it, the examiners will recognize your achievement, and you will be on your way to becoming Accredited by the American Academy of Cosmetic Dentistry (Fig 5).

#### AACD Acknowledgment

*The American Academy of Cosmetic Dentistry recognizes Dr. Marty Zase as an AACD Accredited Member (AAACD), AACD Past President (2006-2007), and Accreditation Examiner and mentor.*



# Redeem your FREE eGift!

How do I earn continuing education credits from the comfort of my own home or office?

## 1. Navigating to the AACD eLearning Program portal.

Visit [www.aacd.com](http://www.aacd.com) and click "Conferences & Education."

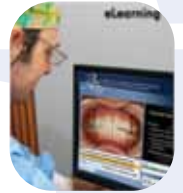CONFERENCE & EDUCATION

Log in with your Member ID and Password located on the top right corner of the page.

Find a Cosmetic Dentist **Member Login**  
Join AACD • Find a Laboratory Technician

Click on the eLearning image located at the bottom right of the Conferences & Education page.

(If you are a new user of the AACD eLearning Program you will be asked to verify your account before proceeding.)



## 2. Redeeming your FREE eGift.

Click "Register" at the top of the page.

Register • See Courses • Our Presenters • Pricing • How

Make sure "1 Course - \$120 (USD)" is selected. In the "Promo Code" box enter eGift and then click "Purchase" at the bottom of the page.

1 Course - \$120 (USD)

Promo Code

If you have a promo code, enter it here:

Confirm your promo code by clicking "Purchase".

Purchase

## 3. Viewing your course online.

Scroll through the list of courses and select the course you would like to view.

Course Title	CE's Earned	Duration
DURAthIn Prepress Veneers (AACDcos101)	1	1 hour
Synopsis: Dr. Dennis Wells, the creator of DUR		

Click "Watch Course" when you have selected the eLearning course you are interested in viewing.

DURAthIn Prepress Veneers

watch sample

CE's Offered: 1  
Presenter: Dennis J. Wells, DDS

watch course

Take **ADVANTAGE** of this special **AACD** members-only exclusive offer before it expires on Friday, **JANUARY 30, 2010.**

**CONTACT THE AACD Executive Office** if you need assistance redeeming your **FREE eGift.**

# ELEARNING

## IN THIS SECTION:

---

ELEARNING PROGRAM REVIEW: THREE-PART VIDEO SERIES—ACCREDITATION CASE TYPE I: SIX OR MORE INDIRECT RESTORATIONS ❖ BY JOHN F. WESTON, DDS, FAACD.....	68
--	----

## eLEARNING PROGRAM REVIEW: THREE-PART VIDEO SERIES—ACCREDITATION CASE TYPE I: SIX OR MORE INDIRECT RESTORATIONS



by John F. Weston, DDS  
AACD Accredited Fellow  
Member (FAACD)  
La Jolla, CA  
[www.scrippsdenalcare.com](http://www.scrippsdenalcare.com)

The goal of this section is to enhance your experience and education through AACD's online eLearning Program. As cosmetic dentistry continues to rapidly evolve, it is even more essential that you seek progressive dental education and invest in yourself and your team. The AACD eLearning Program is being offered to all members as the AACD expands its educational offerings on a global level.

In this first article, regarding AACD's Accreditation Case Type I: Six or More Indirect Restorations, Dr. John Weston covers the three-part eLearning courses (mock-up, preparation, and seating). This column will be a continued series that will provide additional education written by an eLearning educator and will complement the material covered in their eLearning course offered on [www.aacd.com](http://www.aacd.com).

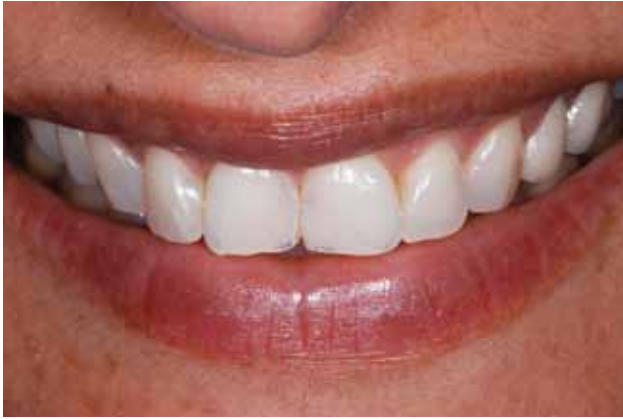For a limited time, AACD members can receive a free, Certified Continuing Education AACD eLearning course on demand. Visit [www.aacd.com](http://www.aacd.com) today, click on Conferences and Education, click on the eLearning button, and review the eLearning library. If you wish to watch a course, enter the promotion code: *eGift* to receive credits toward one free eLearning course. This offer ends January 30, 2010.

For more details and instructions, see page 66. If you have questions or need assistance, please contact the AACD Executive Office at 800.543.9220, 608.222.8583, or [meetings@aacd.com](mailto:meetings@aacd.com).

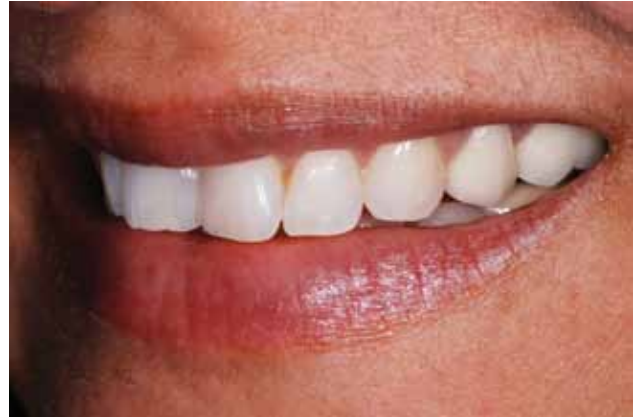---

### BACKGROUND

The Accreditation journey can be a very rewarding process. The body of work you present is a combination of educational and clinical efforts that could ultimately culminate in success. In an effort to expand the educational opportunities for our members, the AACD now offers online courses to aid you in your search for the type of education that suits you best. The AACD's creden-



*Figure 1: Preoperative smile; incisal wear and shade were primary issues.*



*Figure 2: Preoperative smile, left side; note rotations of central incisors.*

tial process will challenge your abilities while training your esthetic eye, and the results may surprise you. The criteria used to evaluate Accreditation cases are based on sound, responsible treatment parameters designed to help the clinician create beautiful, functional, and lasting results.<sup>1</sup> Whether you achieve the credential or not becomes secondary to the changes that occur in your approach and execution of cosmetic cases. Even though Accreditation-level dentistry is not an everyday phenomenon, most that go through the process never look at a case the same way again. The bar is set higher and your dentistry will never be the same.

## DISCUSSION

Conservative restoration of anterior teeth to correct rotations, symmetry, color, and wear is a common presentation in dental practices. In order to create natural contours and undetectable restorations, each case requires precise planning, accurate preparations, and detailed laboratory communication. Every effort must be made to offer the patient orthodontic repositioning as a pri-

mary alternative or in conjunction with restorative care. If a total restorative option is elected, it should be with the understanding that permanent changes will most likely have to be made to the natural teeth. While preparation-less options do exist, if the rotations are significant or the shade change is significant, it may not be possible to properly correct the problem without adding inappropriate thickness to the teeth. As restorative dentists, our goal should always be to conserve as much tooth structure as possible while still allowing the ceramist the proper amount of space required for porcelain.

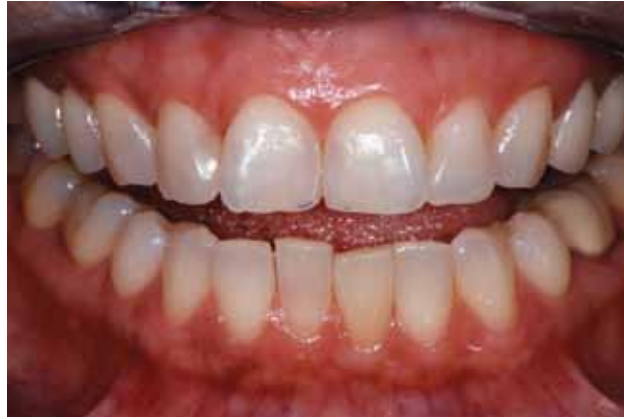## OVERVIEW AND PATIENT HISTORY

This 45-year-old patient presented with a chief complaint of wanting her teeth lengthened, rotations repaired, and shade brightened (Figs 1-5). Orthodontic consultation was recommended; however, the patient already had received orthodontic treatment in the past and had now elected a restorative option. Clinical and radiographic examination revealed a relatively healthy dentition, some incisal

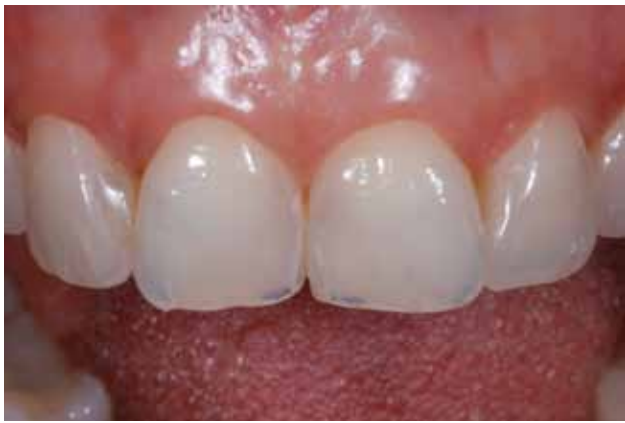wear with minor abfractions, and obvious parafunctional habits that would need to be addressed.<sup>2</sup> It was agreed that in order to visualize the case properly and develop contours for provisional and permanent restorations, a composite mock-up was indicated. This is a valuable tool that helps the clinician and patient visualize the final results. The patient had a pre-existing crown on #12. It was agreed that the goal would be to place conservative porcelain indirect restorations on the upper front eight teeth, ##5-12.

## RECORDS AND SMILE DESIGN

A complete AACD series of photographs was made, including additional photographs of the lips in repose (Fig 6) and shade tab calibration. Maxillary and mandibular preoperative models were taken along with a facebow using a SAM 3 articulator (Great Lakes Orthodontics; Tonawanda, NY). Study casts were mounted with a passively obtained open bite centric relation record using a deprogrammer. The intraoral mock-up was completed (Fig 7) using flowable composite without etch and following basic smile de-



*Figure 3: Preoperative retracted view, acceptable gingival contours.*



*Figure 4: Preoperative close-up view of anterior four teeth; note enamel surface crazing.*



*Figure 5: Preoperative portrait study.*

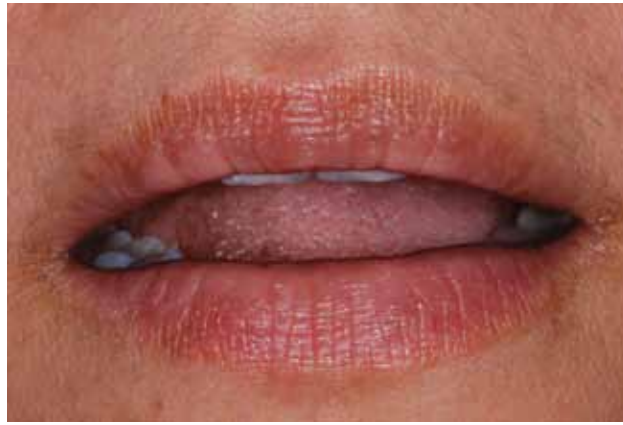sign principles, setting the incisal edges of #8 and #9 first.<sup>3</sup> Areas that required tissue alteration could simply be overlaid with composite to simulate the effect. This case did not require any gingival height changes. Basic contouring of the mock-up was completed with a fine diamond and photographs were taken to compare with the preoperative condition. After checking phonetics, minor corrections, and approval by the patient, incisal and facial reduction guides were made using Blu-Mousse (Parkell; Farmingdale, NY)

and then a detailed over-impression was made using clear bite. These steps need to be completed prior to removing any of the mock-up.<sup>4</sup>

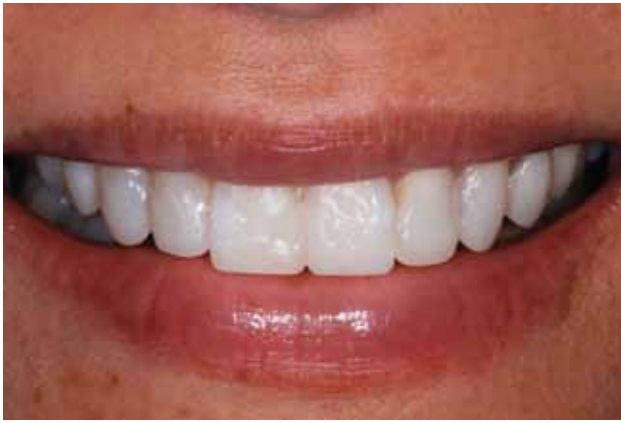#### **CLINICAL SESSION**

Constant referral to reduction guides was made throughout the preparation phase to ensure the teeth were properly but not over-reduced. Typically, 1.5 mm is needed from the incisal edge and a minimum of .2 to .5 mm facial is acceptable.<sup>5</sup> Electric headpieces help create a smooth uniform surface and all

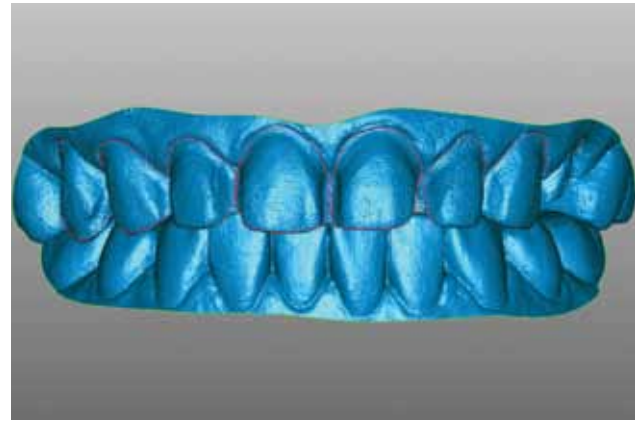
sharp edges must be softened. It is imperative to carry your margin interproximally and into the contact areas to avoid seeing the veneer margins at the proximal gingival areas. I also recommend placing a red perforated diamond strip interproximally between all preparations to create a very subtle space between teeth so the ceramist will be able to separate the die and build a more precise margin. Every effort was made to treat the soft tissue as delicately as possible throughout the procedure; this facilitates final impression mak-



*Figure 6: Lips in repose; note lack of proper display.*



*Figure 7: Intraoral composite mock-up.*



*Figure 8: COS digital bite scan of preparations and opposing occlusion.*

ing and reduces the potential for changes in gingival contour.

The preparations were coated with crown and bridge lubricant and provisionals were fabricated using Protemp (3M ESPE; St. Paul, MN) inside the over-impression of the mock-up. The provisional was teased off carefully and trimmed outside the mouth. Any voids can be repaired with flowable composite.

Final impressions were made with the 3M Lava chairside oral scanner (COS) (Figs 8-10). This digital technology is unique in the industry and is not a point-and-click

system. By using three-dimensional high-resolution video, we were able to capture the preparations, opposing, and centric occlusion bite in just a few minutes. This unique digital impression system provides an extremely accurate stereo lithography apparatus (SLA) model that is received by the laboratory in three days. This system allows the clinician to choose any restorative material they desire, including porcelain-fused-to-metal, pressed, feldspathic, zirconia, and milled CAD/CAM materials.

## DISCUSSION

It is important to obtain an accurate stump shade, and photographs of the moist preparations were made with a shade guide in the view (Fig 11). Provisionals were then tried in and final trimming completed intraorally using a flame diamond and light pressure. Instead of polishing, the provisionals were micro-abraded and coated with BisCover sealer (Bisco; Schaumburg, IL). The preparations were then disinfected with Consepsis (Ultradent; South Jordan, UT), spot-etched, and rehydrated with Gluma (Heraeus; South Bend, IN), after which Single Bond

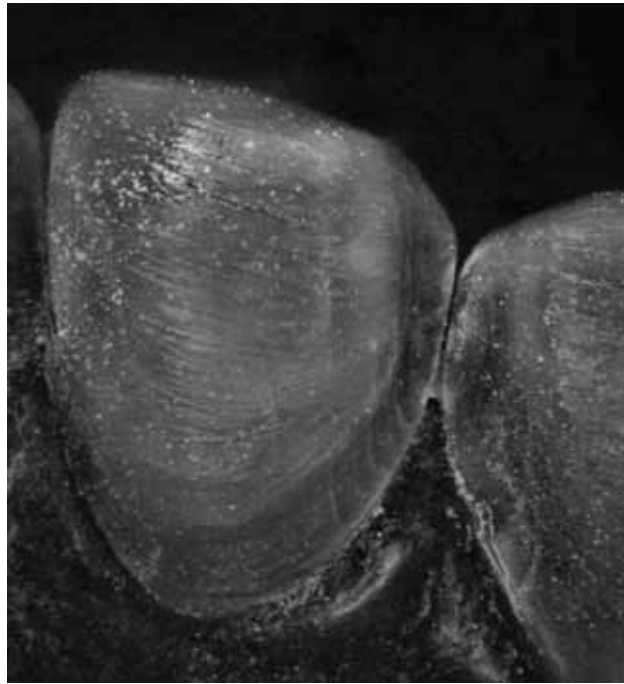


Figure 9: COS three-dimensional video image margin verification.

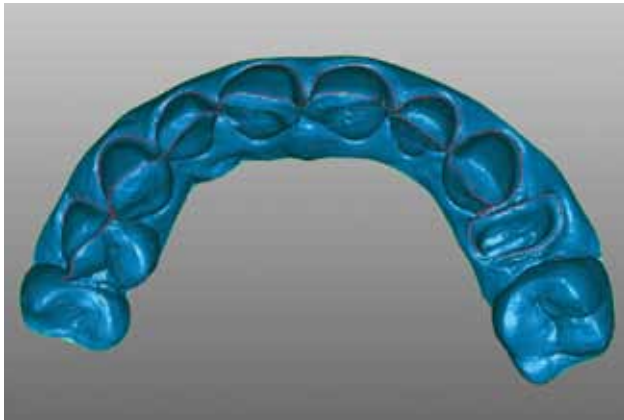


Figure 10: COS digital occlusal scan showing preparations.

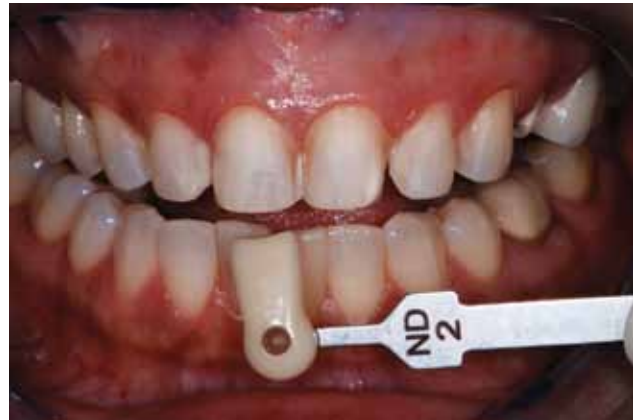

Figure 11: Preparations with stump shade tab for laboratory communication.

(3M) was placed. The provisionals were seated with flowable composite, cleaned, and light-cured. After occlusion was verified and contours refined, an impression was made of the provisionals for the ceramist. Detailed written postoperative instructions were given to the patient.

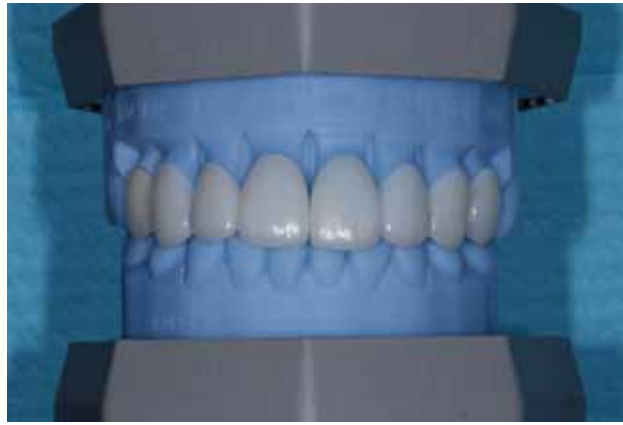I believe that the style of the preparations is determined clinically, and the restorative materials are

determined in the laboratory. I also feel it is important to have an idea as to what style of restoration suits the case best prior to touching any tooth with a bur.

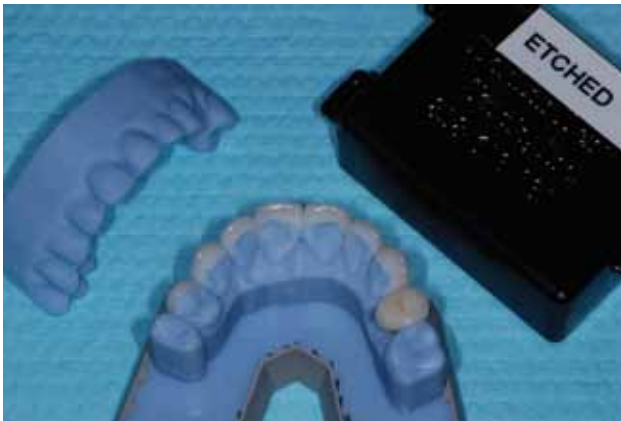In a case like this it is obvious that minimal reduction is desired, so a feldspathic restoration or thin pressed material is indicated. When properly fabricated and seated, feldspathic veneers can be very lifelike

and durable. To automatically prepare a tooth in order to fit the parameters of a restorative material regardless of the situation is simply unjustified. It is imperative that the ceramist receive all the information needed to properly build the case to the contours established during the clinical mock-up. All details are worked out in the mock-up and provisionals so there are no "surprises" at delivery. With proper interocclu-

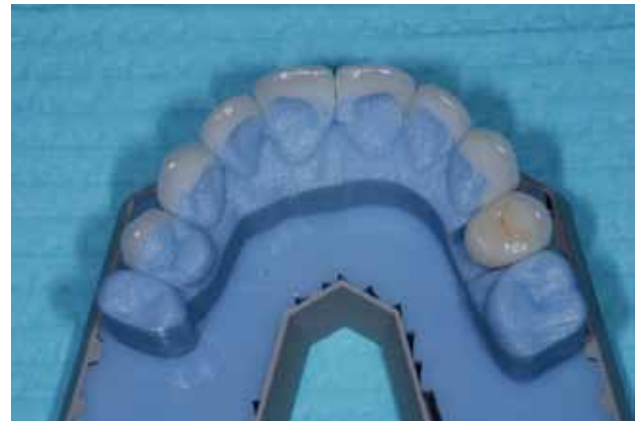



*Figure 12: SLA models are durable, clean, and delivered to the laboratory articulated with ditched and pinned dies.*



*Figure 13: Solid model is included for proximal contact verification of etched restorations.*



*Figure 14: Verification of marginal fit prior to insertion.*

sal records, the ceramist has the ability to cross mount the preoperative, mock-up, provisionals, and preparation casts for excellent comparison while building the case. A comprehensive laboratory prescription is included to establish goals for many items, including shade, texture, amounts of translucency, changes required from the provisionals, and specific patient desires (Figs 12-14).

## DELIVERY

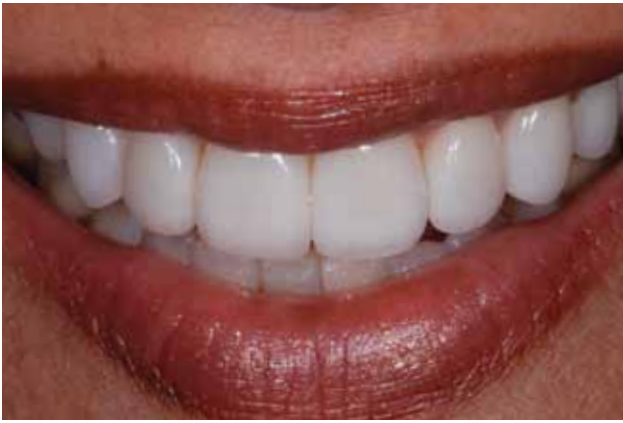Provided the patient follows instructions for hygiene, tissues should be in excellent condition and ready

for insertion. We always dispense a small bottle of chlorhexidine to the patient and give instructions to dip and brush gingival/interproximal areas.

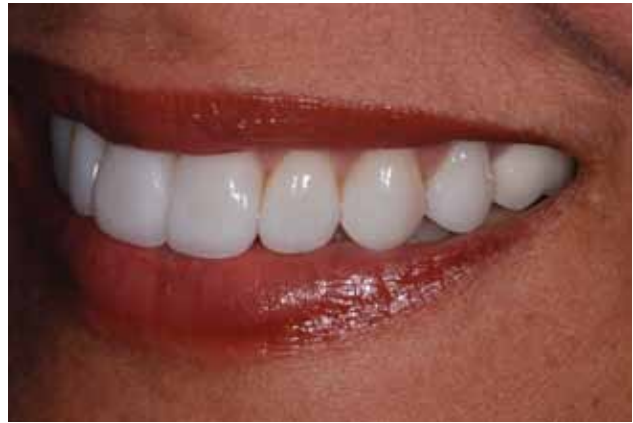After local anesthesia was placed, slices were made to proximal areas and buccal surfaces of the provisionals. Using a spoon excavator, the provisionals were removed in sections. Spot-etched areas required a slight dusting with a medium diamond to remove any bonded composite. The preparations were then aggressively scrubbed with chlorhexidine and pumice, being careful to clear the interproximal areas of cement and de-

bris. A single restoration was tried in with glycerin to verify that the selected shade was achieved. Rubber dam isolation was accomplished using the slot technique, and the preparations were cleaned and rinsed again.

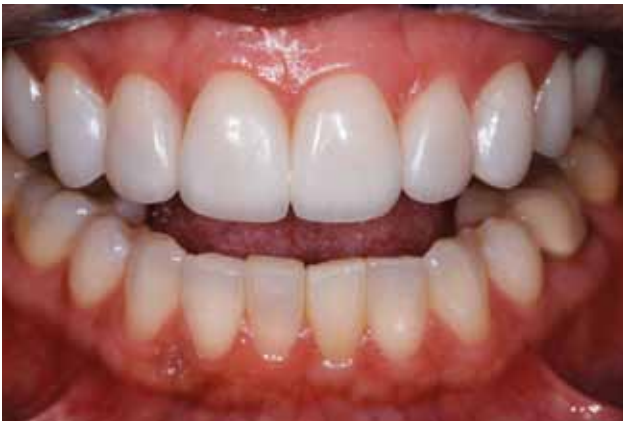A complete dry try-in was then accomplished to verify marginal integrity and proximal contacts. The intaglio surfaces of the veneers were then re-acidified with 35% phosphoric acid etch, silane-primed, and coated with adhesive.<sup>6</sup> All preparations were total-etched and rehydrated with Gluma, primed, and then adhesive was placed (Scotch-bond Multipurpose, 3M).



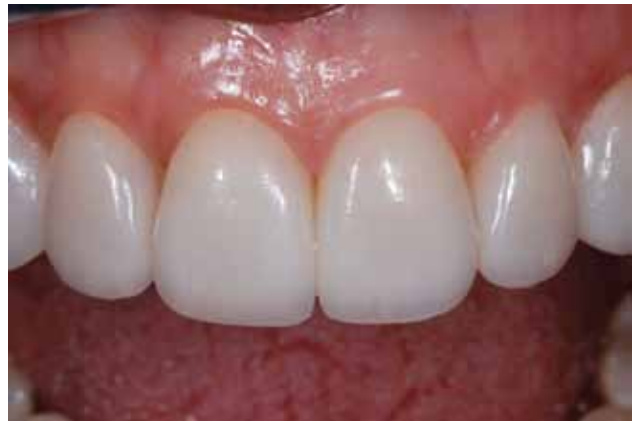*Figure 15: Postoperative smile showing harmonious restorations.*



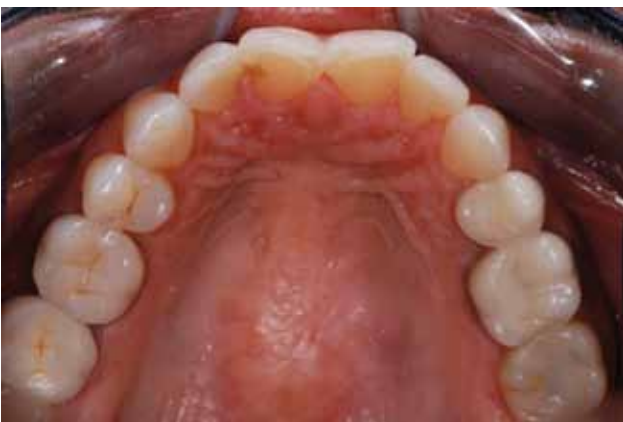*Figure 16: Postoperative left smile; note proper progression of incisal embrasures.*



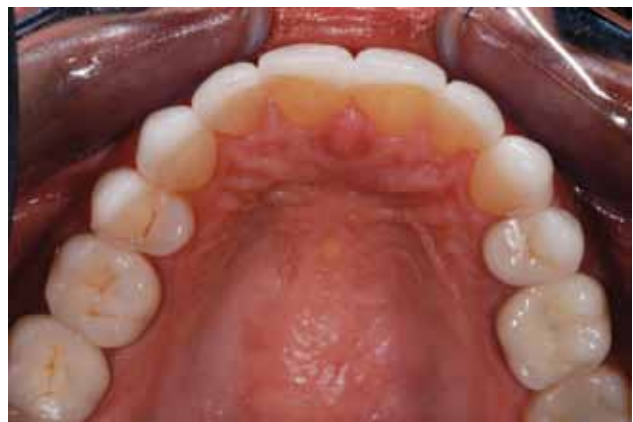*Figure 17: Postoperative retracted view.*



*Figure 18: Postoperative close-up view of anterior four teeth.*



*Figure 19: Preoperative occlusal view showing rotations and wear.*



*Figure 20: Occlusal view; note proper facial embrasures.*



*Figure 21: Final portrait, taken at in-office studio.*

All veneers were seated at the same time, starting from the midline and working distally. Facial surfaces were initially cleaned and veneers were tack-cured at the gingival zenith for two seconds. The remainder of the cement was then cleaned using a camel hair brush and final curing was accomplished with an oxygen barrier. Interproximal separation was completed with Ceri Strips (CeriSaw, Den-Mat; Santa Maria, CA) and finished with a perforated narrow yellow diamond strip (3M). Gingival cement was removed using a #12 Bard-Parker blade (Becton Dickinson; Franklin Lakes, NJ). No burs were used on the facial margins. Occlusion was then verified and lingual surfaces polished with a fine football-shaped diamond and rubber points (Shofu; San Marcos, CA).

## CONCLUSION

Bonding porcelain to tooth structure using modern adhesives has allowed clinicians to create some of the most beautiful restorations ever seen. I believe that cases should

always be designed to accomplish desired restorative corrections by altering the fewest number of teeth possible and removing the least amount of tooth structure possible. When proper planning and laboratory communication are combined with skill and excellent patient communication, the results can be dramatic, yet blend naturally with the original dentition (Figs 15-21). Educating our patients about what constitutes "esthetics" is an important factor, remembering that subtle randomness in shape and contours of hard and soft tissue can help to create balance and harmony of the restorations.<sup>7</sup> There are times when golden proportions are not the best choice and may contribute to an artificial or contrived smile.<sup>8</sup> The outcome of this case represents all that we strive to accomplish with modern materials and techniques, while meeting our goal of conservative yet reliable and functional cosmetic correction of minor dental anomalies.

As an Accreditation and Fellowship Examiner, I have a unique perspective and tend to be very critical of my cases. This case is not a "slam-

dunk" pass and there are some deficiencies, but that is the reality of clinical dentistry. It is probably a borderline case. I do feel it is important to understand that often there are cases that pass Accreditation by a narrow margin. They often have subtle criteria violations but the overall results show that the clinician has superior knowledge, skill, and a level of understanding that puts the case in the "zone of excellence." In the end, I believe that case selection is one of the most critical areas that can help determine a successful Accreditation case. This case is an example of what to look for when approaching Case Type I.

*For more information, readers are directed to Dr. Weston's interview in the July/August 2009 issue of Academy Connection, or the online course at [www.aacd.com](http://www.aacd.com).*

*The American Academy of Cosmetic Dentistry eLearning Program is an easy-to-use tool—all you need is a computer and internet access. To continue your education, please visit [www.aacd.com](http://www.aacd.com) to watch Dr. John Weston complete an indirect veneer case through his*

*eLearning course. Remember to use promotion code eGift to receive your free course.*

### References

1. American Academy of Cosmetic Dentistry (AACD). A guide to Accreditation criteria. Madison (WI): AACD; 2001.
2. Dawson PE. Evaluation, diagnosis, and treatment of occlusal problems. St. Louis (MO): Mosby; 1989. p. 47-52.
3. Kokich VO, Kokich VG, Kiyak HA. Perceptions of dental professionals and laypersons to altered dental esthetics: asymmetric and symmetric situations. *Am J Orthod Dentofacial Orthop.* 2006;130:141-51.
4. Strupp WC. Achieving predictability in anterior crown and bridge with the use of indexes. *C & B Update.* 1997;2(9):65-71.
5. Magne P, Belser U. Bonded porcelain restorations in the anterior dentition: a biomimetic approach. Hanover Park (IL): Quintessence Pub.; 2002.
6. Kanca J. Improving bond strength through acid etching of dentin and bonding to wet dentin surfaces. *JADA.* 1992;123:35-44.
7. Terry DA, Geller W, Tric O, Anderson MJ, Tourville M, Kabashigawa A. Anatomical form defines color: function, form, and aesthetics. *Pract Proced Aesthet Dent.* 2002;14:59-67.
8. Chiche GJ, Pinault A. Esthetics of anterior fixed prosthodontics. Hanover Park (IL): Quintessence Pub.; 1994.

### AACD Acknowledgment

*The AACD recognizes Dr. John Weston as an AACD Accredited Fellow Member (FAACD), member of the American Board of Cosmetic Dentistry (ABCD), and Accreditation Examiner.*



# E LEARN MORE.

Current  
AACD eLearning  
Program educators include: Gary Alex, DMD, Bobbi Anthony, RDH, Mickey Bernstein, DDS, Hugh Flax, DDS, Susan Hollar, DDS, David Hornbrook, DDS, George Kirtley, DDS, Michael Koczarski, DDS, Ed Lowe, B.Sc., DMD, Thomas Nabors, DDS, Robert Ritter, DMD, Larry Rosenthal, DDS, Trent Smallwood, DDS, Tom Trinkner, DDS, Dennis J. Wells, DDS, John Weston, DDS, and Corky Willhite, DDS.  
Visit [www.aacd.com](http://www.aacd.com) to learn more.

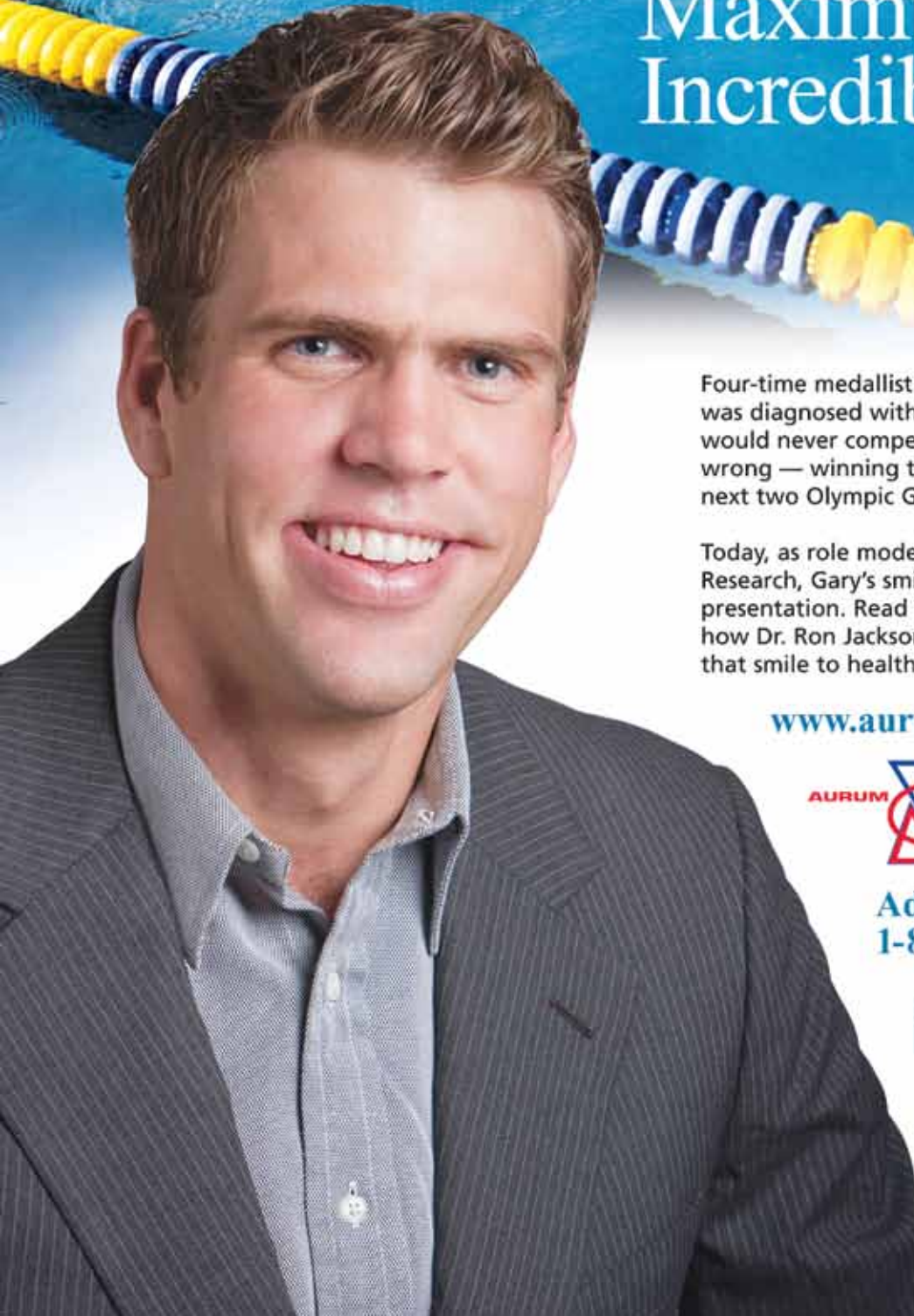
Experience the AACD eLearning Program. This exclusive member learning tool is designed to elevate your skills to a whole new level of dentistry, at your convenience, from the comfort of your own home or office, and at a pace that works best for you. Remember to use promo code "eGift" by January 30, 2010 to redeem one FREE elearning course. See page 66 for details.

[www.aacd.com](http://www.aacd.com) • 800.543.9220 • 608.222.8583





*Reflections of Excellence*  
Maximum Effort...  
Incredible Results!



Four-time medallist at the 1996 Olympics, Gary Hall Jr. was diagnosed with Type 1 Diabetes in 1999. Told he would never compete again, he proved everyone wrong — winning three more gold medals over the next two Olympic Games!

Today, as role model and advocate for Diabetes Research, Gary's smile is an integral part of his presentation. Read Gary's inspirational story, and learn how Dr. Ron Jackson and Aurum Ceramic restored that smile to health, at:

[www.aurumgroup.com](http://www.aurumgroup.com)



**Advanced Esthetic Hotline**  
**1-800-661-1169**

**Empress**  
ESTHETIC

For aesthetically sensitive cases, no material performs like IPS Empress Esthetic. No other laboratory can match Aurum Ceramic in making the most of your IPS Empress Esthetic restorations.

Dentistry courtesy of Dr. Ronald D. Jackson, Middleburg, VA.  
Restorations fabricated by Aurum Ceramic.  
Photography courtesy of Larry Gatz.

# GIVE BACK A SMILE™


## IN THIS SECTION:

---

A GLIMPSE INTO DOMESTIC VIOLENCE.....	80
CAUSE AND EFFECTS OF DOMESTIC VIOLENCE.....	83
A NEW SMILE, A NEW OPPORTUNITY ❖ BY <i>IRA M. LANGSTEIN, DDS</i> .....	87

# Ask Your Patients to Restore a Life and a Smile with You.

Together with your patients, help heal the effects of domestic violence by restoring a life and a smile. Take part in the 2009-2010 Give Back A Smile (GBAS) Whitening Challenge from Tuesday, September 1, 2009 – Wednesday, March 31, 2010. Simply ask your patients to donate the cost of their next teeth whitening to GBAS. Patient trust and loyalty are reinforced from your giving; plus, volunteers who donate the most whitenings will receive special recognition and prizes. Get involved.



*A* *charitable*  
**FOUNDATION**

800.543.9220 • 608.222.8583 • [www.givebackasmile.com](http://www.givebackasmile.com)



give back a  
**smile**™

## A GLIMPSE INTO DOMESTIC VIOLENCE

*The AACD Charitable Foundation's Give Back A Smile™ (GBAS) program restores the smiles and lives of domestic violence survivors at no cost. In this issue, we share with you statistics regarding domestic violence, the cause and effects of domestic violence, as well as our regular column, a GBAS success story, written in this issue by Dr. Ira Langstein. The AACD is grateful to all GBAS volunteers and recipients.*

*We hope this vital information will shed more light on how serious of a widespread social problem domestic violence is, and how you can help through the GBAS program. Please contact the AACD Executive Office at 800.543.9220 or [givebackasmile@aacd.com](mailto:givebackasmile@aacd.com) to find out how you can volunteer. Thank you in anticipation.*

### ALABAMA

- 30,717 reported domestic assaults in 2007
- 32 homicides due to domestic violence in 2007

### ALASKA

- Over 6,000 reported cases of domestic violence in 2005
- Alaska has the highest rate per capita of men murdering women

### ARIZONA

- Every 44 minutes in Arizona, one or more children witness a domestic violence incident
- 125 domestic violence fatalities in 2007

### ARKANSAS

- In 2007, there were 30 domestic violence related homicides
- The state is ranked first in domestic violence homicides for African-American women in the United States

### CALIFORNIA

- California law enforcement received 176,299 domestic violence-related calls in 2006

- 43,911 people were arrested for domestic violence offenses in 2006

### COLORADO

- 14,123 domestic violence criminal cases filed in Colorado county courts in 2006
- 41 people died as a result of domestic violence in 2006

### CONNECTICUT

- 20,102 reported cases of domestic violence in 2005
- 25 deaths due to domestic violence in 2005

### DELAWARE

- In 2006, there were 16,310 criminal domestic violence incidents
- 15% of the criminal domestic violence incidents resulted in serious injury

### DISTRICT OF COLUMBIA

- From January to June 2007, the Metropolitan Police Department (MPD) received 12,806 domestic violence-related calls
- From 2002 to 2005, the MPD reported that the number of

domestic violence-related calls increased 22%

### FLORIDA

- 115,150 reported cases of domestic violence in 2007
- 189 domestic violence-related homicides in Florida in 2007

### GEORGIA

- In 2006, 106 Georgia citizens lost their lives due to domestic violence
- Police responded to 54,010 family violence incidents in 2006

### HAWAII

- 8,013 reported cases of domestic violence in Hawaii in 1999
- Hawaiian shelters serviced 848 victims in 1999

### IDAHO

- 6,252 incidents of intimate partner violence were reported in 2006
- Nearly 26% of all murders in Idaho were committed by a family member of the victim



## ILLINOIS

- 114,921 reported cases of domestic violence in 2006
- 39 domestic-related homicides in 2006

## INDIANA

- From 2006 to June 2007, there were 75 domestic violence related deaths
- During that time, there were 104,437 calls to Indiana's crisis hotline

## IOWA

- 7,047 reported cases of domestic violence in 2005
- 49% of the victims were cohabitants of the abusers

## KANSAS

- 21 domestic violence homicides were reported in 2006
- In 2006, a domestic violence incident occurred once every 22 minutes and 48 seconds

## KENTUCKY

- Spouse abuse program received 33,027 domestic related calls in 2006
- 3,786 victims of domestic violence were sheltered in 2006

## LOUISIANA

- More than 3,500 orders for protection were issued in 2005
- In 2005, the state had the third highest number of females murdered by males in the nation

## MARYLAND

- 21,965 domestic violence crimes were reported to law enforcement agencies in 2006
- 22 women were killed as a result of domestic violence from July 1, 2006 to June 30, 2007

## MASSACHUSETTS

- The statewide domestic violence hotline answered 21,637 domestic violence calls in 2006
- 42 victims killed in domestic violence related incidents

## MICHIGAN

- About 4 of every 10 females seen in selected emergency departments for injuries related to assault were there because of intimate partner violence
- 103,389 domestic violence offenses were reported to Michigan Uniform Crime Report Program in 2003

## MINNESOTA

- At least 17 women were murdered as a result of domestic violence in 2007
- 12,067 orders of protection filed in 2006

## MISSISSIPPI

- Ranks second highest in the nation for domestic violence
- Ranks fifth in the nation for domestic violence related homicides

## MISSOURI

- In 2007, law enforcement agencies reported 37,215 incidents of domestic violence
- 35 domestic violence homicides were reported in 2007

## MONTANA

- In 2003, more people were abused by a batterer in Montana than babies born
- In 2003, batterers killed 11 people

## NEBRASKA

- Domestic violence contributed to 46% of the 30 child deaths in Nebraska occurring between 1998 and 2003

- 1,667 arrests were made for offenses against family and children in 2004

## NEVADA

- 9,022 domestic violence incidents reported in 2007
- 8,661 men and 3,023 women were arrested for incidents of domestic violence in 2001

## NEW HAMPSHIRE

- In 2006, there were 2,223 reported incidents of domestic violence
- In 2006, services were provided by member programs of the New Hampshire Coalition Against Domestic and Sexual Violence to 10,074 victims of domestic violence

## NEW JERSEY

- 73,749 domestic violence offenses were reported in 2006
- 1,720 women, 1,903 children, and six men were sheltered by domestic violence programs in 2006

## NEW MEXICO

- 25,348 domestic violence incidents reported to law enforcement in 2006
- 34 homicides as a result of domestic violence in 2007

## NEW YORK

- 50,088 reported cases of domestic violence in 2006
- 133 homicides were a result of domestic violence in 2006

## NORTH CAROLINA

- In 2006, there were 79 homicides that resulted from domestic violence, 73% of the victims were female and five victims were children
- Between 2002 and 2003, North Carolina's domestic violence

hotline received 90,341 crisis or support calls

#### **NORTH DAKOTA**

- 4,496 incidences of domestic violence were reported to the North Dakota Crisis Intervention Center in 2007
- Of the total number of victims, 95% were women

#### **OHIO**

- 20,608 domestic violence cases were filed in 2006
- 345 deaths occurred as a result of domestic violence in 2006

#### **OKLAHOMA**

- Ranks 10th nationally for the number of females murdered by males
- According to a study conducted by the National Clearinghouse for Defense of Battered Women, nearly ¾ of women incarcerated in Oklahoma state prisons reported being physically abused at some point in their lifetime

#### **OREGON**

- Between 1997 and 2003, 123 homicides occurred among Oregonians age 12 and older due to intimate partner violence
- 2,735 adult survivors of domestic violence and/or sexual assault were sheltered in emergency shelters, motels, and safe homes in 2007

#### **PENNSYLVANIA**

- 64 women were killed as a result of domestic violence in 2006
- 91,545 victims received services from 62 local programs between June 2006 and July 2007

#### **RHODE ISLAND**

- 2,246 victims were visibly injured as the result of domestic violence incidents in 2004
- In 2005, there were six domestic violence related homicides

#### **SOUTH CAROLINA**

- The South Carolina Attorney General has named domestic violence as the #1 crime problem in the state
- 35,894 victims of domestic violence in 2005

#### **SOUTH DAKOTA**

- Over 6,700 women reported being victims of domestic violence in 2004
- 14 homicides occurred as a result of domestic violence in 2007

#### **TENNESSEE**

- 66,619 domestic violence victims reported in 2004
- Due to limited funding, 2,609 women, 1,028 children and 192 men were unable to be sheltered between 2003 and 2004

#### **TEXAS**

- 187,811 incidents of family violence in 2005
- Six children were killed as a result of domestic violence in 2006

#### **UTAH**

- Domestic violence is one of the fastest growing and most serious violent crimes in Utah today
- In 2007, 18 individuals murdered were domestic violence related homicides

#### **VERMONT**

- 48 individuals reported that they were kidnapped by an intimate partner in 2006
- 40% of Vermont homicides were domestic violence related in 2006

#### **VIRGINIA**

- In 2005, there were 3,632 reported violent crimes against family and dating partners
- In 2006, 51,652 individuals in crisis situations contact Virginia domestic violence programs

#### **WASHINGTON**

- In 2006, there were 49,980 reported cases of domestic violence
- In 2006, 59 out of 195 homicides were a result of domestic violence

#### **WEST VIRGINIA**

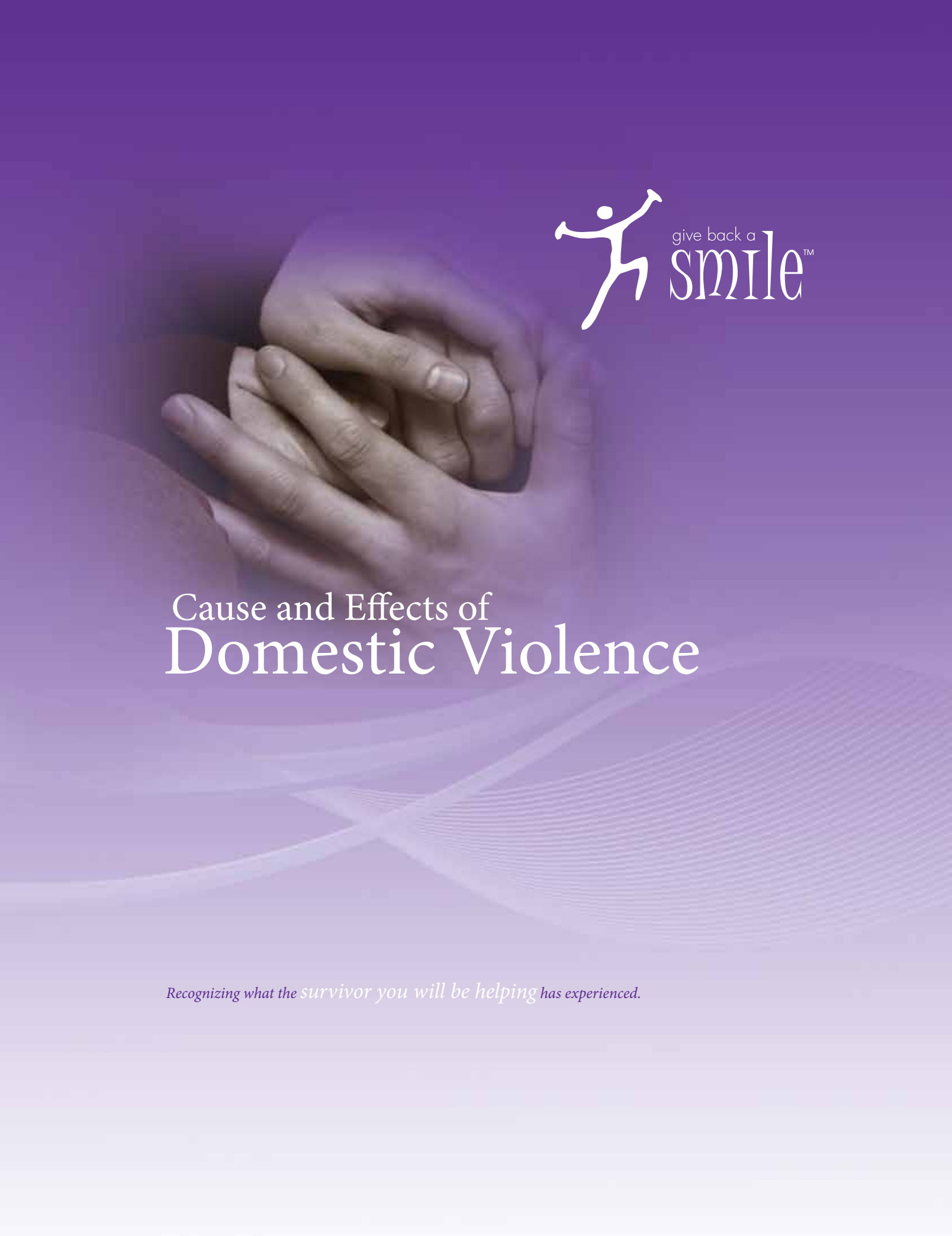
- 12,528 reported cases of domestic violence in 2006
- 37 homicides were a result of domestic violence in 2006

#### **WISCONSIN**

- In 2005, there were 26,323 reported cases of domestic violence
- Nine children were killed as a result of domestic violence in 2005

#### **WYOMING**

- 3,256 incidents of domestic violence reported in 2007
- In 2007, the majority of domestic violence victims were between the ages of 18 and 29



# Cause and Effects of Domestic Violence

*Recognizing what the survivor you will be helping has experienced.*

# Cause and Effects of Domestic Violence

*The following information will help you to recognize what the survivor you will be helping has experienced. It may provide insight to his or her world, shedding light on behaviors, past and present. Please review carefully.*

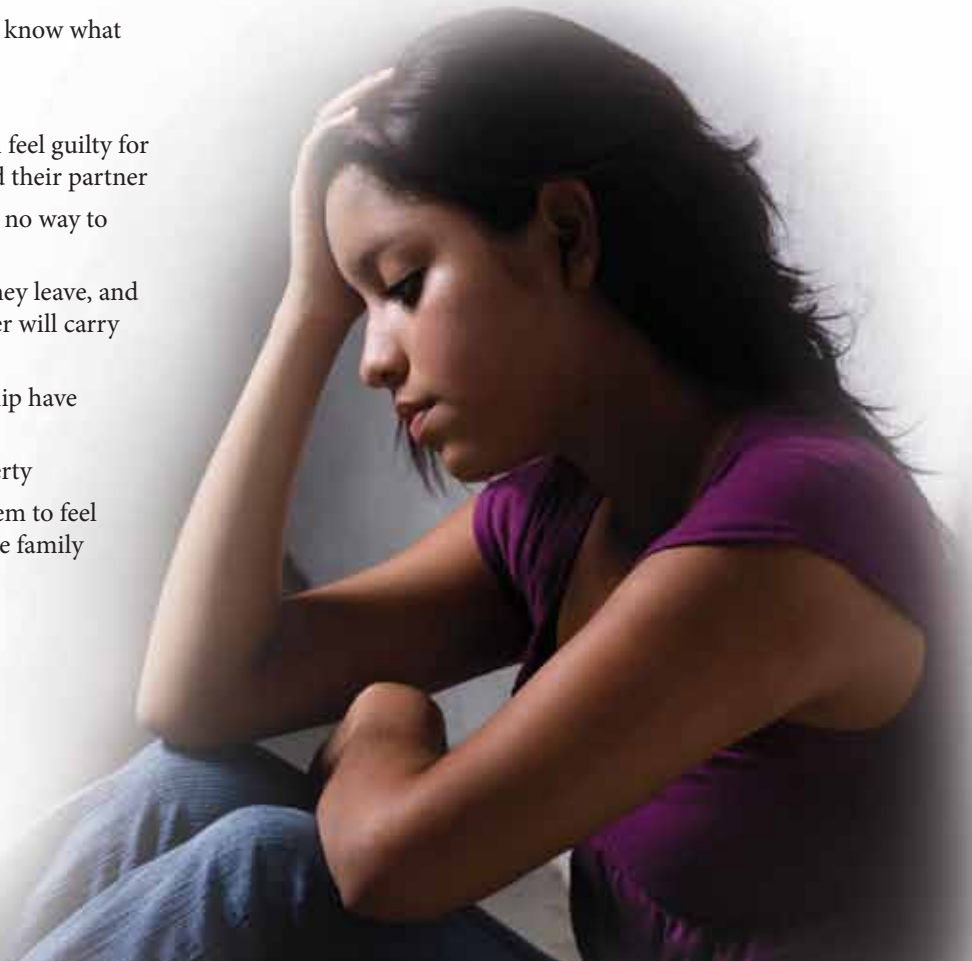
## Potential Long-Term Emotional and Behavioral Effects of Domestic Violence

- Flashbacks and nightmares may occur long after the abuse has ended
- Depression and suicidal tendencies
- Loss of hope for the future
- Low self-esteem
- Inability to trust others
- Anxiety
- Inability to concentrate

Source: [http://divorcesupport.about.com/od/abusiverelationships/p/effects\\_abuse.htm](http://divorcesupport.about.com/od/abusiverelationships/p/effects_abuse.htm)

## Victims Stay Because...

- They still harbor some hope and/or do not know what else to do
- The abuser has promised to change
- The abuser feels hurt and makes the victim feel guilty for leaving. They are supposed to stand behind their partner
- They have no money, no one to help them, no way to earn a living, and no place to go
- The abuser has threatened to kill them if they leave, and they have every reason to believe the abuser will carry out this threat
- In the past, attempts to leave the relationship have resulted in more severe violence
- The alternative may be loneliness and poverty
- Their strong religious beliefs may cause them to feel guilty to leave the marriage, or break up the family
- Of the children



# Cycle of Violence

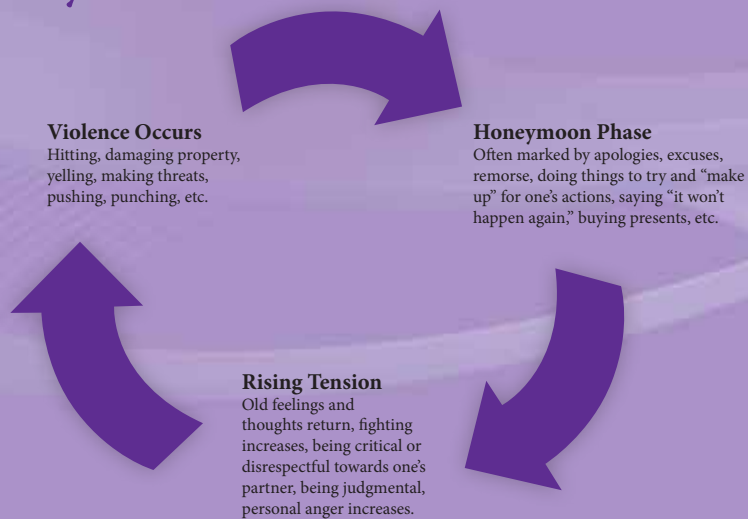


Image copied from: [http://www.saskatoonhealthregion.ca/your\\_health/images/cycle\\_of\\_violence.jpg](http://www.saskatoonhealthregion.ca/your_health/images/cycle_of_violence.jpg)

## Remember:

- Abuse is not random, it occurs within a system of behaviors designed to exert control
- Violence is not constant; there are three distinct phases in the cycle
- The three phases vary in time and frequency
- Violence increases in severity and frequency, if the cycle is not broken

## Abuser

### Tension Building

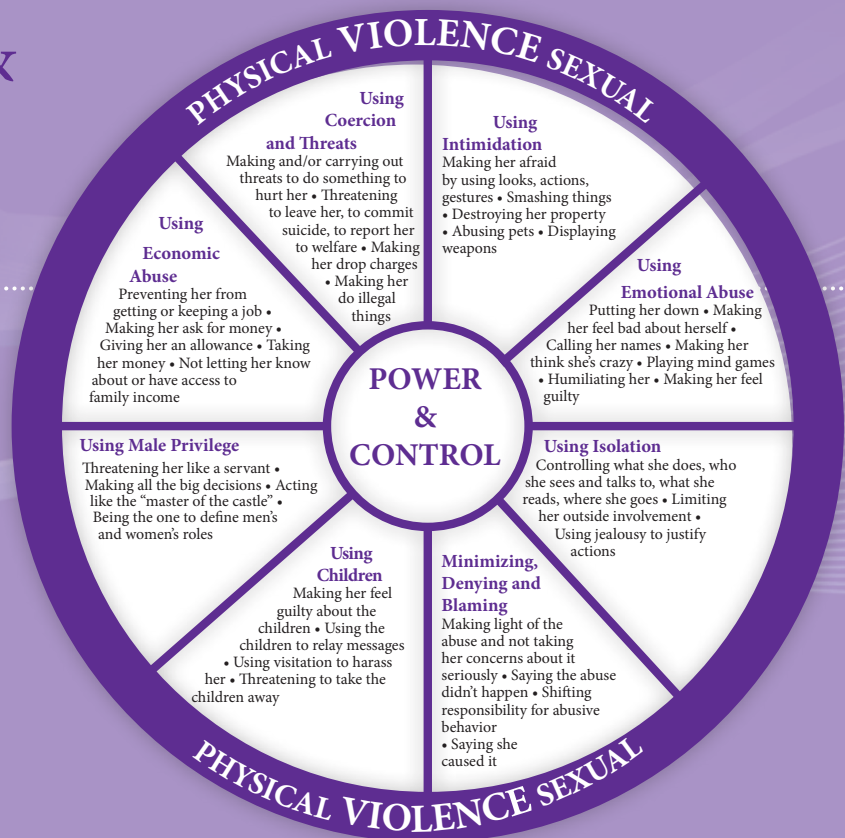
- Minor battering incidents occur including verbal and psychological abuse
- Abuser may be aware of own inappropriate behavior, but doesn't take responsibility
- Afraid that their partner will leave, jealousy and possessiveness increases with the hope that brutality will keep victim captive
- Frantic, more control. Abuser misinterprets partner's behavior, takes withdrawal as rejection
- Outside events can affect this stage
- Abuser feels uncontrollable

## Victim

### Tension Building

- Becomes nurturing, compliant, will stay out of the abuser's way
- Denies escalation of abuse and inevitability of serious incident
- Accepts the abuse. Believes that what they do can prevent the abuser's anger from escalating. They attempt to alter behavior as a way of providing safety
- Rationalizes abuse (everybody has marriage problems, etc.)
- Blames external factors, such as stress or alcohol
- Tension becomes unbearable. Stress-related illness is common. Victim may feel anxious, depressed, sleepless, fatigued, may over/under eat, or experience tension headaches

# The Power & Control Wheel



- Physical abuse never takes place in isolation
- Abusive behaviors can be constructed into a wheel
- Physical violence is part of a system of abusive behaviors, the purpose of which is to maintain power and control over the partner in the relationship
- At the heart of the wheel is power and control. This is the motivation behind the abuse to ensure that the batterer remains in control of how the partner thinks, feels and behaves
- Physical abuse is the behavior that most people see as "the problem." It is the element of abuse that is most easily identified and is often the only form of abuse that is illegal
- The wheel contains a variety of behaviors or tactics, which the abuser uses to gain control
- Not all forms of abuse are used in every relationship. The abuser may switch tactics often to keep the victim on the defensive
- When the victim learns to respond to one type of attack, the batterer may change strategies
- Eventually the struggle may become so exhausting that the victim begins to modify his or her behavior, giving up control, in order to avoid further abuse

## A NEW SMILE, A NEW OPPORTUNITY



by  
Ira M. Langstein, DDS  
White Plains, NY  
ira@westchesterdds.com

### INTRODUCTION

A smile, a person's ability to express a range of emotions with the structure and movement of the teeth and lips, can often determine how well a person can function in society. Each year, thousands of women are deprived of the ability to smile as a result of domestic violence that causes injury and disfigurement to the mouth and dentition.<sup>1</sup> The AACD's Give Back A Smile™ (GBAS) program has facilitated the repair of damaged smiles through a collaboration of dentists and laboratories that can make a true difference in a person's life.

---

*Each year, thousands of women are deprived of the ability to smile as a result of domestic violence that causes injury and disfigurement to the mouth and dentition.*

---

### PATIENT HISTORY

"Victoria" (not her real name) was referred to our office through the GBAS program in order to evaluate her dental needs (Fig 1). She was a victim of repeated violent acts, the worst of which involved being slashed with a broken bottle and absorbing a blow that avulsed her maxillary right lateral incisor. There are a variety of post-traumatic psychological sequelae following events such as these; in this case, I noted a quiet, defensive patient not willing to open up verbally or to explicitly display trust.

### CLINICAL FINDINGS AND TREATMENT PLAN

After suffering the series of traumatic injuries, Victoria immediately sought the help of a dentist, as the wait for eligibility in the GBAS program was several



Figure 1: Preoperative full-face view.

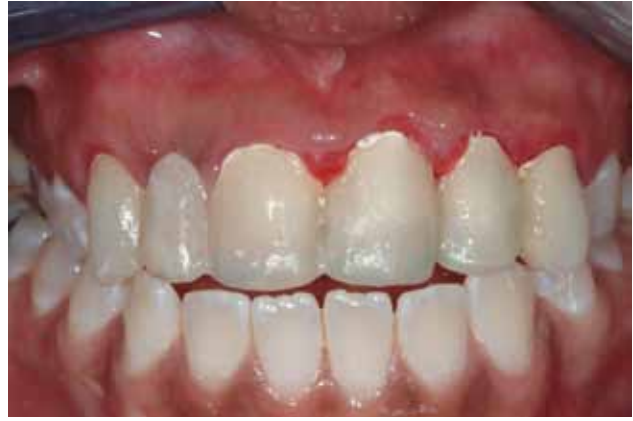

Figure 2: Retracted view.

months. As a result, she presented to our office in provisional crowns splinted on teeth ##6-11 (Fig 2). The marginal integrity of the provisional restorations was poor. There existed an associated high level of temperature sensitivity along with a severe inflammatory response in the gingival tissues. The poor quality of these restorations combined with the history of violent trauma to create emotional distress for the patient. Radiographic evaluation revealed multiple carious lesions, along with a failing endodontic lesion on #18. The pontic site at #7 was covered with a provisional pontic. General periodontal health was deemed adequate, and there were no complicating medical issues, soft tissue anomalies, or signs of oral cancer. An anterior open bite, which the patient said predated the dentistry, was noted.

The proposed treatment plan involved new ceramic restorations on ##6-11, with a three-unit bridge utilizing #6 and #8 as abutments. After a smile analysis was completed, it was decided to include no-preparation ceramic veneers on #5 and #12 to assist in minimizing negative space in the buccal corridors and

avoid the typical esthetic “drop-off” noted when ceramic restorations end at the maxillary cuspids.<sup>2</sup> The anterior open bite, which had been present since the permanent initially erupted, was to be maintained. Caries control in the form of direct resins was planned for the carious lesions, and #18 was marked for extraction and socket grafting for possible future implant placement.

### TREATMENT

One disadvantage that existed from the beginning of treatment was the existing over-preparation of #6 and ##8-11 (Fig 3). The excess removal of supporting dentin and proximity to pulpal tissue compelled us to advise the patient of the possibility of immediate or future endodontic treatment to any or all of these teeth. The preparations were minimally cleaned up to proper axial inclinations and a new provisional restoration was fabricated with Luxatemp shade A1 (Zenith Dental; Englewood, NJ) using a putty matrix developed from a pre-planned wax-up of the envisioned final restorations.<sup>3</sup> Substantial tissue healing was noted at the following

one-week interval (Fig 4). Impressions were taken using the double cord technique and a polyvinyl siloxane putty/wash system (Aqualil, Dentsply Caulk; Milford, DE) (Fig 5).<sup>4</sup> All impressions and casts were sent to the laboratory.

We partnered with Valley Dental Arts (Stillwater, MN), who generously donated their services for this case. Lava (3M ESPE; St. Paul, MN) copings were fabricated and returned for try-in.<sup>5</sup> After verifying the integrity of the copings' fit, an appropriate shade was selected (Fig 6). This shade was determined using the X-Rite (Grandville, MI) system, after the patient had completed a short course of whitening using a tray material. The restorations were cemented conventionally with Fijicem (GC America; Alsip, IL). No-preparation veneers were luted to #5 and #12 using 3M veneer cement translucent shade. All excess cement was trimmed with blades and any occlusal adjustments were polished using the Brasseler USA (Savannah, GA) porcelain polishing system (Fig 7).



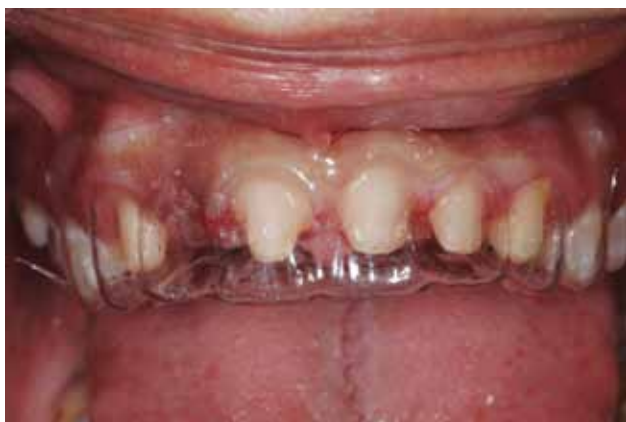

Figure 3: Reduction guide in place.

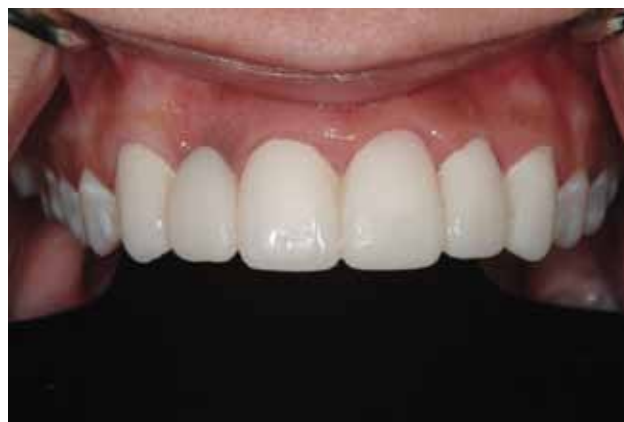

Figure 4: Provisional.

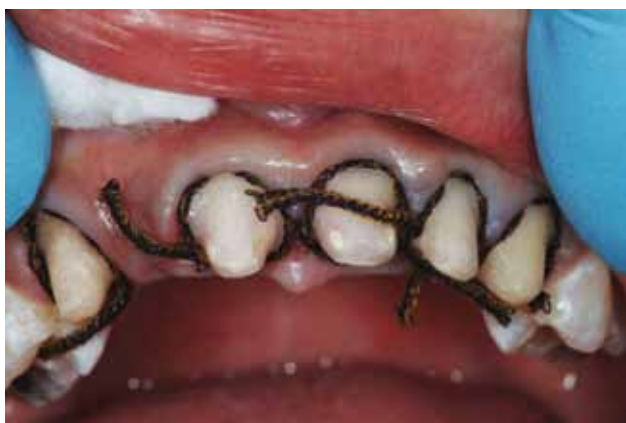

Figure 5: Double retraction cord technique.

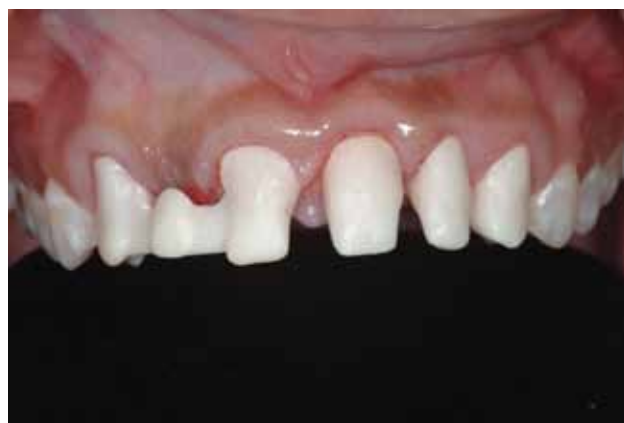

Figure 6: Try-in of Lava copings.

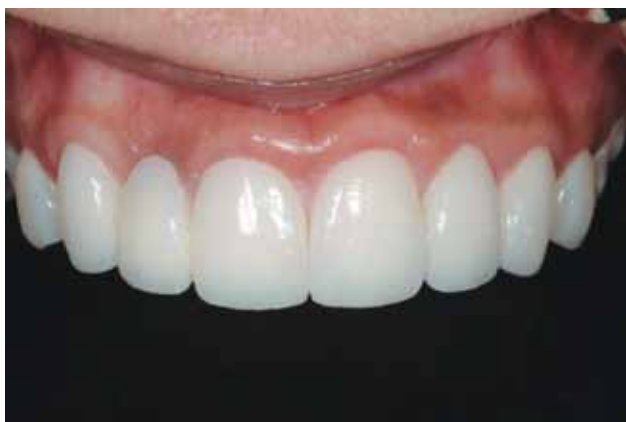

Figure 7: Final restorations, retracted view.



Figure 8: Final smile restoration.

## AFTERMATH

Victoria returned after two weeks for a postoperative inspection and photographs. At her visit, it was apparent that the restored smile had enhanced her self-esteem and served as a vital component of the long journey to rebuild her life (Fig 8). There was also a visible pride in other aspects of her appearance. She is now searching for a job in the area and is optimistic about her chances. The opportunity to create this level of positive change in someone's life provided extreme satisfaction for me, my staff, and our laboratory partners. As experienced firsthand, the AACD's Give Back A Smile program has provided the forum to change lives, one smile at a time.

## AACD Acknowledgment

*The American Academy of Cosmetic Dentistry recognizes Dr. Ira Langstein as a Give Back A Smile™ (GBAS) volunteer who has restored one GBAS survivor's smile.*

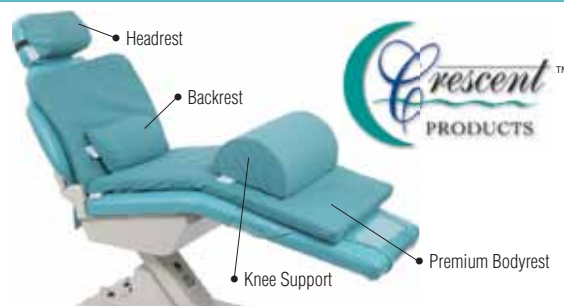## References

1. Love C, Gerbert B, Caspers N, Bronstone A, Perry D, Bird W. Dentists' attitude and behaviors regarding domestic violence: the need for an effective response. *JADA*. 2001;132(1):85-93.
2. Moore T, Southard KA, Casco JS, Qian F, Southard TE. Buccal corridors and smile esthetics. *Am J Orthod Dentofacial Orthop*. 2005;127(2):208-13.
3. Donovan TE, Cho GC. Diagnostic provisional restorations in restorative dentistry: the blueprint for success. *J Can Dental Assoc*. 1999;65:272-5.
4. Cloyd S, Puri S. Using the double cord technique for making crown impressions. *Dent Today*. 1999;18(1):54-9.

5. Quinn JB, Cheng D, Rusin R, Suttor D. Fractographic analysis and material properties of a dental zirconia. In: Lava all-ceramic system for Lava crowns and bridges, a collection of scientific results, 3M Espe. Minneapolis, MN: 3M Espe; 2005.



## The Ultimate in Patient Comfort



### Crescent Headrest, Backrest, Knee Support and Bodyrest

Bring your patients comfort with memory foam cushions for their neck, back and entire body. The Knee Support will provide your patients with pressure relief in the lower back and hips.

— Call 1.800.989.8085 To Order! —



### Isn't it time to WOW your patients?

"We bought your product for one of our chairs that we used for longer procedures. We have spent thousands of dollars on patient comfort items from flat-screen TVs to warm towels to pamper our patients while they are in our office. Most amazingly, this relatively small addition was noticed by every patient, and they invariably verbalized their satisfaction and their improved comfort in our chair. We have since purchased a set for every chair and we enjoy hearing our patients thanking us for their comfort. I can definitely say it has the biggest bang for patient comfort dollars in a dental office."

Parsa T. Zadeh, DDS, FAGD, FICDI  
Beverly Hills Center for Reconstructive & Cosmetic Dentistry

[www.crescentproducts.com/dental.htm](http://www.crescentproducts.com/dental.htm)

What is the difference between ordinary...  
and Extraordinary?

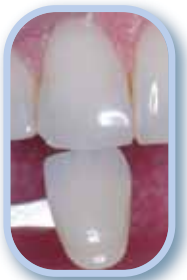# Renamel® Microfill™



## What Makes Renamel Microfill Extraordinary?

- **MORE NATURAL**  
Replicates enamel better than any other material
- **EASIER TO WORK WITH**  
Incredible handling — material spreads like butter and does not slump
- **BETTER POLISH**  
Highest polish of all composites and will retain this polish long-term
- **LONGER LASTING RESULTS**  
Amazing color stability
- **RATED #1 FOR OVER 15 YEARS**  
Renamel Microfill is the highest-rated composite in dentistry. This 5-star material has received “Product of the Year” award a record three times from Reality.

### Incredible Color Stability



22-1/2 years later


Look at the perfect color match and highly polished surface.

### Polishes Like Glass

Renamel® Microfill™



Leading Nanofill Composite



The SEM image of Renamel Microfill (left) and a leading nanofill (right), both at the same 1,000x surface magnification, show Renamel Microfill attains a remarkably smooth polish.

Surface roughness of nano and microfill resin-based composites. A. Catelan, P.H. dos Santos, A.K.B. Bedran-Russo. J Dent Res 88 (spec issue B): 592, 2009. ([www.dentalresearch.org](http://www.dentalresearch.org))

*“Renamel has won me over... completely.*

*Superb sculptability, and the most awesome finish!!*

*And, blending at the margins... simply invisible.”*

– Dr. Rumpa Wig

**COSMEDENT®**  
*Spreading Smiles™*

to order Renamel Microfill  
**800-621-6729**  
[WWW.COSMEDENT.COM](http://WWW.COSMEDENT.COM)

TRY OUR 30 DAY  
RISK-FREE GUARANTEE.

# ACCREDITATION ESSENTIALS

## IN THIS SECTION:

---

INTRODUCTION TO ACCREDITATION ESSENTIALS ♦ BY <i>JAMES H. HASTINGS, DDS, AAACD</i> .....	93
ACCREDITATION CLINICAL CASE REPORTS—ACCREDITATION CASE TYPES IV & III: ANTERIOR DIRECT RESIN ♦ BY <i>JEFFREY S. KERBS, DDS</i> .....	94
ORIGINS OF ACCREDITATION: INTERVIEW WITH DR. JEFF MORLEY ♦ BY <i>JAMES H. HASTINGS, DDS, AAACD</i> .....	104

## INTRODUCTION TO ACCREDITATION ESSENTIALS



by James H. Hastings, DDS  
AACD Accredited Member  
(AAACD)  
Washington, IA  
jhhdds@yahoo.com

*"The quality of a person's life is in direct proportion to their commitment to excellence, regardless of their chosen field of endeavor."—Vince Lombardi*

Football coach Vince Lombardi has been called the most motivational coach of the 20th century. His win/loss record and his ability to get more from his players than they thought possible are legendary. No one can fault the results that Lombardi obtained on the field or in the development of those who were privileged to play for him. He was committed to excellence.

This section of the Journal has often profiled two successful Accreditation cases by two different doctors or laboratory technicians. In this issue, the editors found that one dentist had two cases that were executed in excellent fashion. Dr. Jeffrey Kerbs of Escondido, California, submitted a Case Type III and a Case Type IV for evaluation. Both cases were deemed to be of the highest quality by the examiners, with both being awarded very low

scores (a score of zero is the best; minus seven is the highest that can pass).

In conversation with Dr. Kerbs, I found him to be humble and obviously dedicated to excellence in his dentistry. He took a multitude of steps to complete his Case Type III (tooth replacement), whereas lesser operators might have given up. Dr. Kerbs is to be complimented for his perseverance and his understanding that some sacrifice is essential to the process; and moreover, that the knowledge gained by perseverance is knowledge never lost.

Dr. Kerbs' eventual outcome in both cases was exceptional. It was his determination to succeed that propelled him to complete the tooth replacement case. It is this kind of person who has the heart of a student and also that of a teacher. As with all who undertake the journey to earn the

AACD credential, the major beneficiaries are the patients whom we are privileged to treat. Dr. Kerbs' commitment to excellence stands as an example to us all.

Also in this section of the Journal, we celebrate the Academy's 25th anniversary. For this milestone, we were privileged to interview one of the AACD's founding fathers, Dr. Jeff Morley, to gain a sense of the history behind Accreditation. In this interview, Dr. Morley gives us some interesting insight into how and why the credential in cosmetic dentistry came into being. In future issues you will see interviews with Dr. Jimmy Eubank and Dr. Larry Addleson. These fine clinicians helped to reshape the Accreditation process into what it is today.



## ACCREDITATION CLINICAL CASE REPORTS— CASE TYPE IV: ANTERIOR DIRECT RESIN; AND CASE TYPE III: TOOTH REPLACEMENT



by Jeffrey S. Kerbs, DDS  
Escondido, CA  
[www.drjkerbs.com](http://www.drjkerbs.com)

### INTRODUCTION

Successfully treating the broad range of esthetic challenges encountered in comprehensive care requires a wide range of knowledge and mastery of many skills. The AACD Accreditation process promotes and facilitates acquiring that knowledge and developing those skills.


The examples discussed here pertain to Accreditation Case Type IV and Case Type III. Two patients needed restoration of tooth #8 due to different modes of failure. These situations required two very different kinds of restoration, each with its own necessary set of skills and knowledge to successfully complete the treatment. One patient had a modest chip on the mesial corner of a virgin tooth (Figs 1a-1c). The other patient experienced the catastrophic failure of a previously restored tooth because of a vertically fractured root (see patient 2 on page 99).

---

*The AACD Accreditation process promotes and facilitates acquiring that knowledge and developing those skills.*

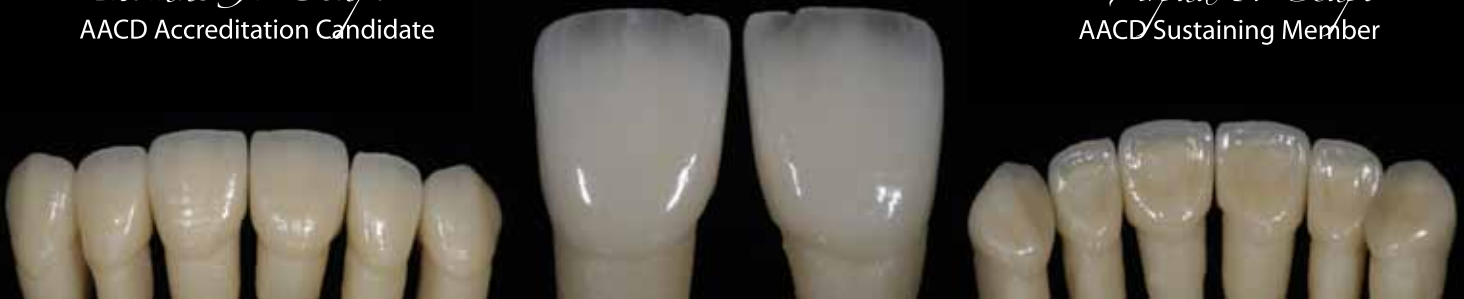---

Although the steps taken to restore an esthetic case can vary greatly, as demonstrated by these two cases, the first two steps apply to all Accreditation case types. Every case must be thoroughly photographed for documentation and study. The AACD series of 12 photographs is an excellent communication and learning tool. Shade selection is best made while the operator's eyes are rested and the natural teeth are still hydrated. If bleaching has been done, the shade should be taken at least a week after bleaching was stopped to ensure that the teeth have settled to a stable shade.



*Thomas J. Csapo*  
AACD Accreditation Candidate

*Arpad F. Csapo*  
AACD Sustaining Member



Individualized Doctor Preferences  
AACD Smile Design Principles  
Natural Functional Anatomy  
Pankey/Dawson Occlusion  
Multi-layering Technique  
Continuing Education  
Beautiful Contour  
Case Diagnostics  
Consistency  
Harmony  
Vitality  
Details

**For more information please call 800.750.6223 or visit us online at: [www.csapodentalarts.com](http://www.csapodentalarts.com)**

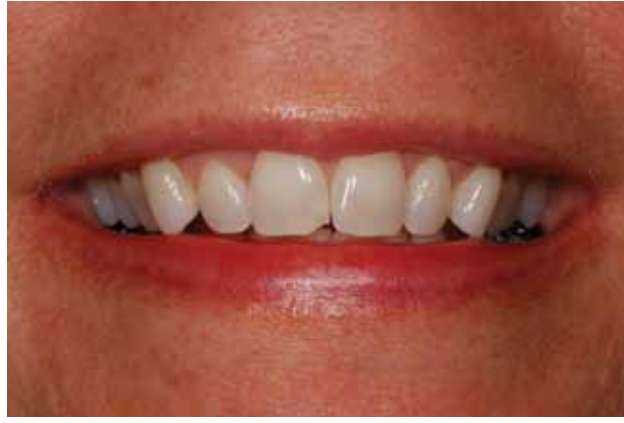

Figure 1a

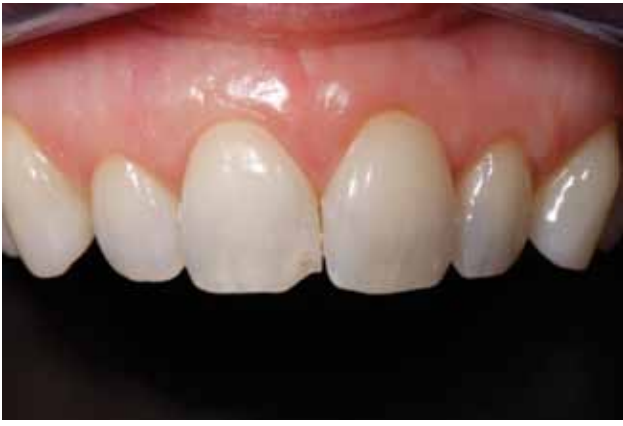

Figure 1b

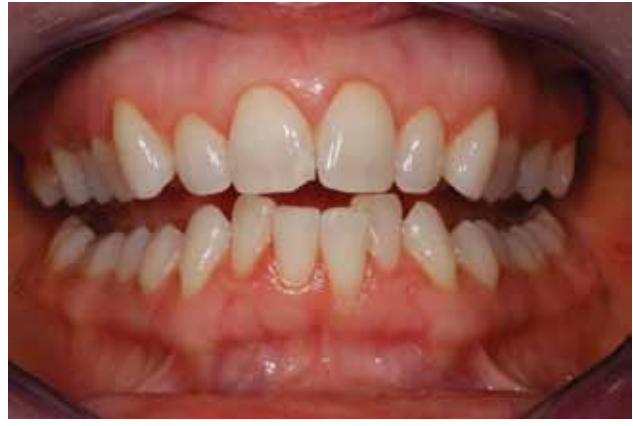

Figure 1c

Figures 1a-1c: Case Type IV, preoperative; fractured mesial incisal corner, #8.

As treatment of this Case Type IV was less complex, with fewer steps, it is reviewed first. The more involved Case Type III follows the information about Case Type IV.

## CASE TYPE IV

### RESIN SYSTEM

The resin system used for this case was Filtek Supreme Plus (3M ESPE; St. Paul, MN). The system is referenced to the standard Vita

Shade Guide (Vident; Brea, CA), so holding the Vita shade tabs up to the teeth being matched will help with initial shade selections. The basic system has three levels of opacity/translucency. The dentin shade, which is the most opaque, is used to mask the fracture line and create the mammelon of the correct chroma. The body shade, which has moderate opacity, is used to blend and add depth without appreciably lowering value. The enamel shade is the

most translucent. It is used in areas where maximum translucency and lower value are desired; for example, along the incisal edge and around the mammelons. This adds depth and accentuates the underlying dentin anatomy. It also creates a "chameleon" effect, producing invisible margins as it ties the restoration into the main body of the tooth.

Although the composite shades match the Vita shades fairly closely there is some variance. This—along



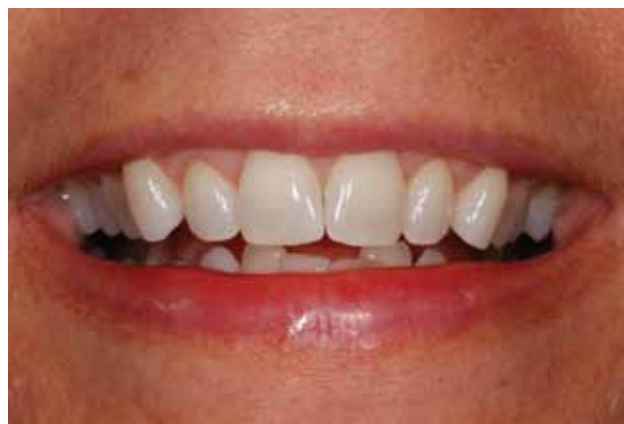

Figure 2a

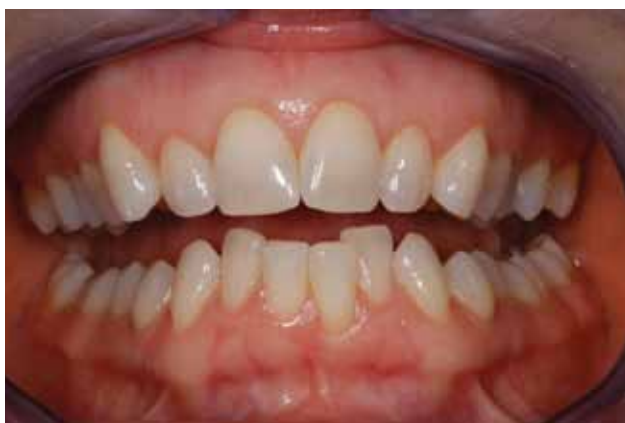

Figure 2b

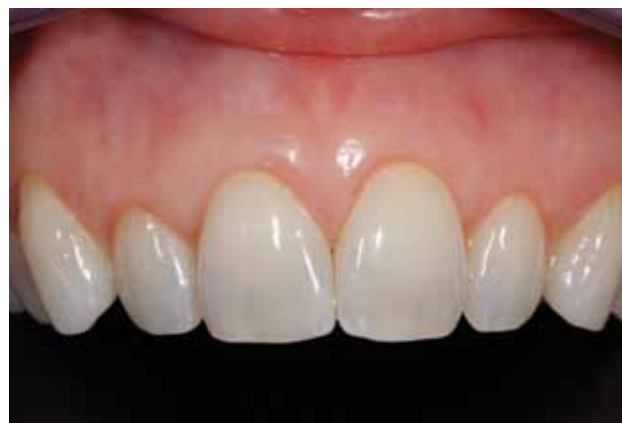

Figure 2c

Figures 2a-2c: Case Type IV; final restoration, 1:2 smile, and 1:1 retracted views.

with the three levels of opacity/translucency—makes it very helpful to try the selected shades directly on the tooth quickly without bonding, to verify that it achieves the desired effect. If not, the composite can be popped off and a revised combination can be quickly tried while the teeth are still hydrated.

#### SHADE CONFIRMATION

The most important shade to confirm is the dentin shade used to mask the fracture line. If the fracture

line is still visible after the placement of the dentin shade, placing more translucent shades over the top will not make it disappear.<sup>1,2</sup> Another principle to consider when trying to achieve the desired effect with composite is that the more opaque, the less depth, and the higher the value, the more translucent gives more depth and lowers value. In this case, we found that a better shade match was achieved by eliminating A1B, then skipping from A1D to A1E, and then using

B1B as the accent. This gave a more subtle and natural appearance than the originally chosen WB. (The W shade in the Filtek system is roughly equivalent to a bleach-white shade.)

#### TREATMENT

As the fracture was predominantly in enamel, there was no need for anesthetic. The area was isolated with Isolite (Isolite Systems; Santa Barbara, CA) and cotton rolls. The rough edges were smoothed and long “infinite” bevels were placed



Figure 3: Case Type IV; final restoration, portrait view.

on the facial surface with a fine diamond.<sup>1-3</sup> Teflon tape (plumber's tape) was wrapped around the mesial of #9, and then #8 was generously etched with phosphoric acid for 30 seconds. Tooth #8 was thoroughly rinsed and dried, then brushed with E-bond unfilled resin (Danville Materials; San Ramon, CA), which was aggressively air-thinned, then cured for 20 seconds. A thin lingual wall of Filtek Supreme WE was placed first, using the operator's finger as a matrix. This thin wall of enamel composite establishes the incisal edge for reference and acts like a canvas on which to sculpt the mammelons, translucent zone, and halo.<sup>1,2</sup> Next, A1D was used to mask the fracture line and carried just short of the incisal edge to create the mammelon effect.

A small dab of B1B was placed on the mesial-incisal corner, to create a highlighted, slightly more opaque area to mimic the mesial-incisal corner of #9. Then, a layer of A1E was placed over the entire facial of the restoration, extending a little beyond all bevels and blending into the incisal edge, to bring the restoration to full contour. Each layer was cured for 10 seconds as it was placed,

and the final layer was cured for 30 seconds. The plumber's tape was removed and contours were refined with an extra-fine diamond and extra-fine strip (GC America; Alsip, IL). High polish was achieved with Soflex (3M ESPE) fine and extra-fine discs; and, finally, with Flexi-buff discs with Enamelize (Cosmedent; Chicago, IL) (Figs 2a-2c).

### CASE TYPE III

Case Type III, replacement of an anterior tooth with an implant, requires more steps and thus a greater range of skills: Optimum placement of the implant; selection and management of the abutment; tissue management; and, finally, laboratory communication for the creation of an esthetic crown.

---

*Each case has its challenges, but persistence in achieving an exceptional esthetic result cannot help but make one a better clinician.*

---

### RECORD TAKING

To document the patient's original condition, photographs and upper and lower impressions were

taken and two sets of models were made (Figs 4a-4c). One set of models was sent to the laboratory with shade selection for fabrication of an immediate stayplate replacing #8; the other for study and recording of the original condition.

When the stayplate was ready, the patient went to the oral surgeon for the removal of #8, the immediate placement of an implant (Astra Tech; Waltham, MA), and delivery of the stayplate.

### PLACING AN ESTHETIC ANTERIOR IMPLANT

Some basic guidelines for placement of an esthetic anterior implant are as follows:

- place the implant at bone level, for maximum flexibility and to eliminate the possible gingival gray-out due to the implant
- there should be a minimum of 1.5 mm between implant and adjacent teeth, ideally having the abutment screw exiting through the cingulum or just lingual to the incisal edge
- be aware that the papillae will extend 4.5 mm above the interproximal bone height of

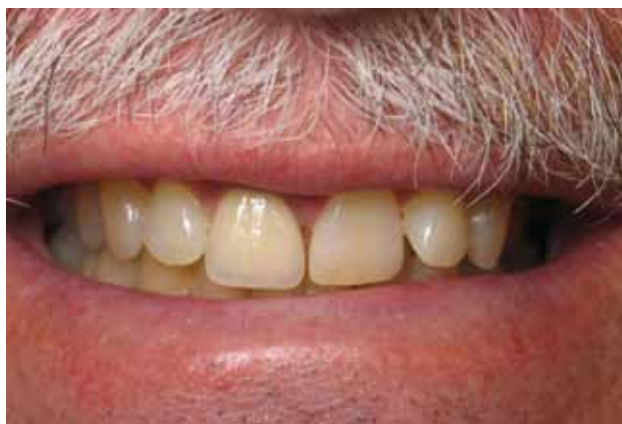

Figure 4a

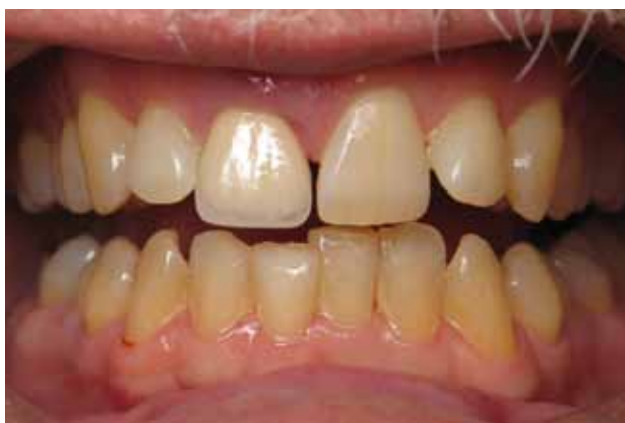

Figure 4b

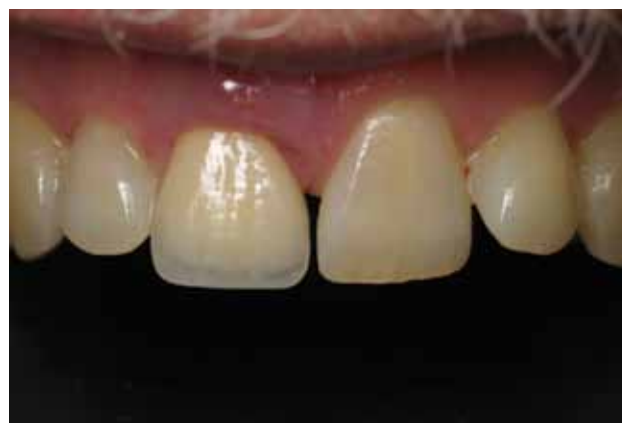

Figure 4c

Figures 4a-4c: Case Type III, preoperative; failing maxillary right central incisor due to vertical root fracture.

the adjacent teeth; this will help plan the crown contours so that there will be less chance of interproximal dark triangles once the tissue is fully matured.<sup>4,5</sup>

The oral surgeon confirmed integration of the implant a little over three months after its placement. A healing abutment was placed and the patient returned to the office to have the stayplate adjusted to fit over it.

#### SHADE MATCHING

Approximately three weeks later, a fixture-level pick-up impression was taken and the tissue height was measured before ordering the desired zirconia abutment (Astra Tech). Numerous photographs were taken with several shade tabs and accent color tabs to help the laboratory identify the various shading and accents needed to match #9<sup>6</sup> (Figs 5a & 5b; Fig 6). Instructions were given to match the emergence

profile of #9 while closing the diastema as much as possible.

#### TRY-IN APPOINTMENT

At the try-in appointment three weeks later, the zirconium abutment was placed and the crown tried in. Upon evaluating the try-in, there were two obvious deficiencies: First, the shading was off, so photographs from different angles were taken with the crown in place (Figs 7a & 7b). Second, the emergence profile was deficient facial-

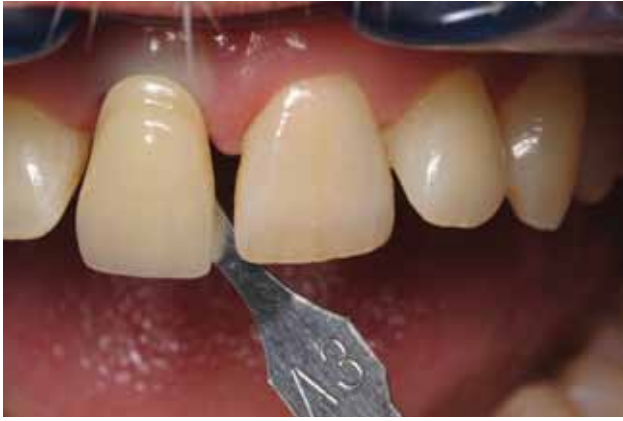

Figure 5a

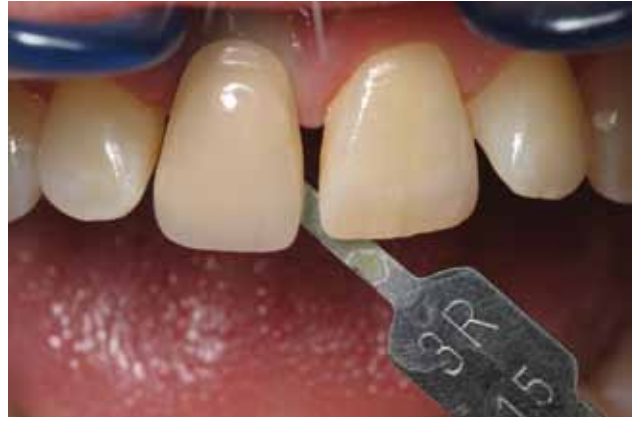

Figure 5b

Figures 5a & 5b: Case Type III; use of various shade tabs for laboratory communication.

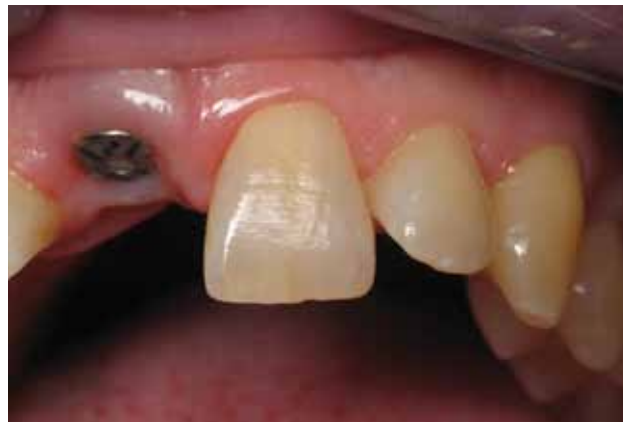

Figure 6: Case Type III; example of surface texture for laboratory communication.

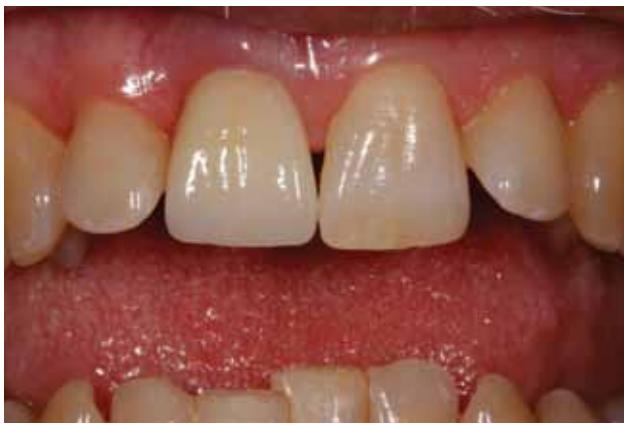

Figure 7a

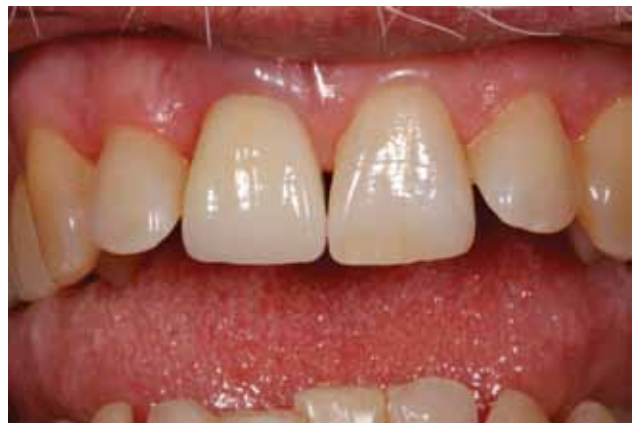

Figure 7b

Figures 7a & 7b: Case Type III; initial try-in shows imperfect shade match and contour.

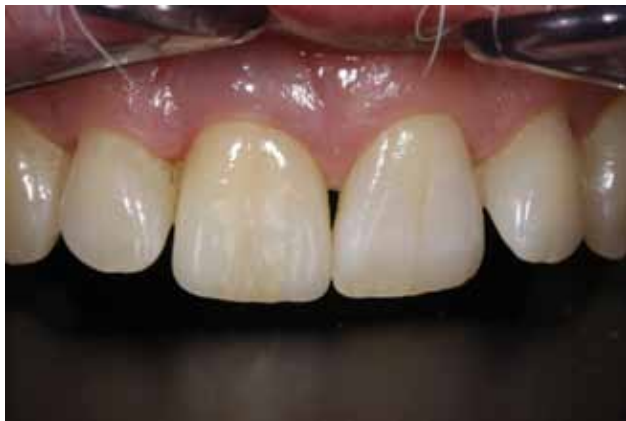

Figure 8a

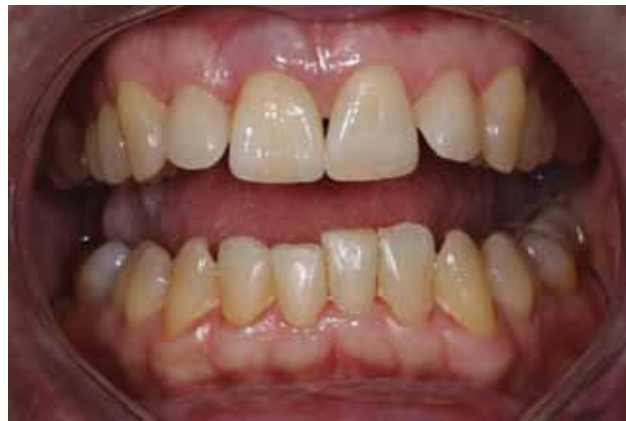

Figure 8b

Figures 8a & 8b: Case Type III; second try-in shows good shade match but incorrect contour.

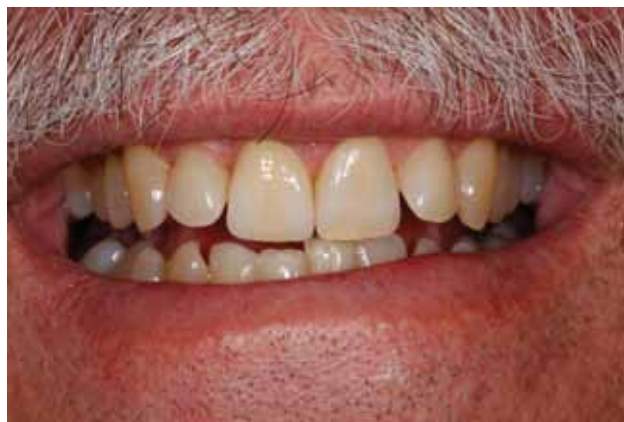

Figure 9a

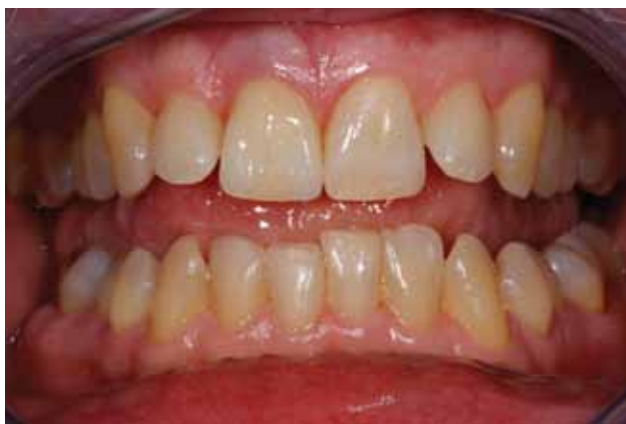

Figure 9b

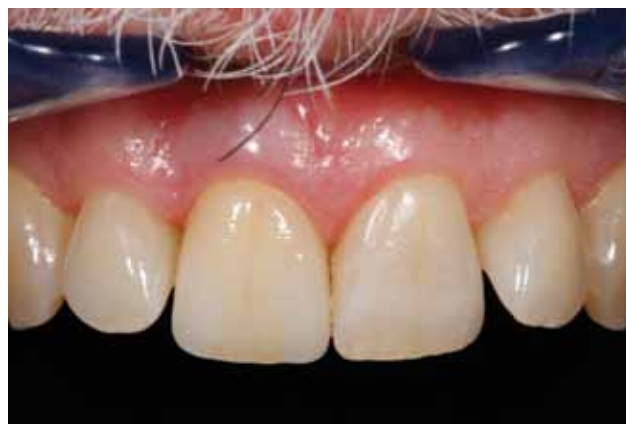

Figure 9c

Figure 9a-9c: Case Type III, postoperative; final restoration accepted and cemented.



Figure 10: Case Type III; postoperative portrait.

lingually and apically. On closer inspection, it was discovered that the margin on the zirconium abutment was not placed apically enough to allow for development of the proper emergence profile.

An approximate measurement of how much the margin needed to be moved apically was made. The abutment was then placed on the model, marked accordingly, then prepared to the mark. Once the desired placement of the margin was verified in the mouth, the zirconium abutment was placed permanently, tightening it down to the recommended torque setting. A custom provisional crown was fabricated, adding and sculpting composite, until the desired emergence profile and contour were achieved.<sup>7</sup>

#### PROVISIONAL

The custom provisional crown was then cemented for two weeks to allow the gingival tissue to adapt to the new contours and become stable. At the next appointment, the contours and tissue position were verified; then an impression of the provisional was taken so the laboratory could have an exact model of

what was desired. The provisional was then removed, and an impression of the abutment was taken. The custom provisional crown was placed back in the patient's mouth. Photographs, a model of the provisional, and the impression of the abutment were sent to the laboratory with instructions.

---

*Completing these restorative tasks at Accreditation level is challenging, but very motivational in attaining the necessary knowledge and skills.*

---

#### FINALIZATION

At the next try-in, it was noted that the emergence profile and contours had been faithfully reproduced. In order to reduce the diastema and minimize the gingival dark triangle, the shape of #8 had been made more rectangular than the triangularly shaped #9 (Figs 8a & 8b).

To make #9 match the shape of #8 and to further reduce the gingival dark triangle, the gingival aspect of the mesial of #9 was recontoured with a ND:YAG laser and the mesial of #9 was recontoured by bonding with Filtek Supreme A2B. The

restoration now "looked like it belonged."

The crown (Empress, Ivoclar Vivadent; Amherst, NY) was cemented with Panavia FTC (Kuraray America; New York, NY) (Figs 9a-9c; Fig 10).

#### SUMMARY

Completing these restorative tasks at Accreditation level is challenging, but very motivational in attaining the necessary knowledge and skills. These are ideally obtained through appropriate continuing educational reading, lectures, hands-on courses, and mentoring from AACD Accredited Members. Sometimes, however, learning is achieved the hard way, through trial and error while performing the treatment, as occurred in this Case Type III treatment. Initially, an attempt was made to have the laboratory prepare the abutment and contour the crown to achieve the desired emergence profile. While theoretically possible, the operator discovered that a more predictable method was to personally prepare the abutment and fabricate a custom provisional that established the desired emergence profile


and contours. This more precise information can then be given to the laboratory for duplication without the guesswork.

Each case has its challenges, but persistence in achieving an exceptional esthetic result cannot help but make one a better clinician. This striving for exceptional outcomes motivates continued searching for more predictable and efficient methods of treatment, ultimately raising the level of dental care as a whole. The AACD Accreditation process has

been invaluable in stimulating and encouraging this growth.

#### References

1. Fahl N. Mastering anterior composite restorations: a direct approach to dental artistry. 22nd AACD Annual Scientific Session; May 16; San Diego, CA. 2006.
2. Weston J. Direct free-hand bonding: creating esthetic success for Accreditation cases. 22nd AACD Annual Scientific Session; May 18; San Diego, CA. 2006.
3. Willhite C. Freehand composite bonding: techniques for Accreditation Case Types IV & V. 21st AACD Annual Scientific Session; Apr 21; Nashville, TN. 2005.
4. Spear F. The use of implants and ovate pontics in the esthetic zone. *Compendium*. 2008;29:72-80.
5. Kao R, Fagen M, Cate G. Thick vs. thin gingival biotypes: a key determinant in treatment planning for dental implants. *J Cal Dent Assoc*. 2008;36(3)193-98.
6. Aiba N. Dentscape: using dental photography to optimize esthetics. *JCD*. 2008;23(4)70-8.
7. Martel V. A multipronged approach to optimizing anterior implant esthetics. *Compendium*. 2008;29:414-20.

Get In the  
**Zone**

As a practice development strategist, Rhonda gets you where you envision to be, "in the zone of excellence".

**Clinically • Managerially • Operationally • Financially**

*"Rhonda transformed our lives not just our practice."*  
– Drs. Steve Wilkerson & Chad Fussell

*"Rhonda has increased our capacity to lead, our clinical skills, & team development to the extent we are ready to engage and achieve our accreditation dream."*  
– Drs. Victoria Callicutt & Amy Dayries

**RHONDA MULLINS**  
DENTAL CONSULTING

**770.841.5721**  
[www.RhondaMullins.com](http://www.RhondaMullins.com)  
Email [Rhonda@RhondaMullins.com](mailto:Rhonda@RhondaMullins.com)

## ORIGINS OF ACCREDITATION: INTERVIEW WITH DR. JEFF MORLEY

INTERVIEW CONDUCTED BY DR. JAMES HASTINGS



*by* James H. Hastings, DDS  
AACD Accredited Member  
(AAACD)  
Washington, IA  
jhhdds@yahoo.com

Jeff Morley, DDS  
AACD Accredited Member  
(AAACD)  
AACD Co-Founder  
San Francisco, CA  
www.jeffmorley.com

**JH:** *Dr. Morley, you have been very active in dentistry for many years. As co-founder of the AACD along with Dr. Jack Kammer, can you give a synopsis on how the AACD started?*

**JM:** From my perspective, it began in Spring 1982 when Dr. Kammer and I became acquainted. A writer for the *Wall Street Journal (WSJ)* came to me as a new patient. She decided not to opt for treatment, but became interested in writing an article about my cosmetic dental practice. In June 1982 the article was published on the front page of the *WSJ*. To my surprise, calls and letters poured in from around the world—from patients, laboratories, dentists, and others who had an interest, product, or idea sparked by the concept of cosmetic dentistry. One of those callers was Dr. Jack Kammer of Madison, Wisconsin. He asked whether I would be interested in starting a cosmetic dentistry organization. As he had already started the American Academy of Dental Group Practice, he had experience in this type of endeavor. I agreed to help and we corresponded, exchanging various ideas as to what a cosmetic dentistry academy should be.

---

*In the beginning there was no Accreditation model to follow.*

---

Our first meeting was scheduled for 1983; Dr. Kammer asked if I would speak about bonding and said Dr. Bill Strupp from Clearwater, Florida, would also speak. Unfortunately, that first meeting never took place, due to lack of interest. Dr. Kammer placed a small ad in *Dental Products Report (DPR)* about our founding meeting but, again, there wasn't much response. At that point, I thought the idea had failed, but it hadn't. The following year, Dr. Kammer asked if I was up for another try...and this time it

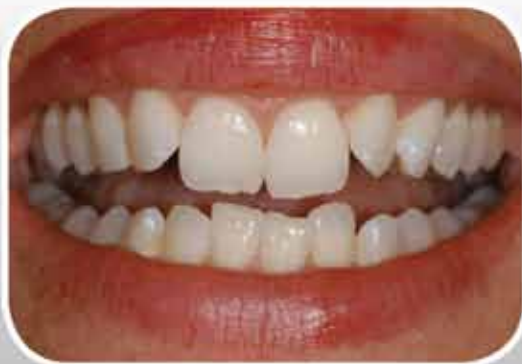

*There is a direct correlation between cosmetic imaging and case acceptance...*

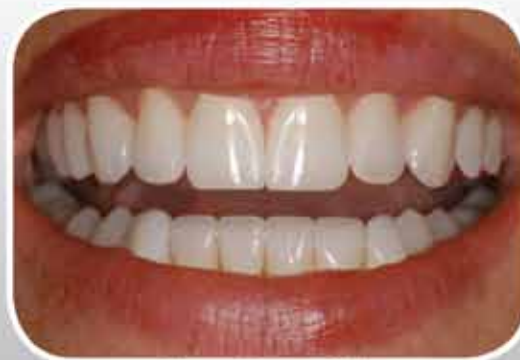

## **Are you imaging?**

**Image the full face, 1:2 smile or 1:2 lateral smile with our proprietary library,  
OR customize the library with your own completed cases!**



**pre-op**



**imaging with  
Envision a Smile**



*For a free on-line demonstration from your own photograph, visit us at*

[www.EnvisionASmile.com](http://www.EnvisionASmile.com)

**Financing available.**  
**Ask us about our lab partners who  
will make your payments for you!**

worked—Dr. Kammer placed another small ad in *DPR* and 60 dentists registered.

The meeting was held at the MGM Grand Hotel in Las Vegas, in December 1984. On the first day, Dr. Strupp spoke about his amazing crown and bridge techniques. On the second day, I discussed how to veneer front teeth with composite and about other cosmetic treatment options available through bonding. Thus, the AACD was born.

**JH:** *Tell us about the early years of the Academy and its first meetings.*

**JM:** It was at that Las Vegas meeting that Dr. Kammer and I first met in person. The lectures went well. Dr. Kammer was elected president; and I, vice president.

That first meeting involved an interesting group of individuals. Dr. Kammer likes to tell the story of the psychologist dentist who didn't like the name "American Academy of Cosmetic Dentistry." My favorite story is about how I was approached by Dr. John Kanca, who offered a private showing of his slide presentation on the results of bond strength experiments that he had been conducting in his garage! Ultimately, that is where we all met Drs. Paul Landman, George Freedman, Michael Miller, Sid Markowitz, John Derango, John Reddick, and others for the first time.

In 1985 two meetings were scheduled: One in Chicago,

the other in Scottsdale. The idea of Accreditation was born at the Scottsdale meeting. Since Dr. Kammer was unable to attend, I served as acting president. Due to Dr. Michael Miller's special interest in our discussions on developing a credential in cosmetic dentistry, he was elected the first chair of Accreditation.

---

*Our vision was to create a fair, objective, and standardized examination process—exactly what it is today.*

---

In the beginning, there was no Accreditation model to follow. Other professional specialty organizations had examinations, but there was nothing for cosmetic dentistry. As we had no access to those other examinations, we had to start from scratch. The challenge of something new provided the creative "juice" needed to get Accreditation off the ground.

**JH:** *How were the first examinations structured?*

**JM:** Approximately 12 members brought cases to the 1986 Toronto meeting. It wasn't really an examination, but rather a brainstorming session about what criteria we should be examining.

We viewed each other's work and discussed it; this gave us a better idea about how to organize the protocol. There were no criteria at that time. Dentin bonding did not exist and bonded porcelain was

in its infancy. Most cosmetic dentistry then consisted of bonded composite, crowns and bridges with porcelain fused to metal, and removable prosthodontics. There were photographs, slides, and Polaroid photography, but no standardization of views. Some dentists showed patients' faces and some did not. Photography was poor as well. In sharp contrast, today's examination process is highly organized and standardized.

**JH:** *What did you learn from that first Accreditation process in 1986?*

**JM:** It is difficult to imagine any working context, since we were truly grasping at ideas from thin air. Our vision was to create a fair, objective, and standardized examination process—exactly what it is today. In my opinion, to judge the beginnings of Accreditation by today's standards would be inherently unfair. In 1986 there was no standard or anything definable. At that time porcelain veneers were very experimental, bleaching was arcane, and there was no bonding to dentin. As the process developed, we had to determine which cases were good to show, which photographic views to use, and what constituted good cosmetic dentistry and photography. The idea of Accreditation as a true credential was developed several years later.

**JH:** *You were an examiner from 1987 until the early 1990s. How did the credentialing*

*process evolve during the Academy's first 10 years?*

JM: The five case types used today began taking form in 1987. Drs. Paul Landman, John Kanca, Michael Miller, and I served as the examiners.

For many years, candidates needed to present all five cases at once and had to be present to discuss the cases they treated. The examiners discussed the cases with the candidate in the room. Those original examinations were a learning process for the examiners and candidates, as well as an exam.

In those early years, the best of the best Accreditation presentations received a special award. The first was awarded to Dr. Dan Mayeda of Maui, Hawaii. Dr. Mayeda became the second Accreditation chair, following Michael Miller; and later he became the ninth AACD president.

In 1994 Dr. Jimmy Eubank, of Plano, Texas, became Accreditation chair and introduced the 12 standardized photographic views used today. Under Dr. Eubank's leadership, the first AACD photographic guide, illustrating the 12 required views, was published. This was a big step forward and, I believe, ushered in today's modern era of the Accreditation credential.

*JH: How was today's scoring system devised?*

JM: By 1997, Dr. Eubank and I were running hands-on Accreditation preparation programs, in various universi-

ties across the country, for the purpose of training dentists in photography and cosmetic dentistry procedures necessary to complete the Accreditation exam successfully. With the use of special typodonts, participants completed all five of the current Accreditation cases. More than 60 dentists per year, from different parts of the country, were going through these mock Accreditation courses. We essentially now had a forum for introducing new ideas to the Accreditation protocol, and could test them out to see if they worked.

---

*The five case types used today began taking form in 1987.*

---

It became clear that a standardized scoring system was needed to make an essentially subjective examination more objective. In 1999, while in Calgary and after giving a hands-on course, my host and I attended an equestrian stadium jumping competition. Stadium jumping is scored on a subtraction system. Minor, major, and catastrophic faults, such as knocking over a barrier, or refusing to jump, are deducted from the score.

I wondered if clinical cases could be scored similarly—by subtracting points for faults. If so, this could allow for a more objective assessment of the cosmetic dentistry presented in AACD Accreditation cases.

I explained a hypothetical system of minor, major, and catastrophic faults to Dr. Eubank, based on my experience in Calgary. After his additions, we decided to see if it would work in our next Accreditation preparation course, and it did. The scoring was as follows: Minor faults were two points off, major faults were four points off, and catastrophic faults were eight points off. Cases with seven or fewer faults would pass. After explaining the scoring system to a group of 15 dentists in our next course, we had them score the slides of their colleagues' cases and were delighted that the system worked. There was, however, a slight drawback: Occasionally an otherwise good case would not pass due to four minor faults or one major fault and two minor faults. We experimented by adding an optional "plus one" point for the overall look of the case. These cases were called "on the bubble." Today, they are termed "borderline."

When the fault system proved successful in mock Accreditation trials, Dr. Eubank then introduced it to Accreditation Chair Dr. Larry Addleson. It has worked ever since. This case scoring system has made the Accreditation examinations much more objective and has allowed the examiners to calibrate their scoring criteria. For a prospective Accreditation Candidate, knowing that cases do not need to be perfect to pass is critical.

There is room for minor faults and even an occasional major fault in what we term the "zone of excellence," representing a passing case.

**JH:** *How do you view today's current existing Accreditation system?*

**JM:** Case selection is a huge success-related issue. As there are no additional credits awarded for degree of difficulty, it is paramount to pick the right kind of case to produce an ideal result. I believe this has been an educational process for the examiners as well.

Overall the system is highly objective, using a double-blind format. It is about as fair and non-political as any exam I have seen.

**JH:** *Dr. Morley, thank you very much for your insights into the AACD's past and into the future of cosmetic dentistry. We appreciate all that you have done and continue to do for the Academy and the profession.*

#### **AACD Acknowledgment**

*The American Academy of Cosmetic Dentistry recognizes Dr. Jeff Morley as an AACD Accredited Fellow Member (FAAACD), AACD co-founder, AACD Past President (1987-1989), founding member of AACD's Accreditation Examining Board, and five-time winner of the AACD Celebration of Excellence Award.*



# ACHIEVE MORE.

Ignite your career. Gain confidence in your skills. Earn respect and credibility from your peers and patients. Achieve the most recognized designation and well-respected credential in cosmetic dentistry. Set yourself apart. Accept the challenge. Pursue Accreditation.

[www.aacd.com](http://www.aacd.com) • 800.543.9220 • 608.222.8583



Brought to you by



le, we **lead** peop  
the success **or** failure of a  
entories can **be** managed  
only things **left** by those  
aves **behind** in other



*Seven steps to creating your laboratory's destiny.*

**NADL 2010 Vision 21 Meeting • Las Vegas, Nev. • Jan. 21 – 23, 2010**

Register online at [www.nadl.org/meetings.cfm](http://www.nadl.org/meetings.cfm)

# CLINICAL SCIENCE AND ART

## IN THIS SECTION:

---

CLINICAL COVER STORY ♦ BY <i>ROBERT G. RITTER, DMD &amp; NELSON A. REGO, CDT, AAACD</i> .....	111
ESTHETIC REPAIR OF THE DENTAL CONSEQUENCES OF CELIAC DISEASE: A CASE REPORT ♦ BY <i>JAMES F. FONDRIEST, DDS &amp; MATTHEW R. ROBERTS, CDT, AAACD</i> .....	118
CORRECTING SOFT TISSUE DEFICIENCIES PRIOR TO ESTHETIC DENTAL PROCEDURES ♦ BY <i>PAUL S. PETRUNGARO, DDS, MS</i> .....	129

## MATERIAL CONSIDERATIONS FOR USING LITHIUM DISILICATE AS A THIN VENEER OPTION



by

Robert G. Ritter, DMD  
Jupiter, FL  
www.ritterandramsey.com

Nelson A. Rego, CDT  
AACD Accredited Member  
(AAACD)  
Santa Fe Springs, CA  
www.regosmiles.com

### INTRODUCTION

At a time when dentists and patients alike are seeking both esthetic and conservative smile makeover options, lithium disilicate glass ceramic is a unique material. With high strength, natural optical properties, and the ability to be pressed thin, lithium disilicate has the potential to provide new options for minimal-preparation veneers.

---

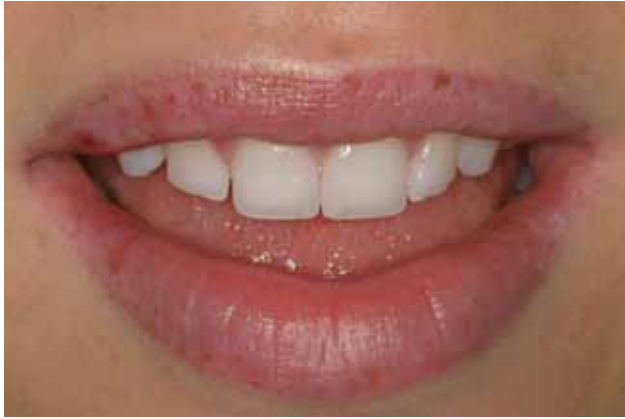*Skilled and experienced ceramists now can press lithium disilicate laminate veneer restorations as thin as .3 mm with great success.*

---

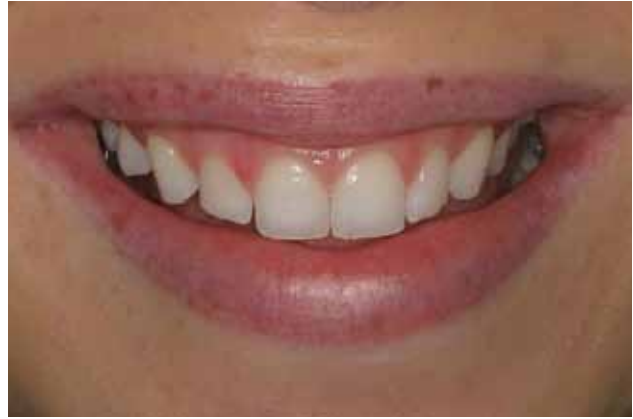Skilled and experienced ceramists now can press lithium disilicate laminate veneer restorations as thin as .3 mm with great success. When a knowledgeable and trained ceramist fabricates the restorations, natural and durable results can be achieved.<sup>1</sup>

Unfortunately, when pressable ceramics were introduced, there was concern about their benefits compared to feldspathic porcelain, particularly considering the amount of tooth reduction that often was necessary in order to achieve esthetic results. The minimal thickness for pressable ceramic restorations has been cited in the literature as .6 mm to .8 mm, which sometimes led to aggressive tooth reduction in the past.<sup>2</sup>

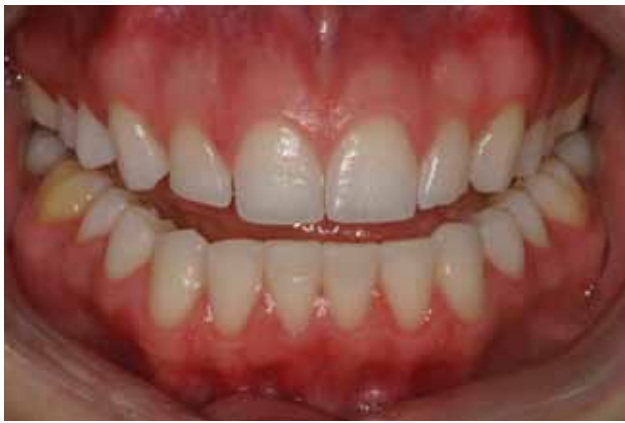A pressable material composed of a promising lithium disilicate glass ceramic (IPS e.max Press, Ivoclar Vivadent; Amherst, NY) can be used in conjunction with minimal preparation techniques and smile design principles to achieve beautiful, natural-looking and long-lasting results. This article introduces readers to the material characteristics of lithium disilicate, describes its application for thin pressable veneers,



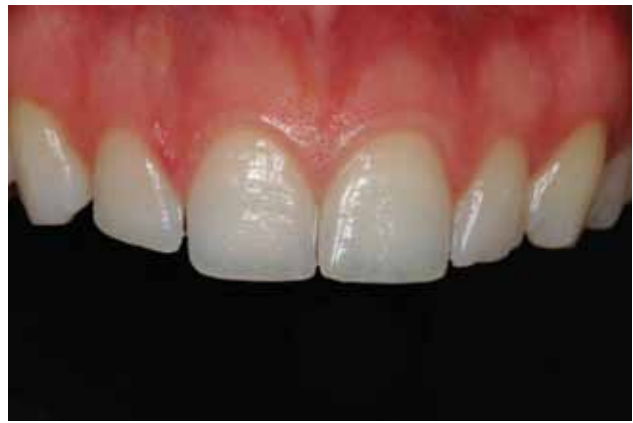*Figure 1: Preoperative close-up view of the patient showing short teeth.*



*Figure 2: Preoperative close-up view of the patient with her natural smile. Note the vertical maxillary excess.*



*Figure 3: Preoperative retracted view of the patient, emphasizing her gingival display.*



*Figure 4: Close-up 1:1 view of the patient's anterior teeth showing length-to-width ratio.*

and outlines the clinical protocol for treatment planning and placing lithium disilicate veneers.

### UNDERSTANDING LITHIUM DISILICATE

Lithium disilicate is an esthetic, high-strength material that can be conventionally cemented or adhesively bonded.<sup>3</sup> It also can offer a full-contour restoration fabricated from one high-strength ceramic, as well as be used in all areas of the mouth when specific criteria are met. Laboratory ceramists find that the versatility and performance of

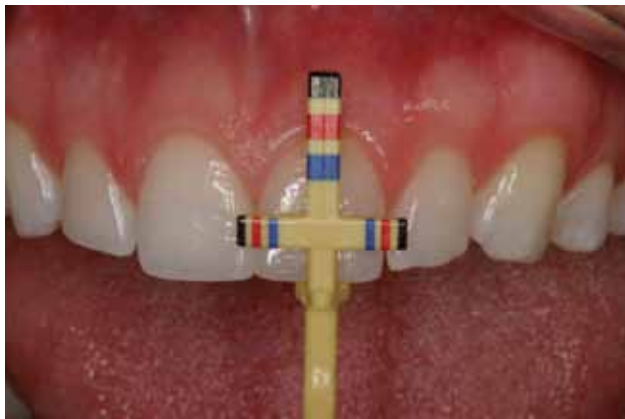lithium disilicate enable the optimization of their productivity when fabricating restorations using this material, since either lost-wax pressing or computer-aided design/computer-aided manufacturing (CAD/CAM) milling fabrication techniques can be used.

Lithium disilicate is among the best known glass ceramics. Glass ceramics are categorized based on their chemical composition or application.<sup>4</sup> IPS e.max lithium disilicate is composed of quartz, lithium dioxide, phosphor oxide, alumina, potassium oxide, and other compo-

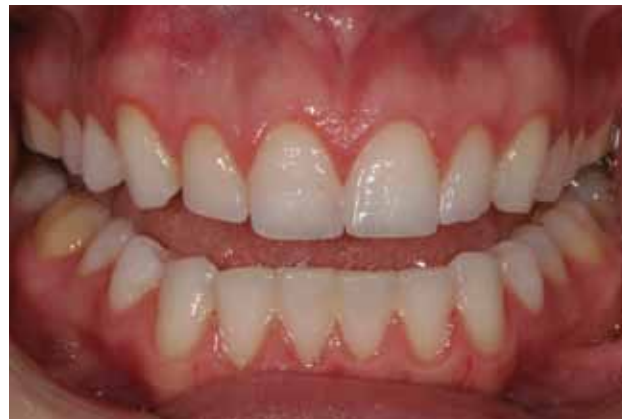nents. This composition produces a highly thermal, shock-resistant glass ceramic as a result of the low thermal expansion that occurs when it is processed. This type of resistant glass ceramic can be processed with either lost-wax hot pressing techniques or modern CAD/CAD milling procedures.

The pressable form of lithium disilicate (IPS e.max Press) is produced using a unique bulk casting production process to create the ingots. This involves a continuous manufacturing process based on glass technology (melting, cooling,





*Figure 5: Dr. Stephen Chu's proportion gauge (Hufriedy; Chicago, IL) was used to determine the ideal measurements for the patient's crown lengthening.*



*Figure 6: Postoperative view of the patient at 12 weeks following the gingival crown-lengthening procedure.*

simultaneous nucleation of two different crystals, and growth of crystals) that is constantly optimized to prevent defects (e.g., pores, pigments). The microstructure of the pressable lithium disilicate material consists of approximately 70% needle-like lithium disilicate crystals that are embedded in a glassy matrix. These crystals measure approximately 3  $\mu\text{m}$  to 6  $\mu\text{m}$  in length.

Polyvalent ions that are dissolved in the glass are utilized to provide the desired color to the lithium disilicate material. These color-releasing ions are homogeneously distributed in the single-phase material, thereby eliminating color pigment imperfections in the microstructure.

### CLINICAL PROPERTIES OF LITHIUM DISILICATE

For single-unit indirect restorations, lithium disilicate is, in the authors' opinion, the best restorative material available. Lithium disilicate material has been in clinical trials for the last four years with adhesive and self-adhesive/conventional cementation. The results have been positive.<sup>5</sup> Mechanical testing of strength using static load with a universal testing machine, subcritical

eccentric loading using a chewing simulator (Willytec; Munich, Germany), and long-time cyclic loading with a chewing simulator (eGo; Regensburg, Germany) have proven several factors contributing to the material's success. First, it has been demonstrated that it is important to consider the minimum thickness of the lithium disilicate frame. Second, the internal aspects of crowns should not be sandblasted. Finally, in comparison to various restorative dental materials for crowns (e.g., leucite glass ceramic, metal ceramic, zirconia), the lithium disilicate material demonstrates superior results.

The strength of the ceramic material in contact with opposing teeth, to fulfill masticatory functions, is about 100 MPa for metal, about 100 MPa for veneered zirconia, and about 150 MPa for leucite glass ceramic. However, for the pressed lithium disilicate, the strength is in the range of 360 MPa to 400 MPa in its final anatomical shaped crown form. This "monolithic," throughout-the-restoration strength is unlike anything found in other metal-free restorative materials.<sup>5</sup>

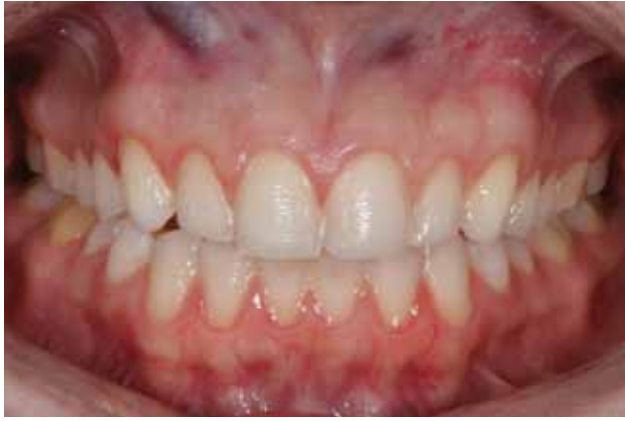Pressable lithium disilicate is ideal for inlays, onlays, thin veneers,

veneers, partial crowns, anterior and posterior crowns, three-unit anterior bridges, three-unit premolar bridges, telescope primary crowns, and implant superstructures.<sup>6-8</sup> When minimal tooth preparation is desired (e.g., thin veneers), IPS e.max lithium disilicate allows ceramists to press restorations as thin as 0.3 mm while still ensuring strength of 400 MPa. If sufficient space is available (e.g., retrusion of a tooth), no preparation is required.

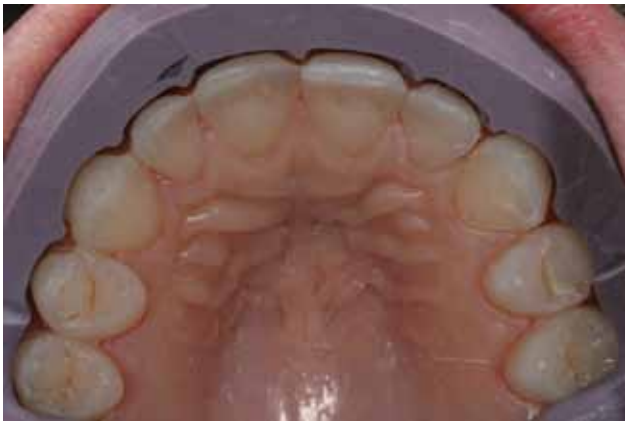### CASE PRESENTATION

A 30-year-old woman presented with short clinical crowns (Figs 1-4). Thorough clinical and periodontal examinations were performed and radiographs were taken, and an esthetic analysis of the patient's smile was conducted. It was determined that the patient required clinical crown lengthening (also sometimes called a "smile lift"), prior to undergoing any indirect restorative treatment.

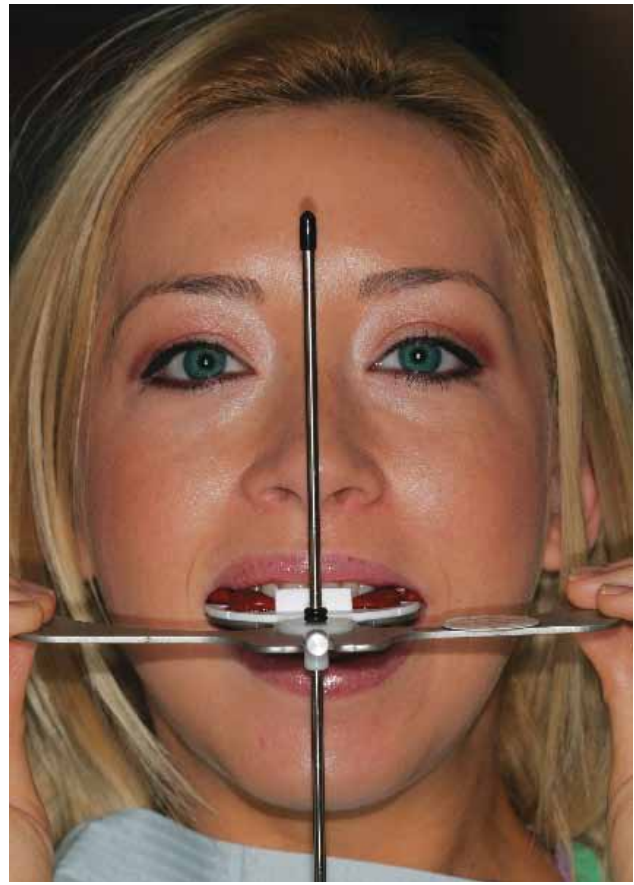
The patient underwent a crown-lengthening procedure to help bring her gingival and tooth proportions into ideal symmetry (Fig 5). She was allowed to heal for six months prior to the initiation of any restorative



*Figure 7: Facial retracted view of the preparations. Note that a .2-mm uniform reduction was achieved entirely in enamel.*



*Figure 8: View of the reduction matrix in place to verify that the required volume of minimal reduction had been achieved.*



*Figure 9: Dr. John Kois' dental facial analyzer (Panadent; Colton, CA) was used.*

work (Fig 6). Then, a treatment plan was developed, and the case was waxed to ideal, with lengthening of the central incisors by 1 mm. The patient agreed to the placement of 10 maxillary pressed glass ceramic (IPS e.max Press) veneers. This pressable material requires significantly less tooth preparation than other indirect materials. This was important, since the patient exhibited healthy tooth structure and was caries-free. Therefore, a minimalist or no-preparation approach was used.

In particular, the authors have found that this lithium disilicate

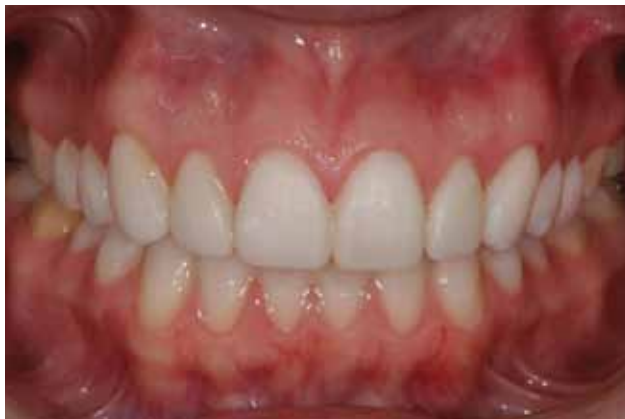material enables clinicians to work with greater confidence when placing these types of restorations. Most of the previous thin press or feldspathic no-preparation cases demonstrated a large breakage factor. Today's lithium disilicate material, however, demonstrates a lesser chance of breaking during insertion.

#### CLINICAL PROTOCOL

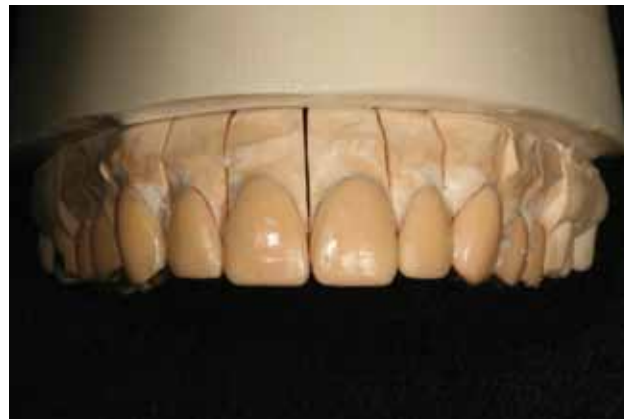The fluoridated enamel was roughened, and a very fine finish line was established to give the ceramist a guide for where to wax. Essentially, although the case involved the placement of thin veneers, an

additive wax technique was used, as no volume of enamel was removed. Preparation guides from the wax-up were used to verify the facial, lingual, and incisal reduction, as well as to ensure uniformity in the thickness of the porcelain (Figs 7 & 8).<sup>9</sup> A combination of depth-cutting burs and preparation guide helped ensure that a minimalist preparation and predictable results were achieved.<sup>10,11</sup>

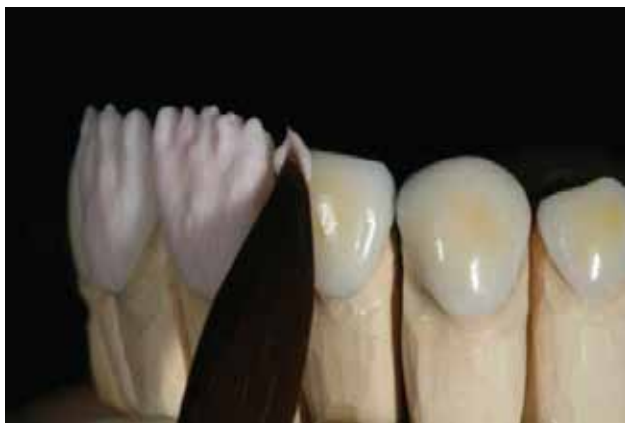A facebow transfer, centric relation bite registration, dental facial analyzer (Fig 9), and several photographs were obtained. This informa-



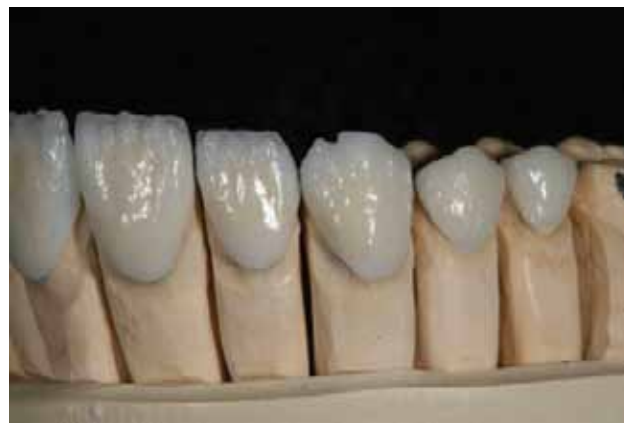*Figure 10: Bisacryl provisionals (Luxatemp, Zenith/DMG; Englewood, NJ) were provided to the patient in the bleach shade.*



*Figure 11: The IPS e.max Press thin veneers were waxed up at the laboratory. Note their minimal thickness, which still offers great support for the ceramic. This provides the dentist with a strong shell that will seat easily, without breakage.*



*Figure 12: Ceram veneering ceramic was applied to the lithium disilicate substructure.*



*Figure 13: Close-up view of the internal, natural-looking effects after baking.*

tion was forwarded to the laboratory for use in developing the case in the most predictable manner possible.<sup>12</sup> A shade of the prepared teeth and an occlusal bite registration were also obtained. Provisionalization was accomplished to provide the patient and the ceramist with a preview (i.e., mock-up) of where the final ceramic would be, as well as the shapes, length, and color of the anticipated restorations (Fig 10).

#### LABORATORY FABRICATION

After the patient approved the provisional "mock-up" of the final restorations, a lost-wax pressing

technique was used to create the thin lithium disilicate veneers. The laboratory ceramist poured a model from the impressions that were received from the dentist, and a full-contour wax-up of the veneers was made, similar to what would be performed for any pressed restoration (Fig 11). The wax-up was sprued onto the ringer former, invested, and burned out. The IPS e.max Press ingots were then pressed into the ring replicating the wax patterns, after which the pressed veneers were divested, layered, and characterized with natural-looking stains and effects (Figs 12-14).

#### CEMENTATION

The provisional restorations were carefully removed. The preparations then were cleaned with a chlorhexidine rinse (Consepsis, Ultradent Products, Inc.; South Jordan, UT) and dried. To ensure complete seating, as well as to evaluate fit, marginal integrity, color, and esthetic integration, the restorations were tried in using Variolink veneer transparent try-in gel (Ivoclar Vivadent). After approval from the patient, the veneers were removed and set aside. A total etch 37% phosphoric acid was applied to the preparations

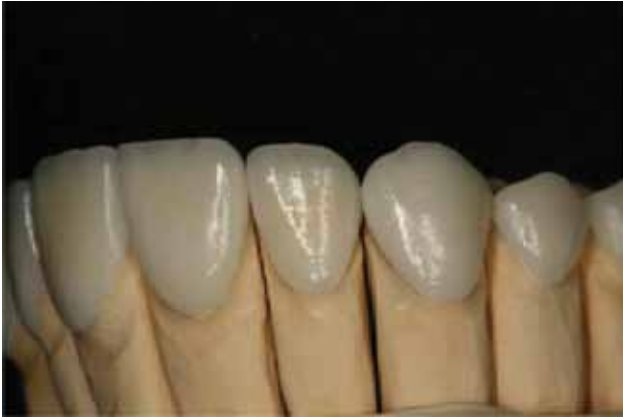

Figure 14: Close-up view of the definitive veneers when placed on the model.

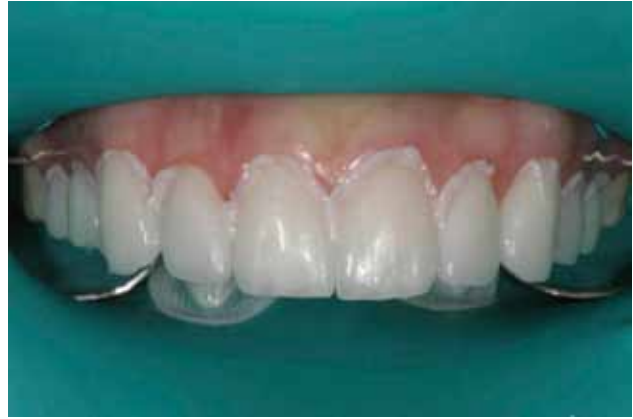

Figure 15: The veneers were cemented into place with resin cement.

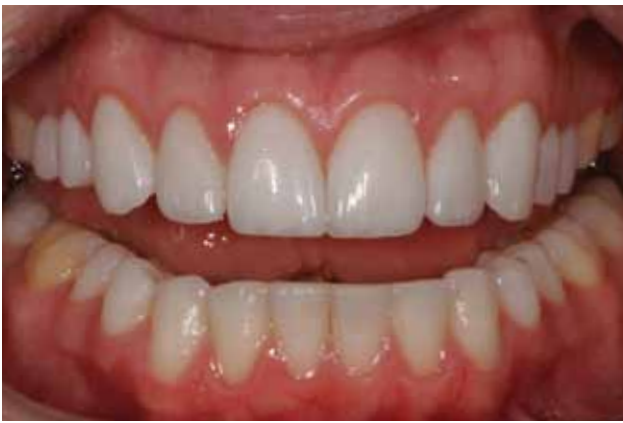

Figure 16: Retracted postoperative view of the definitive thin veneers.

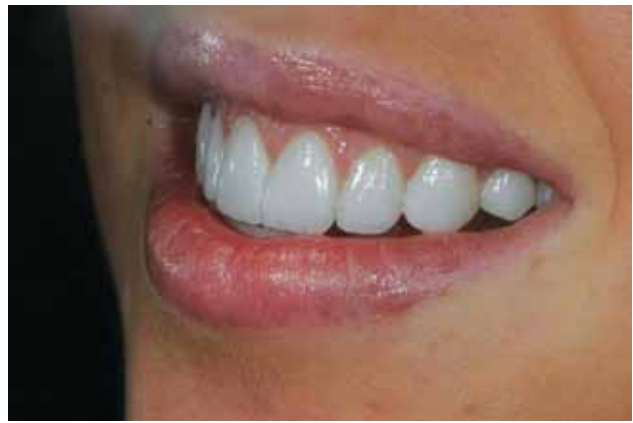

Figure 17: Postoperative; left lateral view revealing the reduction in gingival display and proper tooth outline.

for 10 seconds per tooth, and then thoroughly rinsed from the preparations. After etching, a desensitizing agent (Systemp Desensitizer, Ivoclar Vivadent) was applied to the preparations and lightly air-dried.

A thin layer of a single-component bonding agent (Excite, Ivoclar Vivadent) was brushed for 15 seconds per tooth onto the preparations, and then lightly air-dried. The single-component bonding agent was then light-cured for 10 seconds per tooth.

Variolink veneer resin cement was placed in the internal surface

of the restorations, after which they were seated into place (Fig 15). Before curing, Liquid Strip (Ivoclar Vivadent) was applied to the veneer margins to reduce the oxygen inhibition layer. To spot-tack the restorations at the gingival third, a 2-mm light-curing tip was used, and the curing light was then waved for five seconds per tooth from the buccal aspect to initiate a gel-like consistency of the Variolink veneer cement and tack the restorations into place.

Each restoration was cured for 30 seconds from the buccal, lingual, and incisal aspects. Using Op-

traFine diamond polishing paste and bristle brush (Ivoclar Vivadent), the margins of the restorations were polished. After polishing with OptraFine diamond polishing paste and bristle brush, the excess cement was removed from the margins and interproximally (Fig 16).

## CONCLUSION

This case differs from other thin or no-preparation veneer cases chiefly in terms of material selection. Clinicians and ceramists alike know that esthetic pressable ceramics are capable of being pressed to as



*Figure 18: Postoperative; final full-facial view of the patient's smile.*

thin as .5 mm, but with hard work. Most clinicians and laboratory ceramists would recommend the use of feldspathic porcelain as the material of choice for thin or no-preparation veneers. However, this material has its own drawback of not being able to be fabricated on the articulator because it requires the use of the platinum foil technique.

---

*The minimal thickness for pressable ceramic restorations has been cited in the literature as .6 mm to .8 mm, which sometimes led to aggressive tooth reduction in the past.*

---

With the true wax and pressed technique of lithium disilicate, fabrication on a fully adjustable articulator is possible, so cases can be worked out in terms of all function and excursive movements. This is among the greatest assets of this material. The literature also suggests that the fit of pressed materials can be as good as gold, approaching 25  $\mu$  in the hands of skilled technicians. The adhesive technique for placing

the final restorations is exactly the same as it is for pressed or feldspathic restorations, and the esthetic results are outstanding (Figs 17 & 18).

#### References

1. Javajeri D. Considerations for planning esthetic treatment with veneers involving no or minimal preparation. *JADA*. 2007;138(3):331-7.
2. Nash RW. Porcelain veneers: a clinical perspective. *Contemp Esthet Restor Pract*. 2006; December.
3. Fabianelli A, Goracci C, Bertelli E, Davidson CL, Ferrari M. A clinical trial of Empress II porcelain inlays luted to vital teeth with a dual-curing adhesive system and a self-curing resin cement. *J Adhes Dent*. 2006;8(6):427-31.
4. Denry IL. Recent advances in ceramics for dentistry. *Crit Rev Oral Biol Med*. 1996;7(2):134-43.
5. Heintze S. Research and development. Ivoclar Vivadent: Schaan, Lichtenstein.
6. Sorensen JA, Cruz M, Mito WT, Raffener O, Meredith HR, Foser HP. A clinical investigation on three-unit fixed partial dentures fabricated with a lithium disilicate glass-ceramic. *Pract Periodontics Asthet Dent*. 1999;11(1):95-106.
7. Höland W, Schweiger M, Frank M, Rheinberger V. A comparison of the microstructure and properties of the IPS Empress 2 and the IPS Empress glass-ceramics. *J Biomed Mater Res*. 2000;53(4):297-303.
8. Kheradmandan S, Koutayas SO, Bernhard M, Strub JR. Fracture strength of four different types of anterior 3-unit bridges after thermo-mechanical fatigue in the dual-axis chewing simulator. *J Oral Rehabil*. 2001;28(4):361-9.
9. Brunton PA, Aminian A, Wilson NH. Tooth preparation techniques for porcelain laminate veneers. *Br Dent J*. 2000;189(5):260-2.
10. Rosenthal L. Preparation guidelines for less-invasive cosmetic restorations. *Gen Dent*. 2007;55(7):624-30.
11. Bassett JL. A cognitive systematic approach to analyzing preparation design for a difficult space management case. *Gen Dent*. 2007;55(7):664-8.
12. Trinker TF, Roberts M. A systematic approach to anterior esthetics. *Contemp Esthet Restor Pract*. 2003;42-9.

#### AACD Acknowledgment

*The American Academy of Cosmetic Dentistry recognizes Mr. Nelson Rego as an AACD Accredited Member (AAACD), Accreditation Examiner, member of the American Board of Cosmetic Dentistry, and Give Back A Smile™ (GBAS) volunteer who has restored the smiles of two GBAS survivors.*



## ESTHETIC REPAIR OF THE DENTAL CONSEQUENCES OF CELIAC DISEASE: A CASE REPORT



by James F. Fondriest, DDS  
Lake Forest, IL  
lakeforestdentalarts.com

Matthew R. Roberts, CDT  
AACD Accredited Member  
(AAACD)  
Idaho Falls, ID  
www.teamaesthetic.com

### ABSTRACT

Hypocalcification of her tooth enamel had created occlusal and esthetic problems for a 26-year-old patient with celiac disease. Celiac disease is an autoimmune digestive disorder that damages the villi of the small intestine and interferes with absorption of nutrients from food. This disease can cause the improper development of enamel on adult teeth. The combination of bruxism with weak and poorly developed enamel had caused significant loss of tooth structure for this patient. Bonded composite did not serve well on functional occlusal surfaces. Full fixed prosthodontic coverage of her teeth was performed. The details of creating a customized appearance of the prosthesis for this patient are discussed.

---

*A fairly common oral manifestation of celiac disease is abnormal tooth shape and/or appearance.*

---

### INTRODUCTION

Celiac disease is a digestive disorder that damages the small intestine and interferes with absorption of nutrients such as calcium from food.<sup>1</sup> People who have celiac disease cannot tolerate a protein called gluten, found in wheat, rye, and barley. Gluten is found mainly in foods but may also be found in products we use every day, such as stamp and envelope adhesive, certain medicines, and vitamins. When people with celiac disease eat foods containing gluten, their immune system responds by damaging the finger-like villi of the small intestine. When the villi become damaged, the body

REGISTER  
ONLINE NOW!

**AACD** *presents*  
“**responsible esthetics**”

**Friday, January 22 - Saturday, January 23, 2010**

**new york, new york**

The stage is set and when the curtain draws it will reveal a dental program that is choreographed to reinvigorate your passion for dentistry, elevate patient communication and satisfaction, and energize your practice or laboratory. Join the AACD on Broadway for the Winter 2010 AACD Regional Meeting starring: Stephen Chu, DMD, Michael Apa, DDS, Michael Bellerino, CDT, Brian LeSage, DDS, Brian Lindke, CDT, Kenneth Magid, DDS, Frank Milnar, DDS, Jeff Morley, DDS, and Gary Radz, DDS.



AMERICAN ACADEMY  
OF COSMETIC DENTISTRY

[www.aacd.com](http://www.aacd.com) | [twitter.com/theaacd](https://twitter.com/theaacd) | 608.222.8583 | 800.543.9220

*Brought to you by the AACD in collaboration with the New York Metro Academy of Cosmetic Dentistry,  
Empire State Academy of Cosmetic Dentistry, and the New York University College of Dentistry.*

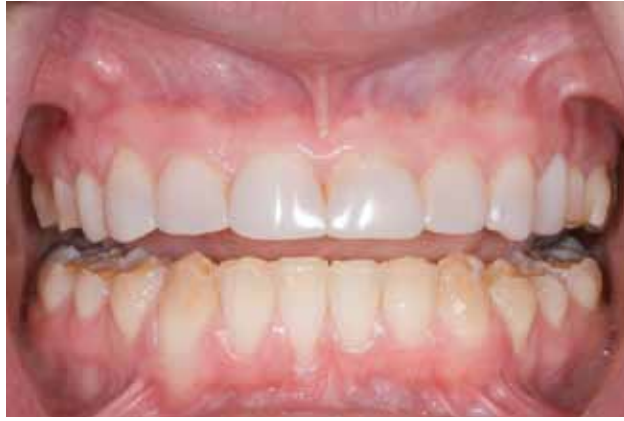

Figure 1

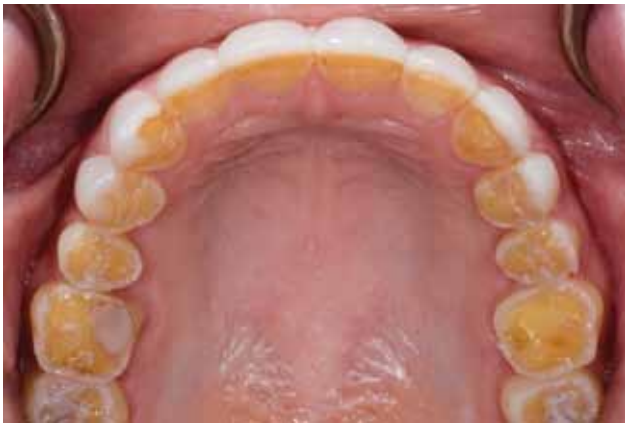

Figure 2

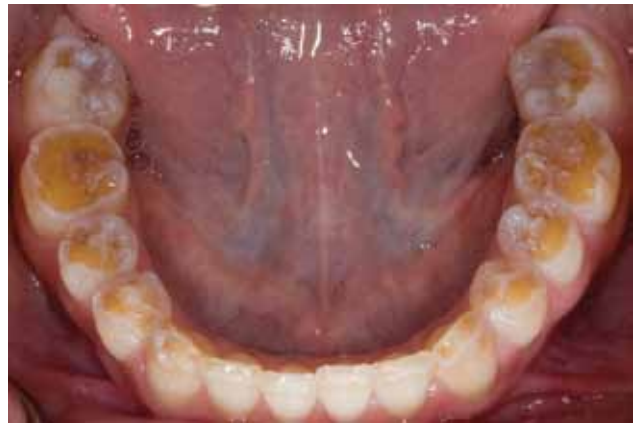

Figure 3

*Figures 1-3: Celiac disease was the cause of this enamel/dentin dysplasia. The teeth did not retain bonded composite well and displayed low occlusal wear resistance. Unlike the composite that was applied to the occlusal surfaces, which chipped off quickly, the anterior composite will stay for years.*

is unable to absorb nutrients into the bloodstream, which can lead to malnourishment. Failure to thrive during childhood development is a common indicator of celiac. Common signs of celiac disease include anemia, delayed growth, weight loss, and joint problems; and the bones become weak, brittle, and prone to fracture. Celiac disease is a genetic condition that can be triggered by events such as surgery, pregnancy, childbirth, viral infection, or severe emotional stress. The

only treatment for celiac disease is a lifelong gluten-free diet.

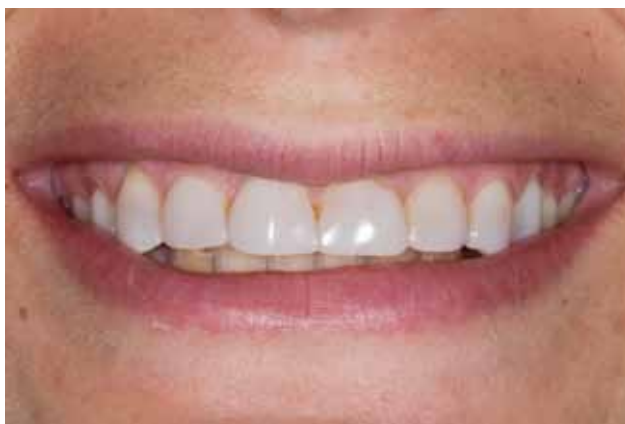A fairly common oral manifestation of celiac disease is abnormal tooth shape and/or appearance. The teeth can be slightly small, widely spaced, and discolored with hypocalcified enamel (Figs 1-3). Patients with dental enamel defects of the entire secondary dentition should be screened for celiac disease even in the absence of gastrointestinal symptoms.<sup>2</sup> There can also be recur-

rent aphthous stomatitis. This disease affects one in 100 individuals, and 97% of those affected are undiagnosed.<sup>3</sup>

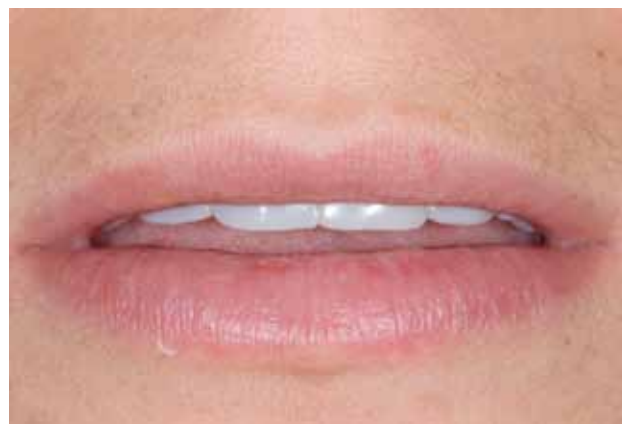### PATIENT HISTORY AND GOALS

The patient discussed here had been diagnosed with celiac disease at age 13. Although she continued to have occasional minor gastrointestinal flare-ups, her medical/dietary therapy had mainly quieted the manifestations of the disease after





**Figure 4:** The recently placed composite bonding significantly improved the smile display, but the composite margins became stained soon after placement.



**Figure 5:** Commissure-to-commissure image of tooth display while the lips are at rest, or in the "M" position.<sup>5</sup>

diagnosis. The damage to her teeth had been done as the teeth were being formed prior to diagnosis.

She was unhappy with the esthetics of her smile. She presented at age 26 with composite bonding that had been applied to the buccal surfaces of her maxillary front teeth, which had been maintained for 18 months (Fig 4). Although the marginal integrity was already staining and failing, the patient's former dentist reported that the composite improved the esthetics of her smile greatly. Previous composite restorations had not been retained for very long, especially on chewing surfaces or functional occlusal surfaces. The qualities of her enamel and dentin as a result of celiac disease might have affected the bond strength of the composite, compromising the longevity of her previous restorations. She had been referred to us to have her teeth restored by more permanent and esthetic means. The goals were to create an improved esthetic display, establish ideal tooth anatomy, and more permanently impede the ongoing changes that had been occurring in her bite.

### TREATMENT PLAN

Due to the poor bonding qualities of the teeth, nighttime bruxism, and the ongoing loss of vertical dimension, it was decided to do full-coverage restorations on all of her teeth. Due to the lack of certainty in reliably achieving a strong dentin bond, the tooth preparations were designed with maximum retention and resistance form. All posterior teeth would be restored with porcelain-fused-to-gold crowns and pressed Empress (Ivoclar Vivadent; Amherst, NY) crowns in the anterior teeth.

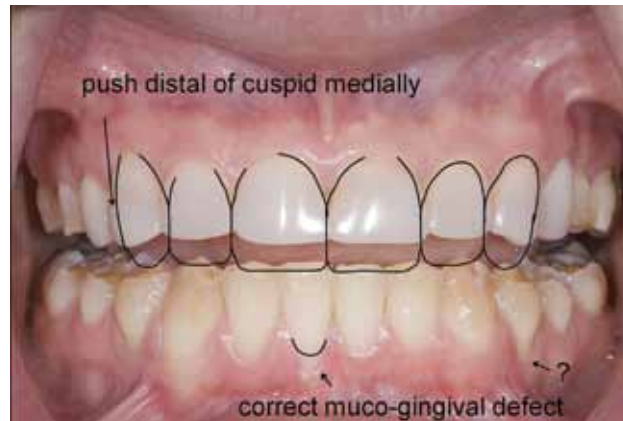The planning phase included acquiring diagnostic photographs of the patient, radiographs, and mounted models; and ascertaining the patient's desires and expectations. The more information-sharing that was done, the more the patient took an active role in the planning process. She had definite opinions on what specific shapes she wanted her new teeth to have, as well as the level of brightness and translucency. Her request was to have "natural-looking teeth, but a little brighter." The patient did not have the knowledge or vocabulary to describe her

understanding of what a beautiful smile was, but she (and her mother) indicated that they would know it when it was achieved. Much time was spent clarifying what their definition of *natural* was.

### TREATMENT

#### DISCUSSION

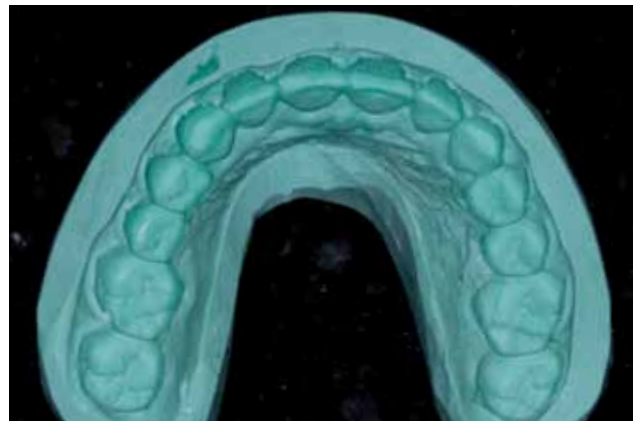
For a 26-year-old female, the normal tooth display of the maxillary centrals when the lips are at rest is 5 mm to 6 mm.<sup>4</sup> In this patient, however, only 1.5 mm to 2 mm of #8 and #9 were visible hanging down below the upper lip (Fig 5). She had a normal lip mobility of approximately 8 mm, and the gingival display was normal and was deemed symmetrical enough in full smile. The centrals measured only 8 mm in vertical length, rendering a square look. A normal length-to-width ratio for the centrals would be achieved by adding 2.5 mm to 3 mm in length. The vertical dimension of occlusion was opened 3 mm as measured from the incisal edges of the maxillary and mandibular centrals. The majority of the addition was to the maxillary arch, adding posterior occlusal thickness in varying amounts



*Figure 6: Line drawings of agreed-upon outline form of future teeth used as a guide in creation of the wax-up. A periodontal consultation recommended a muco-gingival connective tissue graft on the buccals of #21 and #25.*



*Figure 7: Laboratory putty matrix impression of the wax-up used as a buccal surface reduction guide.*



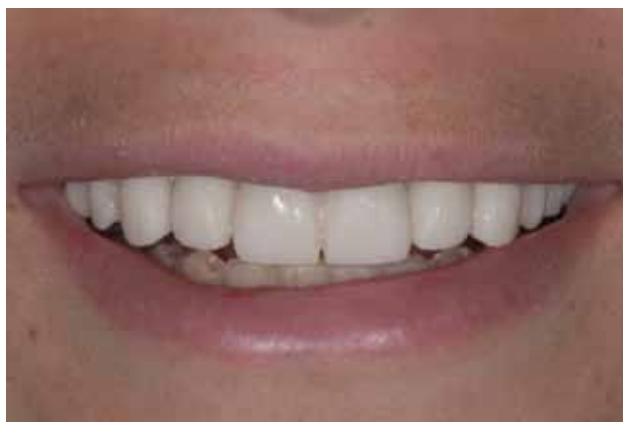*Figure 8: Laboratory putty matrix impression of the wax-up used for provisional fabrication.*

to level the occlusal plane. Opening the vertical dimension served three purposes: It restored some vertical dimension that was being lost by the enamel breakdown faster than the patient was adapting, it allowed for a flat occlusal plane that otherwise would have been uneven after the front teeth were lengthened, and it allowed the lengthening of the maxillary incisors without steepening the guidance.

#### IMPORTANCE OF THE PROVISIONALS

Although we are sometimes referred new patients who think, imagine, and assume everything is possible, the majority of clients do not know what really is possible and even if they do, they do not know what the dentistry will look like in their own mouth. Many practitioners have the ability to create digital images that represent potential outcomes.<sup>6,7</sup> These are helpful but can easily give patients unrealistic expectations due to the fact that changing real teeth is far more difficult than doing it digitally. Applying com-

posite mock-ups to the teeth will give the patient a good impression of how it could look, and often the contours of this mock-up are used in fashioning the provisionals and ultimately the final restorations. When changing the incisal edge position significantly, mock-ups alone may not be an adequate substitute for diagnostic longer-term provisionals.<sup>8,9</sup> It helps to both see and “feel it” to judge it. Wearing provisionals for a month or two would also serve to better develop my patient’s understanding of what was possible esthetically and offer her more op-



*Figure 9: The patient wore indirect acrylic provisionals on the upper arch for several months.*



*Figure 10: Right lateral view of maxillary provisionals.*



*Figure 11: Left lateral view of maxillary provisionals.*

portunity for growth, appreciation, and involvement in the process.

#### **VISUAL GUIDANCE FOR THE LABORATORY**

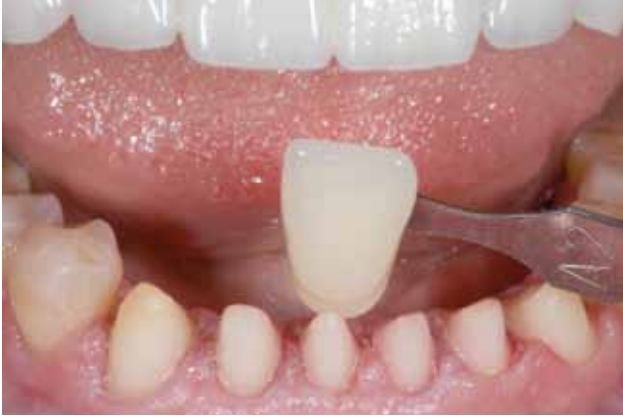When the patient's vision was fully understood, a variety of portraits, intraoral images, scanned magazine photographs, and line drawings (Fig 6) were then collated in a PowerPoint™ presentation. This served as the laboratory prescription for a wax-up of the treatment plan. The visual guidance that the laboratory technician received as to how to create the esthetic contours of the wax-up in this presentation was of

far greater value than any written document. The wax-up was a rendering of my understanding of what the patient wanted esthetically, and would also serve as the first representation of her final smile. All too often the final restoration serves as the only rendering, especially with implant restorations. This limits the many lessons that the intermediate steps of doing a wax-up and provisionals can provide.

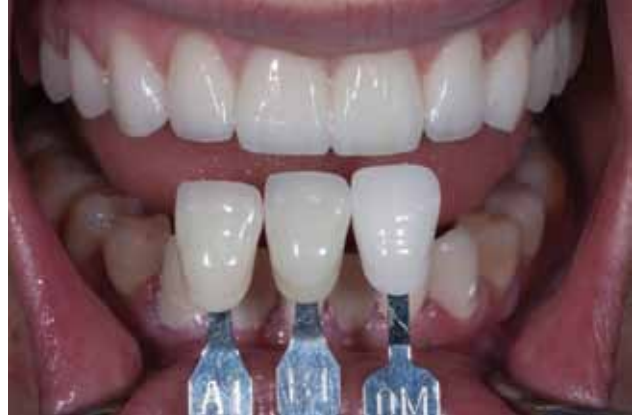#### **IMPORTANCE OF THE WAX-UP**

From a treatment perspective, the wax-up was more than just a guide

for the laboratory to complete the project. The wax-up gave a better feel for just how much reduction needed to be done to move her teeth into preferred orientations and positions.<sup>10</sup> The wax-up allowed detailing for ideal placement of the cusps-fossae relationships and the ridge blade placements for the posterior teeth. The wax-up can allow tooth reduction guides to be made (Fig 7) that represent the desired location of the external surfaces of the final anterior restorations, thus directing tooth preparation to achieve adequate and appropriate restoration



*Figure 12: Stump shade prior to completing the lower front six teeth, one week after insertion of crowns ##6-11. Treatment throughout the mouth was done one sextant at a time.*



*Figure 13: Shade prior to completing the lower front six teeth, one week after insertion of crowns ##6-11.*

thickness.<sup>11</sup> The reduction guides for this case proved very valuable, as their use reduced significantly the amount of tooth reduction from the normal crown preparation. Another version of a lab putty matrix of the wax-up (Fig 8) was used to fabricate acrylic provisionals indirectly in the laboratory.

#### PROVISIONALIZATION

When the wax-up was completed and the reduction guides and putty matrix impressions were created, the patient was scheduled for preparation and provisionalization of the maxillary arch. The lower arch was temporarily built up with composite to help open the vertical. It was at the first placement of the maxillary provisionals that the patient saw her new smile start to materialize. No matter how well the contours were planned with the preoperative photographs and wax-up, until we placed these provisionals into her mouth we did not know what it would look like or how it interacted with the tissue to create scallop forms and inter-dental papillae.<sup>9,12</sup> She got to see for herself what the amended length, shapes, incisal embrasures, etc. that she chose for her

teeth looked like behind the drape of her own lips (Figs 9-11).

Wearing the provisionals allowed the patient to adapt to the changes in the phonetic interplay between the teeth and the occlusal changes that had been created by the significant prosthetic reorientation of her teeth prior to the delivery of her final restorations.<sup>13,14</sup> Due to the increased functional stresses and potential for porcelain fracture from the occlusal trauma that comes with bruxism, a shallow-to-flat anterior guidance with a smooth crossover in excursive movements was created.

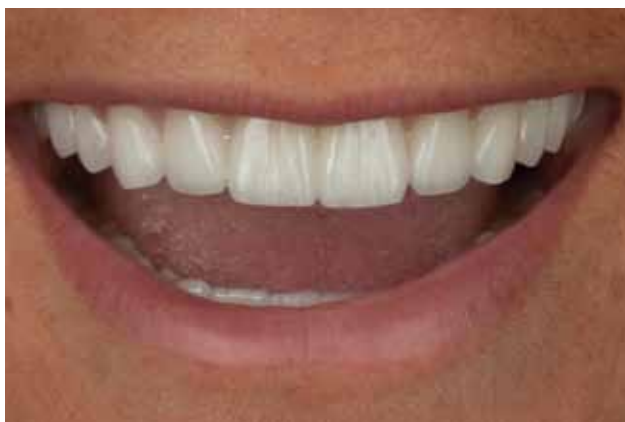Often patients are startled by the quick and profound changes that can be effected through dentistry. The provisionals allow the patient to become accustomed to the changes. Occasionally a patient will pull back on the degree of change desired because of the difficulty in getting used to a new look. When they look at a smile for their entire life and suddenly it is gone, it can be disorienting. If the practitioner gives the patient the time to actually *live* in the provisionals prior to taking final impressions, the patient can be brought further along.

#### LABORATORY WORK

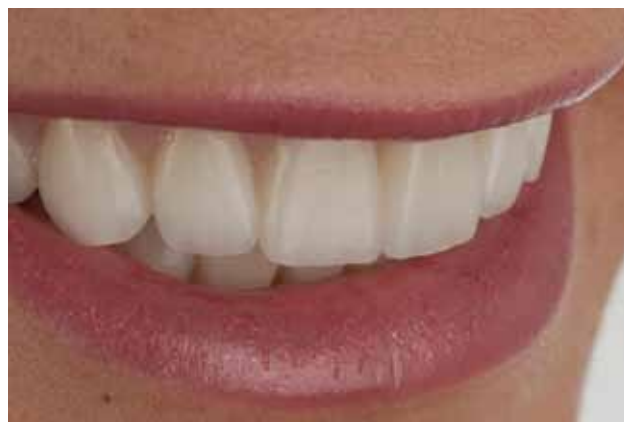When the maxillary provisionals had fulfilled all of the goals for esthetics, function, phonetics, and cleansability, it was time to send the case to the laboratory. Because all of the criteria for acceptance had been worked out in the provisional stage, the laboratory just had to duplicate the contours of the provisionals to achieve an esthetic and comfortable result.<sup>10</sup> Documenting the provisionals included straight-on portraits, portraits taken from the side, close-up extraoral and intraoral photographs, retracted images from all angles when teeth were together and then when they were apart, stick bite, mounted models of the provisionals, and bite registration records of the provisionals and prepared teeth. Offering a critique of the provisionals (mine and the patient's) was helpful to my technician partner. The technician was given direction as to how much artistic license there was with the duplication of the contours of the accepted provisionals.

#### FINAL RESTORATIONS

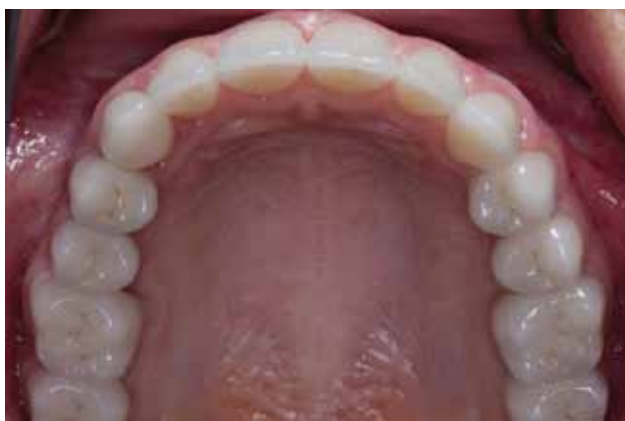To decrease the level of difficulty of replacing the maxillary provisionals with the final prosthetics, this



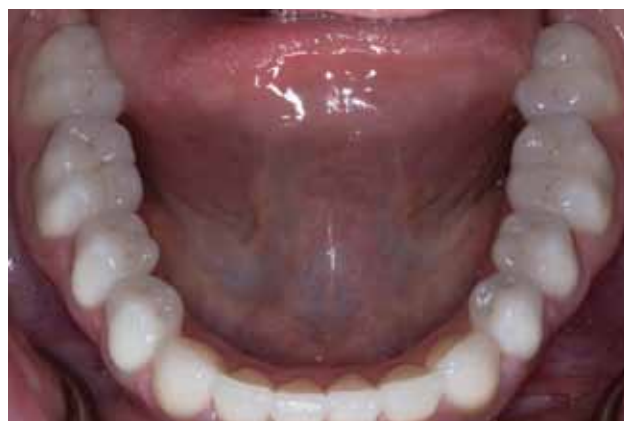*Figure 14: Postoperative full smile.*



*Figure 15: Postoperative lateral view of full smile.*



*Figure 16: Postoperative maxillary occlusal view.*



*Figure 17: Postoperative mandibular occlusal view.*

patient was restored one sextant at a time. This way, the trauma at any given appointment was far less. No master impression required capturing more than six teeth at a time (Figs 12 & 13). This also decreased the risk of bite registration errors, which are far more frequent when doing an entire arch.

The lower arch was completed in three segments like the upper arch but without a wax-up and prolonged use of provisionals (Figs 14-18). All posterior crowns were luted with RelyX luting cement (3M ESPE; St. Paul, MN). The anterior teeth were bonded with Optibond FL

(Kerr; Orange, CA) and RelyX ARC dual-cure resin. Assuming that high bond strengths were unlikely with any cementation system, the choice of luting agents was based on what is commonly used in the office.

### CONCLUSION

This patient suffered the dental consequences of celiac disease in combination with severe bruxism. The resulting significant dental attrition caused the loss of vertical dimension and diminished esthetics. A custom smile was produced by collaborating with the patient in the design on every level of the final

prostheses. Specific shapes, textures, translucency gradients, and chroma and value gradients were created to fashion this patient's definition of a beautiful smile.

### Acknowledgments

*The author thanks the laboratory contributions of Mark Kajfez, CDT (Waukegan, IL), who did the posterior crowns; Dave Rice, DDS (Elgin, IL), for the graphics help; and Dave McClenahan, DDS (Lake Forest, IL), for the muco-gingival grafts.*



Figures 18: Images taken after the entire mouth was completed.

#### AACD Acknowledgment

*The American Academy of Cosmetic Dentistry recognizes Matthew R. Roberts, CDT, as an AACD Accredited Member (AAACD).*

#### References

- Green P, Cellier C. Celiac disease: medical review. *N Engl J Med.* 2007;357:1731-43.
- Pastore L, Carroccio A, Compilato D, Panzarella V, Serpico R, Lo Muzio L. Oral manifestations of celiac disease. *J Clin Gastroenterol.* 2008 Mar;42(3):224-32.
- Celiacdisease.net [Internet]. Chicago: The University of Chicago Celiac Disease Center Web site. Available from <http://www.celiacdisease.net/>.
- Vig R, Brundo G. Kinetics of anterior tooth display. *J Prosthet Dent.* 1996;39(5):502-4.
- Fondriest JF. Documentation versus artistic photography. *Quint Dent Tech.* 2008;31:127-31.
- Brooks LE. Smile-imaging: the key to more predictable dental esthetics. *J Esthet Dent.* 1990 Jan-Feb;2(1):6-9.
- Flucke J. Digital dentistry: using high-tech imaging. *Dent Products Report.* 2002 Jan-Feb:55-58.
- Donovan TE, Cho GC. Diagnostic provisional restorations in restorative dentistry: the blueprint for success. *J Can Dent Assoc.* 1999 May;65(5):272-5.
- Fondriest JF. Using provisional restorations to improve results in complex aesthetic restorative cases. *Pract Proced Aesthet Dent.* 2006;18(4):217-24.
- Magne P, Magne M, Belser U. The diagnostic template: a key element to the comprehensive esthetic treatment concept. *Int J Perio Rest Dent.* 1996 Dec;16(6):560-9.
- Brunton PA, Aminian A, Wilson NH. Tooth preparation techniques for porcelain laminate veneers. *Br Dent J.* 2000 Sept 9;189(5):260-2.
- Ferencz JL. Maintaining and enhancing gingival architecture in fixed prosthodontics. *J Prosthet Dent.* 1991 May;65(5):650-7.
- Pound E. Controlling anomalies of vertical dimension and speech. *J Prosthet Dent.* 1976 Aug;36(2):124-35.
- Pound E. Let /S/ be your guide. *J Prosthet Dent.* 1977 Nov;38(5):482-9.



# OraVerse® (Phentolamine Mesylate) Injection

## it's about time.

Give your patients  
a new measure of comfort –  
bring them back to normal sensation  
in less than half the time.<sup>1</sup>



**Let's face it.** When patients leave your office, they can be limited by the lingering numbness of local anesthesia. Now you can accelerate their return to normal sensation and function with **OraVerse®**.

Adding OraVerse to your regimen is easy too – a simple injection with a standard dental syringe, just like anesthetic.

And you can confidently treat patients aged 6 and older with OraVerse.<sup>2</sup> Nationwide clinical studies prove the safety and efficacy of this novel formulation for phentolamine mesylate, a vasodilator used in medical applications for the last 50 years.

**We think it's about time you found out more.**  
Call us at (888) 888-1441 or visit [www.novalar.com](http://www.novalar.com).

### Important Safety Information

Tachycardia, bradycardia, and cardiac arrhythmias may occur with the use of phentolamine or other alpha-adrenergic blocking agents. Although such effects are uncommon with OraVerse (phentolamine mesylate), clinicians should be alert to the signs and symptoms of these events, particularly in patients with a history of cardiovascular disease. Following parenteral use of phentolamine at doses between 5 to 15 times higher than the recommended dose of OraVerse, myocardial infarction, and cerebrovascular spasm and occlusion have been reported, usually in association with marked hypotensive episodes producing shock-like states.

- 1 Median time to recovery was reduced by 85 minutes (55%) for lower lip and by 83 minutes (62%) for upper lip compared to control.
- 2 OraVerse is not recommended for use in children less than 6 years of age or weighing less than 33 lbs.

See prescribing information on the reverse side of this ad.

© 2009 Novalar Pharmaceuticals, Inc.  
OraVerse and Novalar are registered trademarks of Novalar Pharmaceuticals, Inc.  
Inventistry is a trademark of Novalar Pharmaceuticals, Inc.

0104, Rev. 07/2009



**Novalar®**  
inventistry is here

Novalar Pharmaceuticals, Inc.  
12555 High Bluff Drive • Suite 300  
San Diego, CA 92130 • 858-436-1100

[www.novalar.com](http://www.novalar.com)

# OraVerse™

(Phentolamine Mesylate) Injection

## BRIEF SUMMARY OF PRESCRIBING INFORMATION

Please see package insert for complete prescribing information.

### 1. INDICATIONS AND USAGE

OraVerse is indicated for reversal of the soft-tissue anesthesia, i.e., anesthesia of the lip and tongue, and the associated functional deficits resulting from an intraoral submucosal injection of a local anesthetic containing a vasoconstrictor.

OraVerse is not recommended for use in children less than 6 years of age or weighing less than 15 kg (33 lbs).

### 2. DOSAGE AND ADMINISTRATION

#### 2.1 General Dosing information

The recommended dose of OraVerse is based on the number of cartridges of local anesthetic with vasoconstrictor administered:

Amount of Local Anesthetic Administered	Dose of OraVerse [mg]	Dose of OraVerse [Cartridge(s)]
½ Cartridge	0.2	½
1 Cartridge	0.4	1
2 Cartridges	0.8	2

OraVerse should be administered following the dental procedure using the same location(s) and technique(s) (infiltration or block injection) employed for the administration of the local anesthetic. Note: Do not administer OraVerse if the product is discolored or contains particulate matter.

#### 2.2 Dosing in Special Populations

In pediatric patients weighing 15-30 kg, the maximum dose of OraVerse recommended is 1/2 cartridge (0.2 mg).

(Note: Use in pediatric patients under 6 years of age or weighing less than 15 kg (33 lbs) is not recommended. A dose of more than 1 cartridge (0.4 mg) of OraVerse has not been studied in children less than 12 years of age.)

### 3. DOSAGE FORMS AND STRENGTHS

0.4 mg/1.7 mL solution per cartridge

### 4. CONTRAINDICATIONS

None

### 5. WARNINGS AND PRECAUTIONS

#### 5.1 Cardiovascular Events

Myocardial infarction, cerebrovascular spasm, and cerebrovascular occlusion have been reported to occur following the parenteral administration of phentolamine. These events usually occurred in association with marked hypotensive episodes producing shock-like states. Tachycardia and cardiac arrhythmias may occur with the use of phentolamine or other alpha-adrenergic blocking agents. Although such effects are uncommon after administration of OraVerse, clinicians should be alert to the signs and symptoms of these events, particularly in patients with a prior history of cardiovascular disease.

### 6. ADVERSE REACTIONS

In clinical trials, the most common adverse reaction with OraVerse that was greater than the control group was injection site pain.

#### 6.1 Clinical Trials Experience

Because clinical trials are conducted under widely varying conditions, adverse reaction rates observed in the clinical trials of a drug cannot be directly compared to rates in the clinical trials of another drug and may not reflect the rates observed in practice. Dental patients were administered a dose of either 0.2, 0.4 or 0.8 mg of OraVerse. The majority of adverse reactions were mild and resolved within 48 hours. There were no serious adverse reactions and no discontinuations due to adverse reactions.

Adverse Event	OraVerse			Total (N = 418)	Control (N = 358)
	0.2 mg (N = 83)	0.4 mg (N = 284)	0.8 mg (N = 51)		
	N (%)	N (%)	N (%)	N (%)	N (%)
Patients with AEs	15 (18)	82 (29)	20 (39)	117 (28)	96 (27)
Tachycardia	0 (0)	17 (6)	2 (4)	19 (5)	20 (6)
Bradycardia	0 (0)	5 (2)	2 (4)	7 (2)	1 (0.3)
Injection site pain	5 (6)	15 (5)	2 (4)	22 (5)	14 (4)
Post procedural pain	3 (4)	17 (6)	5 (10)	25 (6)	23 (6)
Headache	0 (0)	10 (4)	3 (6)	13 (3)	14 (4)

Table 1 lists adverse reactions where the frequency was greater than or equal to 3% in any OraVerse dose group and was equal to or exceeded that of the control group. An examination of population subgroups did not reveal a differential adverse reaction incidence on the basis of age, gender, or race. Results from the pain assessments in Study 1 and Study 2, involving mandibular and maxillary procedures, respectively, indicated that the majority of dental patients in both OraVerse and control groups experienced no or mild oral pain, with less than 10% of patients in each group reporting moderate oral pain with a similar distribution between the OraVerse and control groups. No patient experienced severe pain in these studies.

#### 6.2 Adverse Reactions in Clinical Trials

Adverse reactions reported by less than 3% but at least 2 dental patients receiving OraVerse and occurring at a greater incidence than those receiving control, included diarrhea, facial swelling, increased blood pressure/hypertension, injection site reactions, jaw pain, oral pain, paresthesia, pruritus, tenderness, upper abdominal pain and vomiting. The majority of these adverse reactions were mild and resolved within 48 hours. The few reports of paresthesia were mild and transient and resolved during the same time period.

### 6.3 Post Marketing Adverse Reaction Reports from Literature and Other Sources

The following adverse reactions have been identified during postapproval parenteral use of phentolamine mesylate. Because these reactions are reported voluntarily from a population of uncertain size, it is not always possible to reliably estimate their frequency or establish a causal relationship to drug exposure. Acute and prolonged hypotensive episodes and cardiac arrhythmias have been reported with the use of phentolamine. In addition, weakness, dizziness, flushing, orthostatic hypotension, and nasal stuffiness have occurred.

### 7. DRUG INTERACTIONS

There are no known drug interactions with OraVerse.

### 8. USE IN SPECIFIC POPULATIONS

#### 8.1 Pregnancy Pregnancy Category C

There are no adequate and well-controlled studies in pregnant women. OraVerse should be used during pregnancy only if the potential benefit justifies the potential risk to the fetus.

#### 8.4 Pediatric Use

In clinical studies, pediatric patients between the ages of 3 and 17 years received OraVerse. The safety and effectiveness of OraVerse have been established in the age group 6-17 years. Effectiveness in pediatric patients below the age of 6 years has not been established. Use of OraVerse in patients between the ages of 6 and 17 years old is supported by evidence from adequate and well-controlled studies of OraVerse in adults, with additional adequate and well-controlled studies of OraVerse in pediatric patients ages 12-17 years old [Studies 1 (mandibular procedures) and 2 (maxillary procedures)] and ages 6-11 years old [Study 3 (mandibular and maxillary procedures)]. The safety, but not the efficacy, of OraVerse has been evaluated in pediatric patients under the age of 6 years old. Dosages in pediatric patients may need to be limited based on body weight.

### 10. OVERDOSAGE

No deaths due to acute poisoning with phentolamine have been reported.

Overdosage with parenterally administered phentolamine is characterized chiefly by cardiovascular disturbances, such as arrhythmias, tachycardia, hypotension, and possibly shock. In addition, the following might occur: excitation, headache, sweating, pupillary contraction, visual disturbances, nausea, vomiting, diarrhea, or hypoglycemia. There is no specific antidote; treatment consists of appropriate monitoring and supportive care. Substantial decreases in blood pressure or other evidence of shock-like conditions should be treated vigorously and promptly.

### 14. CLINICAL STUDIES

The safety and efficacy of OraVerse when used for reversal of soft-tissue anesthesia (STA), i.e., anesthesia of the lips and tongue following a dental procedure that required local anesthesia containing a vasoconstrictor, were evaluated in the following clinical studies. OraVerse induced reversal of local anesthetic effects on the teeth, mandible and maxilla has not been assessed.

Two Phase 3, double-blinded, randomized, multi-center, controlled studies were conducted in dental patients who had mandibular (Study 1) or maxillary (Study 2) restorative or periodontal maintenance procedures and who had received a local anesthetic that contained a vasoconstrictor. The primary endpoint was time to normal lip sensation as measured by patient reported responses to lip palpation. The secondary endpoints included patients' perception of altered function, sensation and appearance, and their actual functional deficits in smiling, speaking, drinking and drooling, as assessed by both the patient and an observer blinded to the treatment. In the mandibular study, the time to recovery of tongue sensation was also a secondary endpoint. Patients were stratified by type and amount of anesthetic administered.

OraVerse was administered at a cartridge ratio of 1:1 to local anesthetic. The control was a sham injection. OraVerse reduced the median time to recovery of normal sensation in the lower lip by 85 minutes (55%) compared to control. The median time to recovery of normal sensation in the upper lip was reduced by 83 minutes (62%).

In Study 1 (mandibular), OraVerse accelerated: a) the recovery of the perception of normal appearance and function by 60 minutes (40%), b) the recovery of normal function by 60 minutes (50%), and c) the recovery of normal sensation in the tongue by 65 minutes (52%). In Study 2 (maxillary), the recovery of the perception of normal appearance and function was reduced by 60 minutes (50%) and the recovery of normal function was reduced by 45 minutes (43%).

Study 3, a pediatric, Phase 2, double-blinded, randomized, multi-center, controlled study was conducted in dental patients who had received 2% lidocaine with 1:100,000 epinephrine. Dental patients (n = 152, ages 4-11 years) received ½ cartridge of local anesthetic if they weighed ≥15 kg but <30 kg, and one-half or one full cartridge if they weighed ≥30 kg at a cartridge ratio of 1:1 to local anesthetic.

The median time to normal lip sensation in patients 6 to 11 years of age who were trainable in the lip-palpation procedures, for mandibular and maxillary procedures combined, was reduced by 75 minutes (56%). Within 1 hour after administration of OraVerse, 44 patients (61%) reported normal lip sensation, while only 9 patients (21%) randomized to the control group reported normal lip sensation. In this study, neither the patients' perception of their appearance or ability to function nor their actual ability to function was evaluated.

### 16. HOW SUPPLIED/STORAGE AND HANDLING

OraVerse (phentolamine mesylate) Injection 0.4 mg/1.7 mL is supplied in a dental cartridge, in cartons of 10 and 50 cartridges. Each cartridge is individually packaged in a separate compartment of a 10 cartridge blister pack.

NDC 45293-101-01

NDC 45293-101-02

Store at controlled room temperature, 20-25°C (68-77°F) with brief excursions permitted between 15-30°C (59-86°F) Protect from direct heat and light. Do not permit to freeze.

Manufactured by Novocol Pharmaceutical of Canada, Inc., Cambridge, Ontario, Canada  
For Novalar Pharmaceuticals, Inc., San Diego, CA 92130

US Patent Nos.: 6,764,678; 6,872,390; 7,229,630

Trademark of Novalar Pharmaceuticals, Inc.

### 17. PATIENT COUNSELING INFORMATION

Patients should be instructed not to eat or drink until normal sensation returns.



## CORRECTING SOFT TISSUE DEFICIENCIES PRIOR TO ESTHETIC DENTAL PROCEDURES



by Paul S. Petrunaro DDS, MS  
Chicago, IL  
North Oaks, MN  
www.petrungaro.com

### ABSTRACT

Adequate zones of attached, keratinized tissue are important for the periodontal health of the natural tooth system and surrounding bone. This principle becomes more significant in periodontal/prosthetic and cosmetic dental procedures. Additionally, in tooth replacement procedures, adequate zones of attached, keratinized tissue can lead to a healthy implant/gingival complex. Correction of deficient gingival tissues by either autogenous or allogenic tissue grafts has been well documented in the literature. This article describes acellular dermal tissue grafting in conjunction with correcting and altering the natural tooth system prior to the finalization of prosthetic procedures.

---

*Obvious advantages exist in utilizing acellular dermal matrix grafts.*

---

### INTRODUCTION

The esthetic enhancement of the natural dentition is a significant component of the contemporary dental practice. Proper zones of attached, keratinized tissue can lead to a balanced, harmonious gingival complex that can complement the ceramic alteration of the natural tooth, or tooth replacement with dental implants. In areas where there is a lack of attached keratinized tissue, in addition to root surface exposure, consideration must be given to correcting the deficient tissue contours prior to any tooth alteration and/or implant placement procedures. Various procedures to correct deficient gingival contours have been well documented in the dental literature.

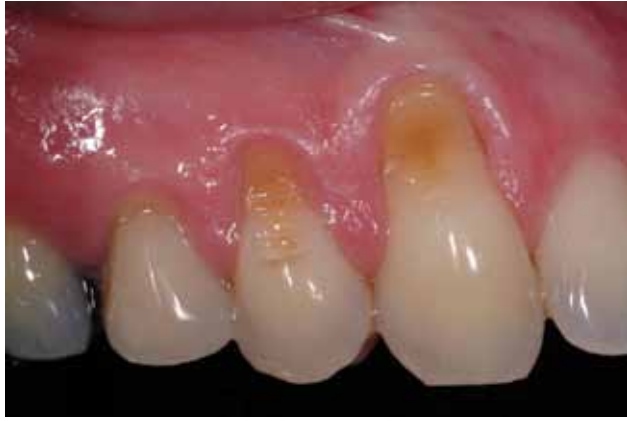

Figure 1: Preoperative view, maxillary right.

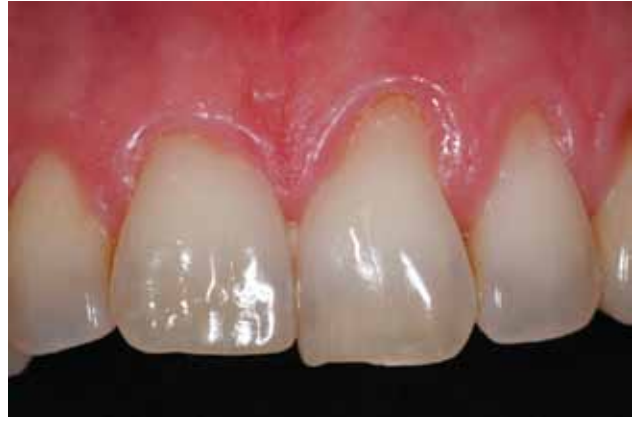

Figure 2: Preoperative view, maxillary anterior.

## REVIEW OF THE LITERATURE

The increasing of zones of attached gingival tissue using palatal donor tissue and the free gingival grafting procedure was introduced by Bjorn almost a half century ago.<sup>1</sup> Use of palatal donor tissue in the form of a free soft tissue autograft for root coverage procedures was reported by Miller.<sup>2</sup> Additional procedures were reported utilizing lateral<sup>3</sup> or coronal<sup>4-6</sup> repositioning of the adjacent attached gingivae via a pedicle flap, or the coronal repositioning of previous grafted tissue.<sup>7-8</sup> Miller also reported gingival grafts placed over root surfaces to correct areas of deep-wide gingival recession.<sup>9</sup> Further surgical advancements led to utilizing subepithelial connective tissue from the palate to obtain root coverage.<sup>10-11</sup>

One of the impediments to patients accepting soft tissue procedures to correct gingival loss is the trauma from harvesting palatal donor tissue. Depending on the volume of tissue required to correct the recession present, multiple harvesting procedures may be required. Also, an inadequate amount of connective tissue may be present, and

the patient's medical status may play a role in whether he or she is a good candidate for the palatal donor site surgery. As a result of some of these concerns, corrective gingival surgery expanded to the use of acellular dermal matrix grafts as a substitute for palatal connective tissue grafts.<sup>12</sup> Harris reported a comparative study of root coverage obtained with an acellular dermal matrix versus a connective tissue graft.<sup>13</sup> He observed no clinical or statistical difference between the two materials. Henderson and colleagues reported on predictable multiple-site root coverage using an acellular dermal matrix autograft,<sup>14</sup> with additional clinical documentation of dermal matrix grafts and their successful use in root coverage procedures.<sup>15-19</sup> Allen described a tunneling technique whereby a surgical pouch is created, the acellular dermal matrix is placed into the pouch, and the pouch is then coronally repositioned to cover the graft completely.<sup>20</sup>

Obvious advantages exist in utilizing acellular dermal matrix grafts. The avoidance of harvesting the palatal tissues is a major benefit to patients undergoing this type of treatment. For the surgeon, to have

unlimited amounts of tissue available and to be able to treat multiple sites at one surgical visit makes the surgical procedure more efficient. Furthermore, the high quality of the donor tissue, in addition to its natural esthetic appearance and patients' improved acceptance of therapy, makes this tissue an ideal replacement procedure for palatal soft tissue grafting.

## CASE REPORT

A 54-year-old non-smoking female presented for correction of deep, wide gingival recession in the maxillary anterior (Figs 1-3). The patient's desires were to correct the gingival recession, balance the heights of contour of the tissues, and possibly to undergo esthetic enhancement of the maxillary anterior with veneer restorations.

## TREATMENT PLAN

The treatment plan was to increase the zone of keratinized tissue in addition to root coverage in the maxillary anterior. The patient was given the option of utilizing her palatal tissue as a donor site, or the use of acellular dermal matrix tissue;

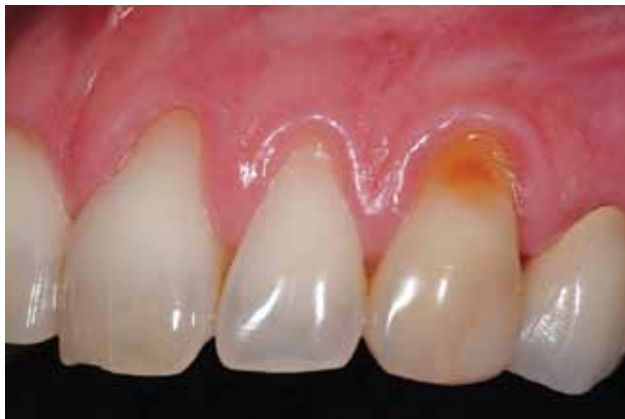

Figure 3: Preoperative view, maxillary left.

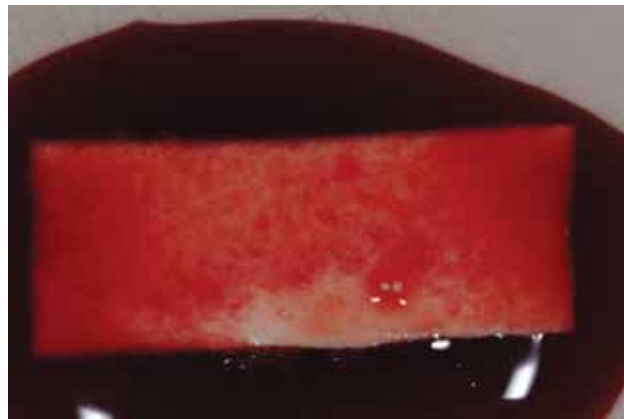


Figure 4: Acellular dermal matrix rehydrated and enriched with PRP.

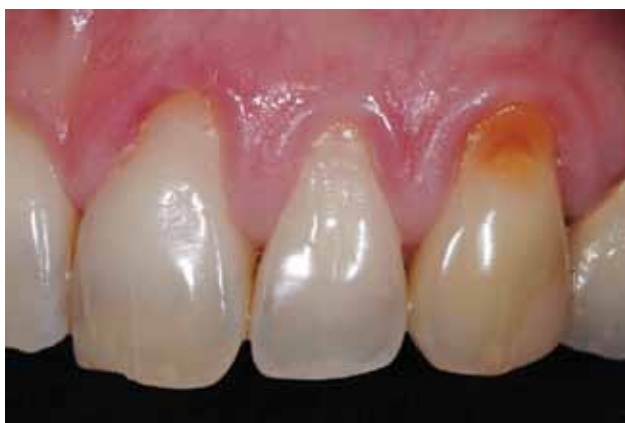

Figure 5: Root preparation, teeth #9-11.

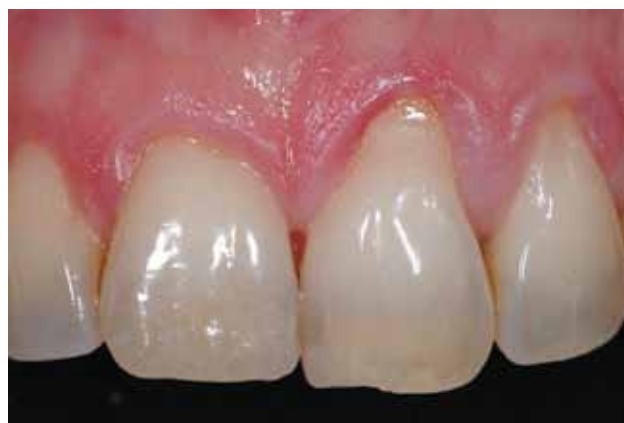

Figure 6: Root preparation, teeth #9, #10.

she opted for the latter as the graft to be utilized.

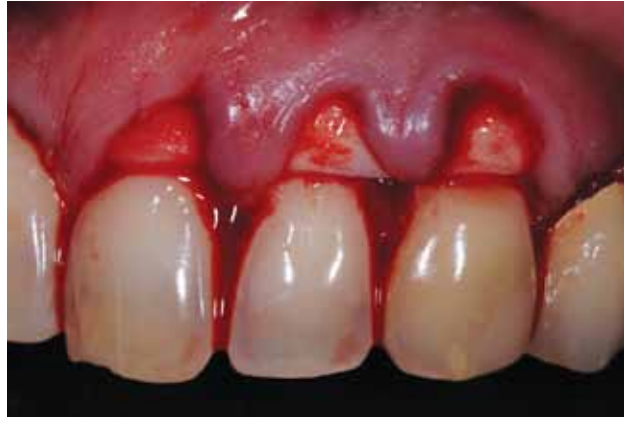#### TREATMENT

Following the technique outlined for fabrication of platelet-rich plasma (PRP),<sup>21</sup> blood was harvested from the patient's antecubital fossa, and the process was initiated. The dermal matrix tissue was then trimmed for each of the surgical sites to be treated. The horizontal dimension of the graft should extend 2 to 3 mm beyond the last tooth where recession is present at each end of the surgical site, where-

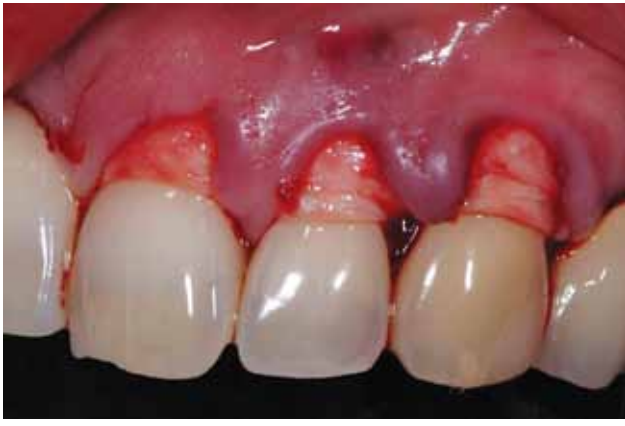as the vertical dimension should be 6 to 8 mm. Once the graft was properly trimmed and sized, it was submerged in a solution of non-activated PRP for rehydration. This was accomplished while the surgical site was being prepared (Fig 4).

After administration of an appropriate local anesthetic, root preparation was accomplished by scaling and root planing with hand instrumentation, and rotary instruments, followed by burnishing of the roots with 24% ethylene diaminetetra acetate (EDTA) and citric acid solution (pH1) (Figs 5 & 6).

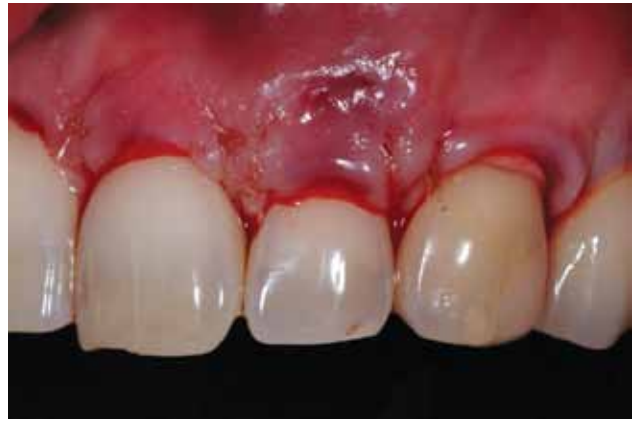Following the surgical technique previously referenced,<sup>20</sup> with modifications to the technique, intrasulcular incisions were made around each tooth to be treated (to a minimum of one tooth on each side of the affected teeth). The incision was not carried through the entire papillae apical to the contact point, being contained roughly between the mesial and distal line angle of each affected tooth. After the incisions were made, instruments to create a tunnel under each of the incised portions of the papillae were utilized to elevate the base of the papil-



*Figure 7: Acellular dermal matrix placed into "pouch."*



*Figure 8: Acellular dermal matrix secured.*



*Figure 9: Pouch coronally advanced and dermal matrix covered.*

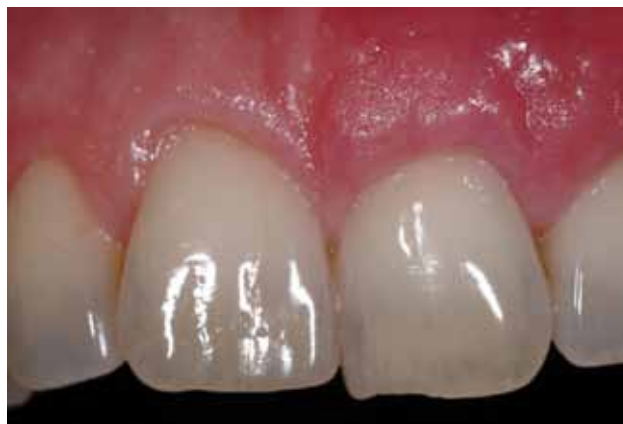lae. The pouch was then created by blunt dissection using a mucoperiosteal elevator, extending the reflection apically past the mucogingival junction, and laterally to the facial aspect of the tunneled papillae. Occasionally, the papillae may separate in this process, as occurred in this case. Deepening and mobilization of the pouch was then accomplished by sharp supraperiosteal dissection, which allowed for the pouch to be coronally advanced and to cover the dermal tissue completely.

The AlloDerm (Biohorizons Inc.; Birmingham, AL), which had been

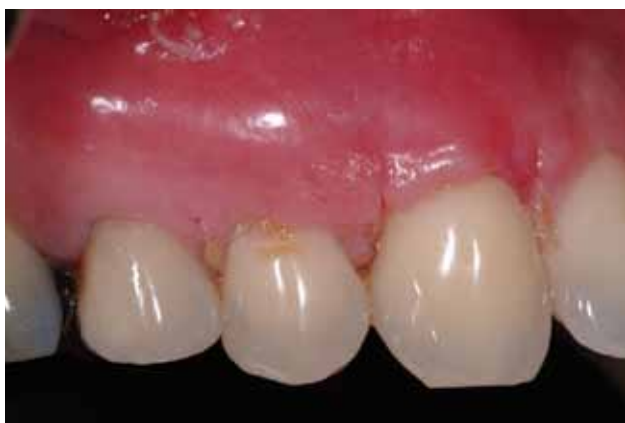rehydrated and enhanced with the non-activated PRP solution, was then placed into the surgical pouch with the basement membrane adjacent to the root surface (Fig 7). The dermal matrix was then secured with 6.0 polypropylene sutures (Ethicon; Sommerville, NJ) (Fig 8). The graft should be positioned at the cemento-enamel junction. The pouch was then coronally advanced to cover the dermal matrix graft completely; it can be secured with 5.0 Monocryl (Ethicon) or 6.0 polypropylene sutures (Fig 9).

The two-and-a-half week postoperative clinical view can be seen in Figures 10-12. Note the rapid soft tissue healing and maturation. At six weeks postoperative, tissue plasty was accomplished to blend the thickened keratinized tissue, in addition to placement of Class V composite restorations at teeth #5, #6, and #11 in order to create a new restorative margin on the root surfaces.

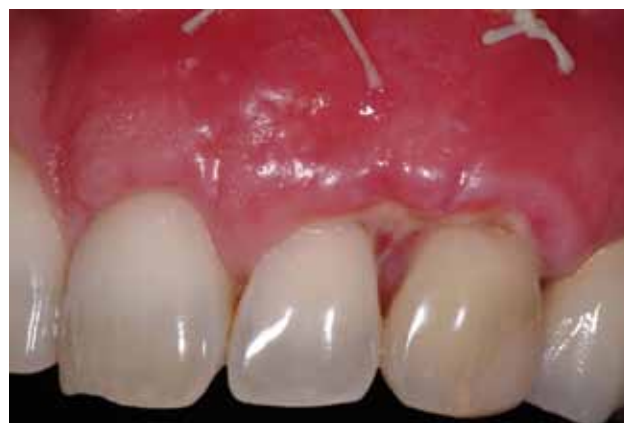The two-month postoperative view is shown in Figures 13-15. Please note the color match of the tissue, balance of the facial heights



*Figure 10: Two-and-a-half week postoperative view, maxillary anterior.*



*Figure 11: Two-and-a-half week postoperative view, maxillary right.*



*Figure 12: Two-and-a-half week postoperative view, maxillary left.*

of contour, and zones of attached keratinized tissue present.

## CONCLUSION

Adequate zones of keratinized, attached tissue are important for long-term periodontal health and maintenance. Restorative and/or cosmetic dental procedures benefit from having this type of periodontal environment. Soft tissue grafting and augmentation procedures have been developed and perfected over the last 30 years. Incorporation of acellular dermal matrix grafts have simplified the procedure and made

it more patient-friendly, allowing patients who have avoided palatal donor harvesting to have the procedure accomplished by using a safe and effective biomaterial. Acellular dermal matrix tissue has proven to be equal to palatal connective tissue for root coverage procedures in randomized, controlled clinical studies.<sup>12,16-19</sup> Tal and colleagues reported that the use of AlloDerm, under a coronally advanced flap, produces an esthetic outcome superior to that achieved with a palatal connective tissue graft.<sup>18</sup>

Dermal matrix grafting possesses distinct advantages over palatal con-

nective tissue due to the following factors:

- avoidance of the palatal donor surgical site
- multiple teeth can be treated at one visit
- unlimited amounts of donor tissue are available
- high quality of the donor tissue
- ability to match, or be superior to, the results observed with autogenous palatal tissue grafts.

Reestablishing the proper soft tissue quality prior to restorative intervention contributes to more predictable outcomes for tooth en-

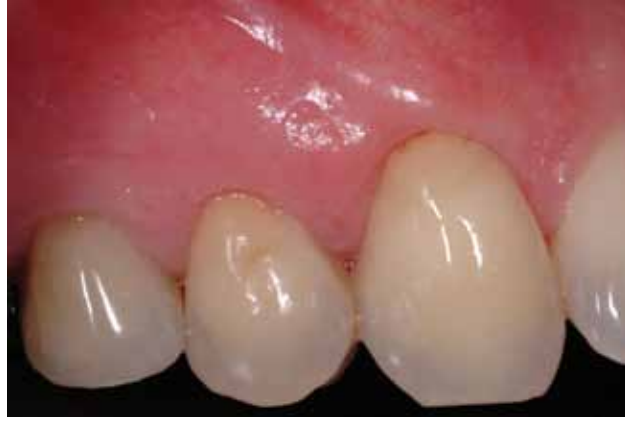

Figure 13: Two-month postoperative view, maxillary right.

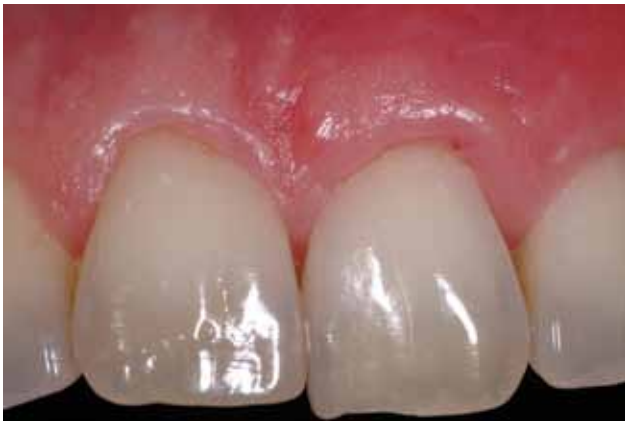

Figure 14: Two-month postoperative view, maxillary anterior.

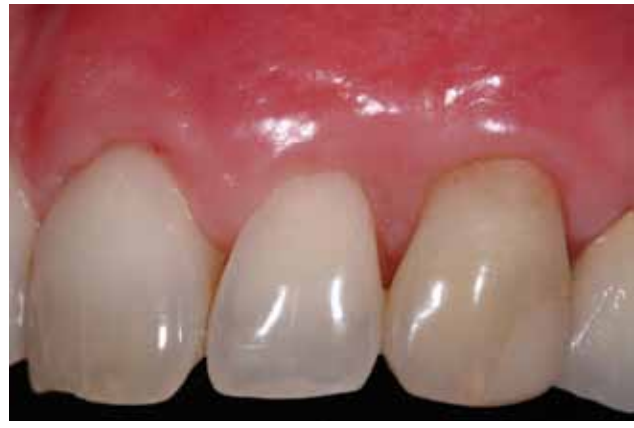

Figure 15: Two-month postoperative view, maxillary left.

hancement and replacement procedures. Dermal matrix grafts provide a safe, reliable option to palatal donor connective tissue.

#### References

1. Björn H. Free transplantation of gingival propria. *Sven Tandlak Tidsskr.* 1963;22:684-89.
2. Miller PD Jr. Root coverage using a free soft tissue autograft following citric acid application. Part I: technique. *Int J Periodont Rest Dent.* 1982;2:65-70.
3. Björn H. Coverage of denuded root surfaces with a lateral sliding flap. Use of free gingival grafts. *Odontol Revy.* 1971;22:37-44.
4. Guinard EA, Caffesse RG. Treatment of localized gingival recessions. Part III. Comparison of results obtained with lateral sliding and coronally repositioned flaps. *J Periodontol.* 1978;49:457-61.
5. Tamow DP. Semilunar coronally repositioned flap. *J Clin Periodontol.* 1986;13:182-85.
6. Allen EP, Miller PD Jr. Coronal positioning of existing gingiva: short term results in the treatment of shallow marginal tissue recession. *J Periodontol.* 1989;60:316-19.
7. Bernimoulin JP, Luscher B, Muhlemann HR. Coronally repositioned periodontal flap. Clinical evaluation after one year. *J Clin Periodontol.* 1975;2:1-13.
8. Matter J. Free gingival graft and coronally repositioned flap. A 2-year follow-up report. *J Clin Periodontol.* 1979;6:437-42.
9. Miller PD Jr. Root coverage using the free soft tissue autograft following citric acid application. III. A successful and predictable procedure in areas of deep-wide recession. *Int J Periodont Rest Dent.* 1985;5(2):14-37.
10. Raetzke PB. Covering localized areas of root exposure employing the "envelope" technique. *J Periodontol.* 1985;56:397-402.
11. Langer B, Langer L. Subepithelial connective tissue graft technique for root coverage. *J Periodontol.* 1985;56:715-20.
12. Cummings LC, Kaldahl WB, Allen EP. Histologic evaluation of autogenous connective tissue and acellular dermal matrix grafts in humans. *J Periodontol.* 2005;76:178-86.
13. Harris R. A comparative study of root coverage obtained with an acellular dermal matrix versus a connective tissue graft: results of 107 recession defects in 50 consecutively treated patients. *Int J Periodont Rest Dent.* 2000;20:51-9.

14. Henderson RD, Greenwell H, Drisko C, Regennitter FJ, Lamb JW, Mehlbauer MJ, Goldsmith LJ, Rebitski G. Predictable multiple site root coverage using an acellular dermal matrix allograft. *J Periodontol.* 2001;72:571-82.
15. Harris RJ. Root coverage with a connective tissue with partial thickness double pedicle graft and an acellular dermal matrix graft: a clinical and histological evaluation of a case report. *J Periodontol.* 1998;69:1305-11.
16. Paolantonio M, Dolci M, Esposito P, Lisanti L, Di Luccio A, Perinetti G. Subpedicle acellular dermal matrix graft and autogenous connective tissue graft in the treatment of gingival recessions: a comparative 1-year clinical study. *J Periodontol.* 2002;73:1299-1307.
17. Novaes AB Jr, Grisi DC, Molina GO, Souza SL, Taba M Jr, Grisi MF. Comparative 6-month clinical study of a subepithelial connective tissue graft and acellular dermal matrix graft for the treatment of gingival recession. *J Periodontol.* 2001;72:1477-84.
18. Tal H, Moses O, Zohar R, Meir H, Nemcovsky C. Root coverage of advanced gingival recession: a comparative study between acellular dermal matrix allograft and subepithelial connective tissue grafts. *J Periodontol.* 2002;73:1405-11.
19. Aichelmann-Reidy ME, Yukna RA, Evans GH, Nasr HF, Mayer ET. Clinical evaluation of acellular allograft dermis for the treatment of human gingival recession. *J Periodontol.* 2001;72:998-1005.
20. Allen EP. AlloDerm: an effective alternative to palatal donor tissue for treatment of gingival recession. *Inside Dentistry.* 2006;25(1):48-52.
21. Marx RE, Carlson ER, Eichstaedt RM, Schimmele S, Strauss J, Georgeff K. Platelet-rich plasma: growth factor enhancement for bone grafts. *Oral Surg Med Oral Pathol Oral Radiol Endod.* 1998;85(6):638-46.

### Acknowledgment

*The author thanks Dr. Steven Gorman of North Oaks, Minnesota, for his restorative excellence in the management of this case.*



# GET MORE.

Your pursuit for excellence begins in the American Academy of Cosmetic Dentistry. Get more. Become an active member.

*The American Academy of Cosmetic Dentistry is the world's largest non-profit, international membership association dedicated to advancing excellence in the art and science of cosmetic dentistry and encouraging the highest standards of ethical conduct and responsible patient care.*

www.aacd.com • 800.543.9220 • 608.222.8583



BE MORE.



# GIVE MORE.

The American Academy of Cosmetic Dentistry Charitable Foundation (AACDCF) is the philanthropic arm of the American Academy of Cosmetic Dentistry. It maintains four programs: the Give Back A Smile (GBAS) program, the GBAS Whitening Program, the Domestic Violence Intervention and Prevention program, and the AACDCF Disaster Relief Fund. Volunteers whose names appear in this advertisement have made an in-kind donation, monetary donation, and/or donated their time to the Foundation during the fiscal year 2008-2009.

[www.aacdcf.com](http://www.aacdcf.com) • 800.543.9220 • 608.222.8583



AMERICAN ACADEMY  
OF COSMETIC DENTISTRY

*A* *Ch* *a* *r* *i* *t* *a* *b*  
FOUNDATIC

3M • A Beautiful Smile Dentistry, LLC • Behzad Abadi, DMD • Tareq M. Abuzeq, DDS • Damon C. Adams, DDS • Mark W. Adams, DDS • Lawrence M. Addleson, DDS • ADL Dental Lab • Advanced Dental Concepts • Advanced Dental Lab • Advent Dental Lab • Leonid Agranat, DDS • M. Suzanne Ahnquist, DMD • Roya N. Akbar, DMD • Alan Jackson Fan Club • Stephen B. Alouf, DDS • Rick D. Alwan, DDS • Americus Dental Labs • Mira Andre, DDS • Steven B. Andreaus, DDS • Andre's Dental Studio • Karen F. Andrews, BDS • Wade B. Anshutz, III, DDS • Eric D. Arias, DDS • Brock D. Arms, DDS • Stanley D. Armstrong, DMD • J. Fred Arnold, III, DMD • Kara M. Arnold, DDS • Art 4 Your Practice • M Andrew Atwood, DDS • Margaret Atwood • Auger Dental Lab • Aurelle • Aurum Ceramic Dental Laboratories • Peter Auster, DMD • Joan Autran, DDS • Nasrin S. Azimzadeh, DMD • Susanne Inez Baaqee, DMD • Graeme I. Bacchus, BDS • Joan Baez • Richard Lyle Bailey, DDS • Elizabeth M. Bakeman, DDS • Joseph W. Baker, DDS • Gabor Balogh, DDS • Amerjote Bansal, DDS • Ronald Thomas Barganier, DMD • Dave Barry • Lindsay A. Barry, DDS • Bart Conner Educational Programs • Joyce L. Bassett, DDS • R. Brad Beasley, DMD • Paul E. Beavers, DDS • Anne Becker, DDS • J Alex Bell, DMD • Ira F. Berger, DDS • Neil D. Berman, DDS • Robert G. Berman, DDS • David Bernath • Daniel Bernstein, DDS • Mickey E. Bernstein, DDS • Thomas M. Bilski, DDS • William R. Birdwell, DDS • Jorge R. Blanco, DDS • David A. Blaustein, DDS • Kelly J. Blodgett, DMD • Joshua Bockian, DDS • Body Sense • Cheryl Bologna, DDS • Peter D. Boulden, DMD • John G. Boyd, DDS • Jennifer S. Bragg, DMD • Bramlett Crown & Bridge • Tina Brenza, DDS • Keith W. Brewster, DDS • Kelly D. Bridenstine, DDS • Ronald Joseph Briglia, DMD • Brittain's Dental Lab, Inc. • Matt Brock, DDS • Steven E. Brock, DDS • Vickie Lynn Brodersen, RDH • Scott W. Brodie, DMD • Brookfilms Limited • Steven H. Brooksher, DDS • Patrick J. Broome, DMD • Richard L. Brown, Jr., DDS • Karen Brune, DDS • Gretchen L. Bruso, RDH • Robyn Burchman • Rodney E. Burdette, DDS • Jeremy J. Burke, DDS • Robert R. Burks, DDS • Tyler R. Burningham • Ronald L. Burton, DMD • Jeffrey L. Buxton, DMD • John R. Calamia, DMD • Stacie T. Calian, DDS • Jefferson Call, DMD • Victoria C. Callicutt, DDS • Angela R. Cameron, DDS • Beata Campbell, RDT • David T. Cappetta, DMD • Michael L. Cariens, DMD • Arlene F. Caringal, DMD • Robert A. Carl, DDS • John A. Carletti, DDS • Dennis J. Carmody, DDS • George F. Carr, DMD • Angelle Casagrande, DDS • Jodi Case • Carmen B. Castillo, DDS • Anthony F. Castrogiovanni, DDS • Randall Caton, DDS • Beth A. Caunitz • Jerome Y. Cha, DDS • Joe S. Chafin, DMD • David K. Chan, DMD • Michael Chan, DDS • David C. Chang, BDS • Belen T. Chavez, DMD • Cary T. Chavis, DDS • Kari D. Chellis, DDS • Norman S.M. Cheung, DDS • Chicago Academy of Cosmetic Dentistry • Bert Chodorov, DDS • Malcolm M. Choy, DDS • Knox N. Christie, DDS • Richard A. Chwalek • Robert Ciccone, DDS • Valarie A. Cicrich, DDS • Mark L. Civin, DDS • Scott Clems • Kenneth W. Coffey, DDS • Douglas E. Cohen, DMD • Randall G. Cohen, DDS • Stacy V. Cole, DDS • Scott H. Coleman, DDS • Mark W. Collins, DDS • Mitch A. Condit, DDS • ContacEZ, Ideal Proximal Contact Solution • Anthony M. Cook, DDS • Christopher E. Cooley, DDS • Charles C. Cooper, DMD • Howard I. Cooper, DDS • Karen Cooper, DDS • Louis T. Core, DDS • Jack H. Corn, DMD • Philip Cornette, III, DMD • Cosmedent • Cosmetic Dentistry Center of Lexington • William J. Couvelis, DDS • Crawdaddy Productions • Steven J. Crawford, DDS • Richard N. Greasman, DMD • Crescent Products, Inc. • Wendy B. Crisafulli, DDS • John J. Cross, DDS • Fred R. Curcio, DMD • **YOUR NAME HERE** • D. H. Baker Laboratory • Bruno C. Da Costa, DDS • Justin J. D'Abadie, DDS • Stephen Dallal, DMD • Michael Dalton, DDS • Richard Wolfgang Davenport, DMD • Sherwin N. Davidson, DDS • Nicholas C. Davis, DDS • Spiker Davis, DDS • Amy Dayries, DMD • Melissa Daza, DDS • DCS Dental Lab • Clifford E. Degel, DDS • Orleans Del Carmen, DDS • Joseph F. DelPrete, DMD • Denmat Holdings LLC • Brian K. Dennis, DDS • Dental Ceramics • Dental Dimensions • Dental Health Group • Dental Innovation, Inc. • Dental Prosthetics • Dentistry by Design • John Derango, DDS • Derric D. DesMarteau, DDS • Declan J. Devereux, DDS • DeVreugd Dental Lab • Kevin C. Dickinson, DDS • Stacie L. Dietz • Nicholas J. DiMauro, DDS • Dimensions Dental Lab • Discus Dental • Neil F. DiSpirito, DDS • DMG America • Keri L. Do, DDS • DQCS Education • Michael G. Dolby, DDS • Lia Dominici-Bly, DDS • Jeffrey R. Dornbush, DDS • Susan Dotson • Timothy B. Dotson, DDS • Edward T. Dougherty, Jr., DDS • Shaun N. Dowd, DMD • Ralph M. Downey, DDS • Dr. Phil Show • Kathrynne M. Dryke, DDS • Duckee Lee Protech Dental Studio • Francis J. DuCoin, DMD • Thomas E. Dudney, DMD • Diana Dumitru, DDS • Joseph C. Duncan, DDS • Rick P. Durkee, CDT • David A. Durkin, DDS • Michael R. Durr, DMD • Natalia Duvalco, DDS • Gary S. Dworkin, DMD • Maja Dzudza, DDS • Ariana Ebrahimian • Eclipse Dental Lab • Stephen E. Edgerton, DDS • Lisa Elias, DMD • Peter A. Eliopoulos, DMD • Joe M. Ellis, DDS • Robert W. Erlach, DDS • Carl F. Ern, DDS • Malek H. Esrawi, DMD • Everest Publishing • Excel Dental Studios • Faircourt Dental • Tom Fallon, DDS • Anthony L. Falciano, DDS • Family Dental Clinic • Michei Fancelli, DDS • Gene S. Fang, DDS • Vicente Faus-Matoses, DDS • Sean M. Feely, DDS • Chuck Felts, DDS • Scott W. Finlay, DDS • Steven A. Firshein, DMD • Ann Elizabeth Fishel, DDS • Devin C. Fisher • Michael H. Fisher, DDS, CDT • Andrea S. Flamer, DDS • Denise Flanagan, DDS • Hugh D. Flax, DDS • Kevin Floyd, DDS • Fluid Dental Lab • Victor C. Foltz, DMD • Fonda, Inc. • Bryan G. Foote, DDS • Terry W. Forsberg, DDS • Michael K. Forth, DDS • Fox Dental Lab • Kevin R. Frawley, DDS • Karen E. Frazer, DDS • Daryl W. Frederick, DDS • Susan Fredericks, DDS • Cheryl G. Freeman, DDS • Patrick O. Freeman, DDS • The Freeman Center • John F. French, Jr., DMD • Frontier Dental Laboratories • Robert M. Fryer, DDS • Alexander Fu, DMD • Yoshio Fukushi, DDS • Raffaella Gabassi, BDS • Nick Gadler, DDS • Maria C. Galdiano, DMD • Jeffrey M. Galler, DDS • Armando Gama, DDS • Richard Gangwisch, DDS • Thomas B. Gatgens • Geoffrey M. Gaunt, DMD • Phil Gaus, DDS • Marilyn S. Gaylor, DDS • Daniel S. Geare • Anthony N. Giamberardino, DMD • Barry P. Gibberman, DMD • Dina Jackson Giesler, DDS • Brian J. Gilbert, DDS • Giving Tree LLC • Karen G. Glerum, DDS • Glidewell Laboratories • Eugene N. Goetz, DMD • Alan D. Gold, DDS • Andrew M. Goldsmith, DDS • Cary N. Goldberg, DDS • Gold Dust Lab • Jay H. Goldstein, DDS • Jerrold K. Goldsmith, DDS • Jeffrey Golub-Evans, DDS • Sandy Gonsalves • Tannaz T. Goodjohn, DDS • Ronald M. Goodlin, DDS • Dell Ariel Goodrick, DDS • John R. Gordon, DDS • Michael S. Gore, DDS • Joseph J. Gormly, III, DMD • J. Brent Gorrell, DDS • Paula S. Gould, DDS • Mary M. Govoni, RDH • Guy F. Grabiak, DMD • Kevin P. Grace, DMD • Maria Luisa Gracias, DDS • Gregory H. Grady, DDS • Paul G. Grandsire, DMD • Amy Grant • Ward F. Gravel, DDS • Randy J. Greenberg, DMD • Roy L. Greenberg, DDS • George L. Grein, DDS • Greystone Dental Arts • Marlo R. Griesser, DDS • Justin W. Griffin, DMD • Erika K. Grimm, DDS • Allan D. Gross, DDS • Todd R. Groen, DDS • Caryn A. Guba, DDS • Raul I. Guerra, DDS • Tony L. Guilbeau, DDS • Gregory L. Gullikson, DMD • Emily Guy • Miles A. Guyton, DDS • Kimberly S. Haas, DDS • Joseph Haddad, DDS • Jeffrey W. Hadley, DDS • Richard Hagstrom, DDS • Bradley S. Haines, DDS • Richard H. Haines, DMD • Andrew D. Hall, DMD • Lena T. Halikias, DDS • John S. Halmaghi, DDS • Kenneth M. Hamlett, DDS • Hammond Dental Lab • David J. Hanle, DMD • Paulo Hanna • Marshall W. Hanson, DDS • Craig E. Harris, DMD • Winifred J. Harris, DMD • Dennis B. Hartlieb, DDS • John H. Hartman, II, DDS • Paul Y. Hasegawa, DDS • Haupt Dental Lab • William E. Hay, DMD • Garrett T. Hayashi, DDS • Curtis O. Hayslip, DMD • Marty Everette Heesch, DDS • Michelle L. Hegeudus, DDS • Tina L. Heil, DMD • John Heimke, DMD • Roland D. Helfer, DDS • James F. Helmkamp, DDS • Scott Henning, DDS • Henry-Schweitzer • Dale Herrero, DDS • Tammy S. Herzog, DDS • Patricia E. Higgins, DDS • High End Ceramics • Jeffrey E. Himler, DDS • Howard G. Hindin, DDS • Satoshi Hirose • Ivan W. Ho, DDS • David Hobock Ronald J. Hoffer, DMD • Craig Holbrook • William J. Holevas, DDS • Hollandwood Smiles • Susan Hollar, DDS • Paul M. Holliday, DDS • Milt Holloway, DDS • Rowland S. Holsinger, DDS • Martin J. Hopf, BDS • John M. Hucklebridge, DDS • Michael E. Huguet, DDS • Corey J. Husu, DDS • Michael B. Hutchison, DDS • Manon B. Hutchison, DDS • Frank G. Hutton, DDS • Long T. Huynh, DMD • G. Earl Hydrick, DDS • Thomas D. Ince, DDS • Eugene F. Ingles, DDS • Integrity Dental Designs • Yoshinori Ishibashi • Aleksey Ivasenko • Mouaffaq A. Jaber, BDS • Noel W. Jackson, DDS • Bryan P. Jacobs • Paul J. Jacobs, DDS • Peter J. Jacobs, DDS • IAG Entertainment • Angela R. James, DDS • Bart L. James, DDS • Michelle M. Janbakhsh, DDS • Richard W. Janson, DDS • Shaun A. Janvier, DMD • Donald M. Jayne, DDS • Brenda K. Jennings, DDS • Howard P. Jensen, DDS • Jimenez Dental Studio • David Jin, DDS • Deborah A. Johann • R. Howard John, DDS • Robert E. Johnson, DDS • Ronald S. Johnson, DMD • Frances Anne Johnston, DDS • Krista M. Jones, DDS • Robert N. Jones, DDS • Bryan G. Judd, DDS • Joong-Hyun Jun, DDS • Jurim Dental Studio • Laura L. Justice, DMD • Donald M. Kahn, DDS • Michael R. Kaludy, DDS • Christian Kamaris, DMD • William T. Kane, DDS • Lester N. Kanemaru, DMD • Brian A. Kastner, DDS • Louis R. Kaufman, DDS • Keating Dental Arts • Michael K. Keating, DDS • J. Paul Keelan, DMD • Carla M. Keene, DDS • Neil Kelly, DDS • Phillip A. Kemp, DDS • Jennifer W. Kernagis, DMD • Jeffrey S. Kessler, DDS • Kettenbach • Fadi Khoury • Paul R. Kidman, BDS • John J. Killeen, DDS • Daniel S. Kim, DDS • Lisa Kimble, DDS • Debra Gray King, DDS • Laurie A. Kitson, DMD • Adam C. Kleiger, DDS • John D. Kling, II, DDS • Knight Dental Group • Robert L. Knudson, DDS • Victor A. Koehler, DMD • Keith M. Koga, DDS • Craig S. Kohler, DDS • Komet USA • Gregory L. Konotopetz, DMD • Michael E. Konrad, DMD • Harold Kopman, DDS • Sameet S. Koppikar, DDS • Olena I. Kopyova, DDS • John Koutsoyiannis, DDS • Elias Kouvalis, DDS • Lois A. Kovalchick, DDS • Kreyer Dental Prosthetics • Matthew J. Krieger, DMD • Nisha Krishnaiah, DDS • AnnaLee S. Kruyer, DDS • Albert J. Kurpis, DDS • Kuwata Pan Dent • Yoo Jong Kyun • William E. Lacey, DMD • Bruce J. Lachot, DDS • Robert D. LaCrosse, DDS • Lafayette Lab • Lake Area Dental Studio • Jean-Paul Lambert, LSD • Cecil Lambertson, DDS • David A. Landau, DDS • Kevin M. Landers, DDS • Rebecca J. Landman, DDS • Ralph Langer, CDT • Ryan Langer • Ira M. Langstein, DDS • Bertrand Larmoyer • Earl R. Larson, DDS • Las Vegas Esthetics • Les Latner, DDS • Rebeca J. Paul, DDS • Maria Le • Thomas G. Leatherman, DDS • Suzanna N. Lee, DDS • Legend Dental Technologies • Gerard J. Lemongello, Jr., DMD • Irving J. Leonard, DDS • N. Summer Lerch, DDS • Jay M. Lerner, DDS • Brian P. LeSage, DDS • Allen J. Levesque, DDS • Fredrick R. Lewcock, DDS • Garry L. Lewis, DDS • Guy M. Lewis, DDS • Linda Day Lewis, DDS • Stacy D. Lind, DMD • Ellis K. List, DDS • LK Dental Studio • Dean W. Lodding, DDS • Troy Lee Long, III, DDS • Long Island Anesthesia Physicians • Marcia A. Loo, DDS • Heber Lopes, DDS • Markus P. Lorch, DMD • Mark A. Luria, DDS • Lynch Dental Lab • Steven P. Lynch, DMD • Craig A. Mabrito, DDS • Mark C. MacGaw, DDS • Jeffrey Mader, DDS • Bogdan R. Madurowicz, DDS • Nicholas A. Maffeo, DMD • Maggio Porcelain Studio • Timothy G. Mahoney, DDS • Aziz A. Majid, DMD • Amjad Malik, BDS • Mike Malone, DDS • Ronald P. Malouf, DDS • Leslie Malueg, DMD • Edward T. Mamaril, DDS • Noor-Allah Manji, DMD • Francisco J. Marciano, DMD • Richard B. Marill, DDS • Robert N. Marshall, DMD • Jill A. Martenson, DDS • Greyc R. Martinez, DDS

• Jose M. Martinez, DMD • Rey Martinez, DDS • Jennifer M. Martinez-Amores, DMD • Caitilin R. Martini, DMD • David M. Mastro, DDS • Jose R. Matos-Perez, DMD • John W. Maynard, DDS • Pagan Mazaheri, DDS • John Shuford Rowe McAllister, DDS • Paul F. McAllister, DDS • MaryBeth McCabe, DMD • Michael P. McCarty, DDS • Mary Lynne McElhaney, DDS • Mark E. McGee, DDS • James G. McGhee, DDS • Carol A. McGonigle, DDS • Brian C. McGue, DDS • Debra C. McIntosh, DMD • Angela LM McKeefry, BDS • McKenzie Dental • Patrick R. McKnight, DMD • Douglas E. McMaster, DDS • Charles E. McMillian, DMD • Michael O. McMunn, DDS • Ron Mcoombs, DDS • Tara L. Meachum, DDS • Michael R. Meharry, DDS • Mike Mehlbauer, DMD • John Mennitt, DDS • James P. Merrett, DDS • James A. Merriman, DMD • Juan C. Mesia, DDS • Matthew J. Messina, DDS • Bob Meyers, DMD • Alberto J. Meza, DDS • The Miami Herald • Dennis J. Mihalka, DDS • Paul Mikhli, DDS • Diane Milberg, DDS • Ronald E. Mileham, DDS • Glenn J. Miller, DMD • Leslie C. Miller, DDS • Lorie Miller-Stevens, DMD • Kweon Suk Min, DDS • Robert S. Minch, DDS • Joseph M. Miranda, DDS • Microdental • David H. Mishler, DDS • Randy R. Mitchmore, DDS • Modern Methods • Allan S. Mohr, DDS • Tatyana P. Mokeyev, DDS • Timothy J. Molloy, DDS • Thomas W. Monahan, III, DMD • Rex Monif, DDS • Roberto E. Monteagudo, DDS • Marc L. Montgomery, DDS • Mark W. Montgomery, DMD • Phillip W. Moorad, DDS • Andrea Moore, DDS • Edward Moore, DDS • James M. Moran, DDS • James A. Moreau, Jr., DDS • Ray H. Morgan, DMD • Jeff Morley, DDS • Beverly T. Morris, DDS • Ronald P. Morris, DDS • Thomas O. Morse, DDS • Mouer Dental Lab • Sunshine Annette Mullins, DDS • Thomas J. Munroe, B.Dent.Sc. • Muth & Mumma • James M. Muzzi, DMD • Girija Nadarajan, DDS • Fujio Nagaoka, DDS • Kazuya Nakashima, DDS • Mohammad Nami, DDS • David G. Nangle, DDS • Bertrand WD Napier, BDS • Arun Narang, DDS • Julie R. Nathanson, DDS • Philip D. Nebeker • Alvin W. Neff, DDS • Alec C. Nelson, DMD • David E. Nelson, DDS • Peter B. Nelson, DDS • Neoss Inc. • Douglas G. Ness, DDS • Kenneth A. Neuman, DMD • New Creation Dental Studio • David R. Newkirk, DDS • New York Red Bulls • New York University Dental Center • New Wave Dental Studio • Next Generation Radiology • Tien K. Ngo, DDS • Alexander H. Nguyen, DDS • Anthony H. Nguyen, DDS • Jack Edgar Nicewander, DDS • Mark K. Nieh, BDS • Nilsson Dental Studio • Donald J. Nimz, DMD • Nobel Biocare • Byron J. Nordhus, DDS • Nancy A. Norling, DDS • Northwest Dental Arts • Northwest Dental Labs • Scott Norton, DMD • John R. Nosti, DMD • Nuance Dental Ceramics Inc. • Nucraft Dental Arts • Nu-Way • O'Brien Dental Lab • Sergio G. Ocampo, DDS • Georgios Oikonomopoulos, DDS • Lorna L. Okada, DDS • Wynn H. Okuda, DMD • Marshall S. Olech, DDS • Colleen M. Olitsky, DMD • Mary E. Oliverie, DMD • George M. Olsen, DDS • Bradley J. Olson, DDS • Douglas Peter Olson, DMD • Marie Louise Onesto, DDS • W. James Ongena, DDS • Thomas E. Oppenheim, DMD • Orange County Dental Lab • Orchid Dental Ceramics • Gerard T. Ortner, DDS • John M. Otrhalek, DDS • Garo Ourfalian, DDS • Glenda G. Owen, DDS • Claude K. Owens, DDS • Roy Oyangen, DMD • Page 1 Solutions • Charlie A. Palano, DMD • Arnold Palmer • Marc A. Panet-Raymond, DDS • William Papadopoulos, DMD • Nicholas T. Papapetros, DMD • Roshan P. Parikh, DDS, MBA • Yong J. Park, DDS • David E. Parker, DDS • Hubert H. Parker, IV, DMD • Scott Parr, DDS • Gilbert G. Parrott, DDS • Giuliana Partners • Dolly Parton • Vladimir Pastouk, DMD • Kunjan Patel, DMD • Paresh B. Patel, DDS • Patient News Publishing • James V. Penfield, DDS • Pentron Clinical Technologies • Perception Dental Lab • Ricardo M. Perez, DDS • Christopher Pescatore, DMD • Ted Peters, DDS • Thomas R. Peters, DDS • J Lee Pettigrew, DDS • Christopher C. Pham, DDS • George Phillips, DMD • T Gregory Phillips, DDS • Thomas J. Piccolo, DDS • Stephen Pickering, DDS • Shauna L. Pier, DDS • Gena E. Pineda, DDS • Jason B. Pittman, DDS • Albert Pizzi, DDS • Barry F. Polansky, DMD • Nicholas S. Polito, DDS • Anselum L. Pominville, DDS • Richard F. Porcelli, DDS • James V. Potter, DDS • Eric S. Powell, DDS • Donald J. Powers, DDS • James M. Poyak, DDS • Precision Dental Designs • Preferred Dental Ceramics • Prestige Dental Studio • Jeffrey G. Priluck, DMD • Pro-Art Dental Laboratory Ltd. • Prowest International Dental Labs • David Pumphrey, DDS • Lawrence J. Puccini, DDS • Solongo Purev, DMD • Steven G. Rabedeaux, DDS • Pat Rabot, DMD • Kelly Radcliff • John J. Radomile, Jr., DDS • Gary M. Radz, DDS • Rascal Flatts • Kenneth J. Rawlinson, DDS • Gregory B. Raymond, DDS • Recreations Dental Studio • Red Mountain Dental Lab • John L. Redd, II, DMD • Catherine G. Reimels, DDS • Steven Reiner, DMD • Pete Rendek, DDS • Lisa R. Rentschler, DDS • Pamela J. Reynolds, DDS • Fred E. Rich, DDS • Edwin M. Richardson, DMD • Melissa E. Rinck, DDS • Jack Ringer, DDS • Grant D. Ringler, DDS • Robert L. Rioseco, DMD • William B. Risk, DDS • H. Grant Ritchey, Jr., DDS • Harris L. Rittenberg, DMD • Roadside Multimedia • Daniel J. Robbin, DMD • Andrea L. Robbins, DDS • David Roberts, DDS • Erin Roberts • Stephen W. Robertson, DMD • Ginnylee Roderick, DDS • Kenny Rogers • Michael B. Rogers, DDS • Timothy D. Roney, DDS • Raymond Rophie, DDS • Randall Davis Rose, DDS • Fred M. Rosen, DDS • Thomas S. A. Rosenberg, DDS • Robert Rosenthal, DMD • James C. Ross, DDS • Joseph A. Rota, DMD • Rota & Smith Denial Center • Rota-dent • Robert J. Rother, BDS • Richard A. Rothwell, DDS • Stephen G. Roush, DDS • Marina Rubinshtein, DDS • Edward N. Russo, DMD • Robert Rybicki, DDS • Mitchell v. Sabbagh, DMD • Saber Dental Studio • Alan F. Saczawa, DMD • Sam S. Sadati, DDS • Mehdi Sadeghi, DDS • Aparna Sadineni, DDS • Khalil S. Saghezchi, DDS • Preet Khara Sahota, DDS • Kari L. Sakurai, DDS • Mirjan Salkovic • David Salomons, DDS • Michele Salonia, DMD • Keith M. Sanger, DDS • Catherine J. Santone, DDS • John Sartorio, DMD • Hiroko Sasabuchi • Christy Savas, DDS • Mark G. Sayeg, DDS • Matthew S. Scarberry, DDS • David A. Schaefer, DDS • Jonathan Scharf, DMD • Michael J. Scherb, DMD • Monica L. Scheurer, DMD • Eric S. Schikowski, DDS • William T. Schlosser, DMD • George J. Schmidt, DMD • Earl Marshall Schneider, DDS • David B. Schwartz, DDS • Sanford N. Schwartz, DDS • Boris Schwartzman • John L. Scott • Michael F. Scully, CDT • Amanda N. Seay, DDS • Sheldon Seidman, DDS • Jerry C. Sells, DMD • Parisa Sepehri, DDS • Servent • Michael R. Sesemann, DDS • Lucas B. Setiady, DDS • Buddy H. Shafer, Jr., CDT • Ty D. Shafer, DDS • Ramesh Shah, BDS • Mehdi Amirzadeh Shams, BDS • Arthur I. Shapiro, DMD • Edward I. Shapiro, DDS • C. Ray Sheppard, DMD • Raymond A. Sheridan, DDS • Karen F. Shibuya, DDS • Chris S. Sholota, DDS • Mark Shulman, DDS • Bryan A. Shumaker, DDS • Harris B. Siegel, DMD • John C. Sieweke, DDS • Signet Dental Lab • John W. Simmons, IV, DMD • Darren D. Simpson, DDS • Thomas M. Sims, DDS • Tarlochan Singh, DDS • Dan H. Singley, Jr., DMD • Sirona Dental Systems • Darce A. Slate, DDS • David R. Slater, DDS • The Smile Design Center • Smile Designs by Rego • Smile Vision Labs • Harold A. Smith, DDS • J. Edwin Smith, DDS • Ronald C. Smith, DDS • Roy A. Smith, III, DMD • Tim Smith, DDS • Alan M. Smolen, DDS • Mack Snead, DDS • Har-Simran K. Sodhi, DDS • Mohsen Solhjo, DMD • Somer Dental Lab • Lee J. Sorcinelli, DDS • James E. Sorge, DMD • Richard A. Sousa, DDS • Southern Craft Dental • Mark A. Sowell, DDS • Spalding Entertainment • Ryan D. Sparks, DMD • Eric H. Spellman, DMD • Spencer Dental Lab • Rhys D. Spoor, DDS • Rutger Sprengers • Bryan K. Springer, DMD • Celeste H. Springer, DMD • Springstone Patient Financing • Christopher R. Sprout, DDS • Robert E. Stafford, DDS • Fred C. Stalley, DDS • Angela S. Stathopoulos, DDS • Jerry L. Statman, DMD • Richard Steckler, DDS • Linda M. Steel, DDS • Robert E. Steele, DDS • Michael R. Steffen, DMD • Daniel L. Steinke, DDS • Stephen Park Dental Lab • Cynthia E. Stephenson, DDS • Fabiana R. Steren-Ofrit, DDS • David Stern, DDS • Christopher J. Stevens, DDS • Bruce A. Stewart, DDS • Nancy M. Stewart, DDS • Dennis J. Stiles, DDS • Pearse Stinson, BDS • Teresa C. Stiteler, DMD • Cloise Michael Stocking • Brenda Stong • Mary Sue Stonisch, DDS • Roumiana B. Stoycheva, DDS • Daniel B. Strader, DDS • Walter Whitman Strom, II, CDT • Kent D. Stuart, CDT • John K. Sullivan, DDS • Summit Dental Lab, LTD • Larry Sumrall, DDS • Jenny C. Sun, DDS • Suncoast Ceramic Studio • Sundance Laboratory • Paul I. Sussman, DMD • Ben A. Sutter, DMD • Erik P. Svans, DDS • William H. Swearingen, DDS • Mark W. Sweeney, DDS • Bernice Szafarek, DMD • Yoshitomo Takaishi, DDS • Richard D. Tallon, DDS • Sai Tamaki • Thomas T. Tang, DDS • Millie K. Tannen, DDS • Stephen P. Tassone, DDS • Elizabeth Taylor • James R. Taylor, DDS • Michael E. Taylor, DDS • Michael Teitelbaum, DMD • Rita Antonini Tempel, DDS • Christine Theroux, DDS • Texas Center for Cosmetic Dentistry • Phelan R. Thomas, DDS • Christopher J. Thompson, DMD • Dan H. Thompson, DDS • Steven P. Thompson, DDS • John Derek Ticken, DDS • Ann D. Tobin, DDS • Rodrick G. Toms, DDS, BSc • Toothwerks • Garry S. Tous, DDS • Louis J. Traci, DDS • John Tran, DDS • Olga N. Tran, DDS • Treasure Dental Lab • Treasure Dental Studios • Thomas F. Trinkner, DDS • Triodent Corporation • Tripple Porcelain Laboratory, Inc. • James L. Tritton, DDS • Troy Aikman Foundation • Dale R. Trudeau, DDS • The Trump Corporation • Kristoffer J. Tumilowicz, DMD • James E. Turley, DDS • Turner Enterprises • Ultimate Styles • Ultradent Products • University Dr. Dental Studio • University of Pacific • University of Wisconsin-Madison • Valley Dental Arts • Galen R. Van Blaricum, DDS • Richard W. Van Gorp, DDS • Dr Kurt Van Winkle, DDS • Andrew G.H. Vance, BDS • James V. Vecchio, DDS • Vector Management • Ossie R. Vereen, CDT, MDT • Kevin D. Verrett, DDS • Michael S. Vetter, DMD • Dora Vilk-Shapiro, DMD • Kirk Vincent, DDS, LC • Daniel R. Vodvarka, DDS • John W. Vollenweider, DMD • Christian-Axel Von Rosenbach, DDS • Candace M. Wada, DDS • Jurgen Wahlmann, DMD • Sandeep Walia • Clifford A. Walker, DMD • Michael Vincent Wall, DDS • Nicholas P. Wall, DDS • Andrew J. Wallace, BDS • Cristin M. Wallace, DDS • Rusty Wallace • Gary V. Walton, DDS • Curt Warren, DDS • Everett B. Watson, Jr., DDS • James E. Watson, DDS • Robert W. Webster, DDS • Steven D. Wegner, DDS • James A. Weisman • Steven Weinstein • James R. Welland, DDS • Jeffrey A. Weller, DDS • Dennis Wells • Welu Dental Lab • Betty White • Johnathan Robert White, DDS • Kerri L. White, DDS • John Whittemore, DDS • Christer Wihlborg, DDS • Corky Willhite, DDS • Brad Williams, DDS • Kenneth W. Williams, DDS • Michele Y. Williams, DMD • Timothy Williams, DDS • William Williams, DMD • Treva E. Willis, DDS • Christopher M. Wilson, DDS • Sean S. Wilson, DDS • Tom Wilson, DDS • Jack T. Winchester, DMD • Gerald M. Winkler, DMD • Laura E. Wittnauer, DDS • George Wolfe • Michael A. Wong, DDS • Gary R. Woodall, DDS • C. Macdonald Worley, Jr, DMD • Fred F. Worrall, DDS • Gregory B. Wright, DDS • Thomas Wright, Jr., DDS • Lynn R. Wuthnow, DDS • C. Lee Wyant, DDS • Gregory J. Wych, DDS • Eleni Xenidou • Anthony R. Yamada, DDS • Manami Yamaguchi, DMD • Andrew W. Yap, DDS • Kenneth T. Yasuhara, DDS • Carter S. Yokoyama, DDS • Yonsei La Dental Clinic • Pearl H. Zadeh, DDS • Nazy Zahedi, DDS • James H. Zarafonetis, DDS • Frank S. Zarkowsky, DDS • Marty Zase, DMD • Robert B. Zavada, DDS • Zenith Dental/DMG • April L. Ziegele, DDS • Henry J. Zielinski, Jr., DDS • James R. Zonghetti, DMD

Together, we recognize those affected by domestic violence and intervene to help restore lives by restoring smiles. Together, we support dental colleagues in times of devastation. Together, our contributions are remarkable. Together, we are the American Academy of Cosmetic Dentistry Charitable Foundation.

# JOURNAL of Cosmetic Dentistry

## GUIDELINES FOR SUBMITTING A MANUSCRIPT

---

The following guidelines have been provided to assist potential authors in writing and in submitting manuscripts to the *Journal of Cosmetic Dentistry (JCD)*. Please follow these instructions to help ensure efficient processing of your manuscript.

Original manuscripts submitted to *JCD* are accepted subject to the understanding that they are submitted exclusively to the *Journal* and will not be reprinted without written consent from the publisher.

The *Journal of Cosmetic Dentistry* is aimed primarily at practicing cosmetic dentists and laboratory technicians. Clinical, clinical research, and case study manuscripts are considered for publication. Material should be prepared with short sentences, simplicity of wording, and high-quality supporting visual material. Editorial alterations may be made to correct grammar, clarify meaning, and make the text consistent with the *Journal's* style. All manuscripts are peer-reviewed by the *JCD's* Editorial Review Board through a double-blind review process.

Please follow these guidelines for manuscript submission:

- Submit one laser-quality original hard copy of the manuscript, accompanied by a CD or DVD containing the electronic version.
- Include the author's name(s), address(es), telephone and fax numbers, and e-mail address on a cover sheet. Do not put the author's name on the manuscript itself; this will aid in keeping authorship anonymous when the editorial board reviews the manuscript.
- Authors may not have more than two articles published in the *Journal* within a 12-month period, unless it is part of an already-accepted series.

- If the paper was presented before any organized group, include the name of the organization and the date and place the paper was delivered.
- An image of the author must be submitted. A minimum resolution of 300 ppi is required.

### MANUSCRIPT PREPARATION

In preparing an article for submission, please follow these guidelines:

**Format:** Manuscripts must be submitted on CD or DVD, along with an original laser-quality hard copy. Use only one side of the paper and number pages consecutively.

**Spacing/Length:** All copy must be double-spaced and submitted on 8 1/2" x 11" paper. Manuscripts of 1,500 to 2,500 words will be considered for publication. Margins should be 1" around the document.

**Paragraphs:** Indent at least five spaces or insert a tab to identify a paragraph.

### TEXT

Please follow these guidelines:

- Number pages consecutively.
- Organize manuscripts in a manner that best fits the specific goals of the article.
- Use standard headings in preparing clinical manuscripts—abstract, introduction, case report, diagnosis, treatment plan, discussion, and conclusion.
- Include an abstract of approximately 100 words summarizing the article.
- Refer to past issues of *JCD* for examples of proper text format.

## REFERENCES

**Authors are responsible for ensuring the accuracy of all information in their references.**

- A minimum of 10 references should be included with clinical manuscripts.
- References must be cited in the text (numbered consecutively in superscript). Do not “embed” references in the manuscript—simply type them in a list at the end of the article.
- Include references only to published work that directly pertains to statements made in the article. Do not include works that were used only as a general bibliography.
- Authors may not reference their own work unless it pertains directly to their own original research.

## IMAGES

Manuscripts should be accompanied by images (no more than 25) that reflect the article’s content and purpose. The *Journal* reserves the right to edit the number of images, if necessary. Please limit captions to 25 words.

When considering images to accompany your article, keep in mind the following:

1. Are all the images necessary (i.e., do they enhance the text)?
2. Do all the images make sense in relation to the text?

**Do not** embed images (photos, graphs, etc.) into the manuscript—send all images separately to the Director of Publications. **Do not** submit images in PowerPoint or in a Word document.

All images must be mentioned in the text, **in numerical order**. A caption list must accompany the manuscript, with a caption listed for each image.

### • QUALITY

The quality of photographs submitted contributes directly to the quality of their reproduction in the *Journal*. The quality of images accompanying any article submitted to *The Journal of Cosmetic Dentistry* must meet the current AACD standards. If you have questions on what is acceptable, refer to the AACD’s *Photographic Documentation and Evaluation in Cosmetic Dentistry: A Guide to Accreditation Photography* for the approved standards.

Digital images will be accepted for publication. Excellent print quality require images with a minimum of 300 ppi (high-resolution) with an appropriate output size (at least 3” wide). Limit the number of images submitted to adequately illustrate the article (maximum of 25). When submitting **digital images**, please use JPEG format. Digital illustrations should not be altered.

### • LINE DRAWINGS/GRAPHS

Keep the figures, charts, and graphs simple, with lettering large enough to read; a maximum of three per article. These must be professionally designed or computer-generated and ready for publication. Art must be in a vector format, a minimum of 300 ppi, and a minimum of 3” wide.

## AUTHORSHIP REQUIREMENTS AND DISCLOSURES

An Authorship Requirements and Disclosures Statement will be sent to the author upon receipt of the manuscript and must be signed and returned before the review process begins. Authors may submit the form with the manuscript by requesting it in advance. The form requires authors to disclose authorship responsibility, statement of financial disclosure, and copyright transfer to the AACD. A manuscript will not be published unless this form has been signed by the author and returned to the AACD Executive Office.

## REPRINTS

A small number of complimentary copies of the *Journal* are available to authors. At an additional charge, reprints of specific articles (four-color only) are available and can be ordered through the AACD Executive Office. Authors may order additional copies of complete journals for an extra charge if the order is placed before press time.

These requests for standardized submission of materials are necessary for ease and accuracy of publication. The Editorial Review Board looks forward to your submission. Communication regarding your expected date of submission would greatly help the publishing staff, as considerable long-range prepublication planning is necessary.

Please mail your manuscript to:

*Journal of Cosmetic Dentistry*  
AACD Executive Office  
5401 World Dairy Drive  
Madison, WI 53718

## ADVERTISING INDEX

AACD 2010 Winter Regional	www.aacd.com	119
AACD Annual Scientific Session 2010	www.aacd.com	30
AACD eLearning	www.aacd.com	66
AACDCF Whitening Program	www.aacd.com	79
Aurum Ceramic Dental Laboratories	www.aurumgroup.com	77
Cosmedent	www.cosmedent.com	91
Crescent Products	www.crescentproducts.com/dental	90
Csapo Dental Arts	www.csapodentalarts.com	95
daVinci Dental Studios	www.daVinci.com	13
DiaDent	www.DiaDent.com	19
Discus Dental	www.discusdental.com	IFC
Envision A Smile	www.EnvisionASmile.com	105
Evolve Dental Technologies	www.KORwhitening.com	25
Give Back A Smile	www.givebackasmile.com	136
Golden Proportions Marketing	www.goldenproportions.com	7
Heraeus	www.heraeus-kulzer-us.com	33
Ivoclar Vivadent	www.ivoclarvivadent.com	41, IBC
MicroDental Laboratories	www.macveneers.com	BC
NADL	www.nadl.com	109
Novalar Pharmaceuticals, Inc.	www.novalar.com	127
Patient News Publishing	www.patientnews.com	9
Rhonda Mullins Consulting, Inc.	www.RhondaMullins.com	103
Springstone Patient Financing	www.springstoneplan.com	51
Utah Valley Dental Lab	www.utahvalleydentallab.com	57
Valley Dental Arts	www.valleydentalarts.com	61

**FOR ALL YOUR MARKETING AND SPONSORSHIP NEEDS, PLEASE CONTACT:  
JEFF ROACH, DIRECTOR OF STRATEGIC PARTNERSHIPS AT JEFFR@AACD.COM OR 608.237.8827.**

### Advertising Deadlines

Issue	Space Reservation	Ad Material
Winter 2010	December 1, 2009	December 14, 2009
Spring 2010	January 18, 2010	February 1, 2010

Shift up to  
**SpeedCEM™**



SpeedCEM... For the fast, efficient cementation of IPS e.max® restorations.

**SpeedCEM™**  
Self-Adhesive Resin Cement

Developed specifically for high-strength ceramic restorations such as IPS e.max lithium disilicate, as well as metal, metal-ceramic and zirconia restorations, SpeedCEM features patented adhesion promoters eliminating the need for additional dentin/enamel primers or bonding agents.

**Request a FREE sample\* of SpeedCEM today!**  
Log on to [www.ivoclarvivadent.com/SpeedCEMsample](http://www.ivoclarvivadent.com/SpeedCEMsample)



100% CUSTOMER SATISFACTION  
GUARANTEED!

[www.ivoclarvivadent.com](http://www.ivoclarvivadent.com)

Call us toll free at 1-800-533-6825 in the U.S., 1-800-263-8182 in Canada.  
©2009 Ivoclar Vivadent, Inc. SpeedCEM and IPS e.max are trademarks of Ivoclar Vivadent, Inc.  
\*Offer valid in the USA and Canada only, while supplies last. Requests must be received by 11/30/09.  
Limit one per office. Ivoclar Vivadent reserves the right to cancel this promotion at any time.

**ivoclar  
vivadent:**  
passion vision innovation

ORTHOTICS · WAX-UPS · MACVENEERS™ · COMPOSITES · LAVA™ · PFM

© 2009 D11 Dental Technologies, Inc.

MAC has always embraced a *passion* for life-changing dentistry. Many clinicians around the world have partnered with us to *empower* their practice and their patients.

Experienced in all occlusion philosophies, our technicians can tailor to each unique smile story. Partner with us to elevate your practice *beyond the ordinary*.

MAC. A SMILE FOR EVERY STORY™

LYAH BIESING IS A MACVENEERS PATIENT. DENTISTRY BY DR. MITCH CONDITT, FORT WORTH, TX.

800.229.0936  
DUBLIN · CALIFORNIA  
LAS VEGAS · NEVADA  
VANCOUVER · BC

MACVENEERS™  
BY MICRODENTAL TECHNOLOGIES

[www.macveneers.com](http://www.macveneers.com)

MAC  
BY MICRODENTAL LABORATORIES