Materials You Cannot Work Without

Refining Your Tools for Treatment

John O. Burgess, DDS, MS

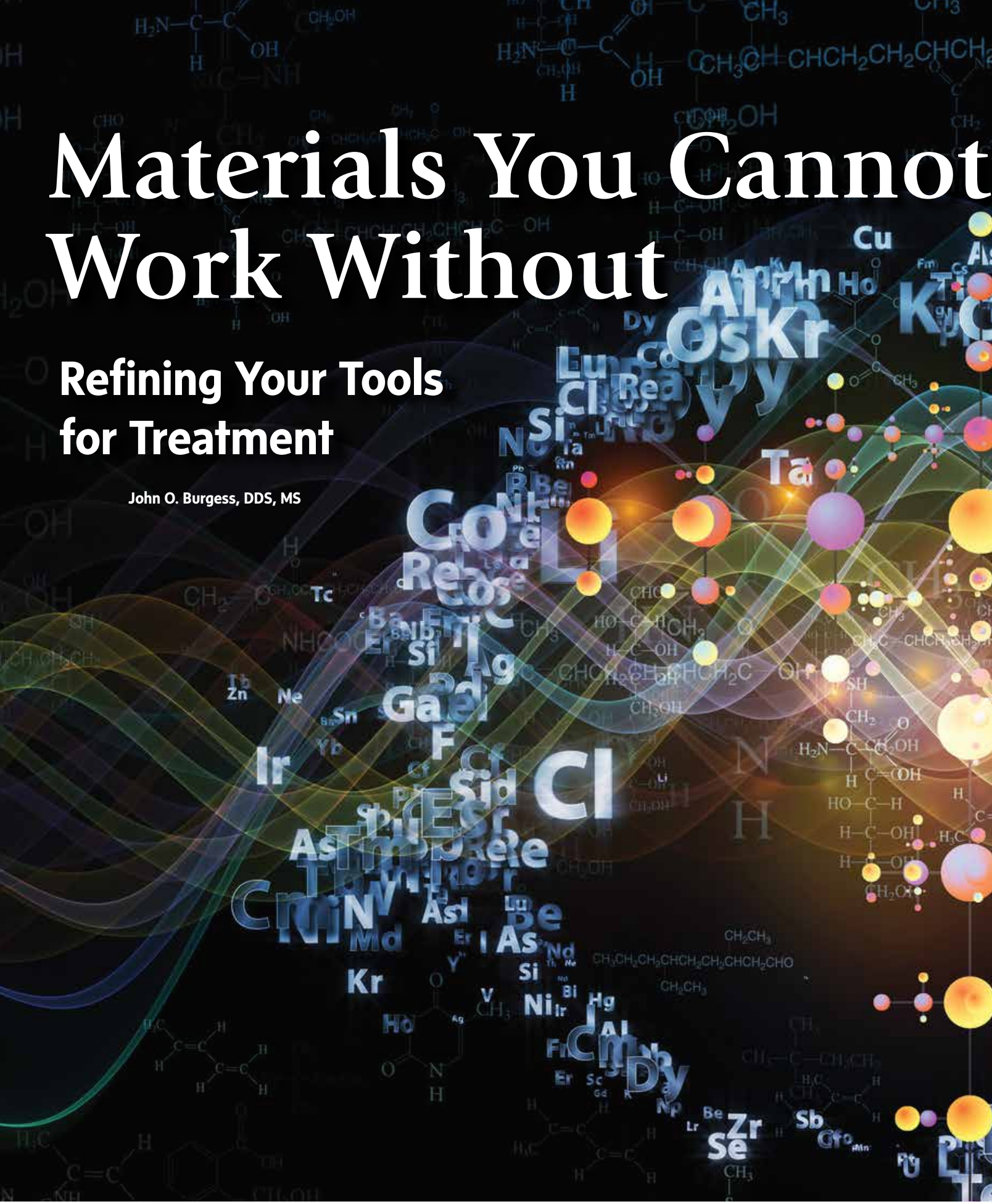

Abstract

Dental materials are constantly evolving and improving. This article evaluates materials from several product classes that have significantly improved properties that will help the busy practice improve care, shorten treatment time, and preserve oral health. Beginning with the newest adhesive (the Universal adhesives), materials are compared and two are recommended. These adhesives bond direct and indirect restorations by producing a low film thickness and all can be applied using a total-etch, self-etch, or selective etch technique. Composite resin can now be bulk-filled and cured to depths of 4 to 5 mm. These promising restorative materials may shorten placement time yet provide successful, durable esthetic composite resin restorations. Vital pulp therapy includes direct and indirect pulp-capping procedures. Two new calcium silicate materials, Biodentine and TheraCal LC, are useful for vital pulp therapy and provide an effective seal, higher strength, and lower cost than older materials. Maintaining restorations is difficult and it is difficult to provide preventive materials that are effective, especially for patients suffering from dry mouth. Preventive materials containing a combination of calcium, phosphate, and fluoride seem to provide the minerals necessary for remineralization and are especially useful for xerostomic patients.

Key Words: Universal adhesives, bulk-filled composite resins, vital pulp-capping materials, preventive materials

Introduction

Material development has produced significant advances for the practice of clinical dentistry. This article describes several classes of restorative materials with potential to change your practice of dentistry by improving and protecting the restorative treatment, and decreasing treatment time.

Universal Adhesives

Scotchbond Universal Adhesive (3M ESPE; Seefeld, Germany) was the first "universal" single-bottle adhesive. Currently, Scotchbond Universal, All-Bond Universal (Bisco; Schaumburg, IL), and Prime and Bond Elect (Dentsply Caulk; Milford, DE) are available, with more sure to be marketed **(Fig 1)**. Universal adhesives can be applied using a total-etch, self-etch, or selective-etch technique. Total-etch and self-etch systems have been used with different adhesive systems for years, but the selective-etch procedure is a relatively new concept in which the enamel is etched with phosphoric acid and rinsed, followed by applying the self-etching adhesive to the enamel and dentin. Universal adhesives have a higher pH than traditional adhesives **(Table 1)** and consequently most bond to etched enamel better than unetched enamel. Many self-etching adhesives produce lower bond strengths to phosphoric acid etched dentin. When a self-etching adhesive is applied to cut dentin, etched intentionally or unintentionally, bond strengths to the etched dentin are reduced. A selective-etch technique applies phosphoric acid etchant to enamel and sclerotic dentin and, after rinsing, the adhesive is applied to etched enamel and unetched dentin, agitated, dried, and cured. Two "universal" adhesives (Scotchbond Universal and All-Bond Universal) contain a phosphate monomer that allows them to bond to multiple substrates. Scotchbond Universal contains silane to bond to ceramic without a separate silane application. During our testing we discovered that hydrofluoric acid provides most of the bond strength to ceramic, with silane providing an additional smaller bond. Bonds with Scotchbond Universal to glass-containing ceramic are improved when a coat of silane is applied to the ceramic surface. Scotchbond Universal bonds directly to zirconia and alumina oxide abraded metal. All-Bond Universal will bond to zirconia but requires a separate application of Z-Prime (Bisco), a phosphate-containing monomer **(Fig 2)**. Two of the currently marketed "universal" adhesives (Scotchbond Universal and Prime and Bond Elect) use a dual-cured activator with chemical or dual-cured cements, core materials, or composites. While little is known

Figure 1: Three Universal bonding agents: Scotchbond Universal, All-Bond Universal, Prime and Bond Elect.

Figure 2: Z-Prime is a phosphate-containing monomer that is required when using All-Bond Universal to bond to zirconia.

about the clinical durability of these adhesives, we are conducting a clinical trial with Scotchbond Universal and have had no loss of retention after the six-month recall to restored noncarious cervical lesions. We are completing one-year recalls at this time with no loss of retention or marginal discoloration in the restored teeth.

Bulk-Filled Composite Resins

Stress

Polymerization shrinkage in composite resins has decreased to .9 to 2.7% for highly filled composites, whereas flowables range from 3.1 to 6.7%. Shrinkage stress produced by the polymerization of composite cured in cavity preparations has also declined.[1] Although these terms are frequently used interchangeably, free shrinkage is not the same as the stress or force produced during polymerization, which causes margin fracture and pulls cusps together. During finishing of the composite, fine particles of composite fall into the cracks produced by shrinkage stress, causing a white line to be seen around the restoration. As polymerization shrinkage and the stress produced during polymerization decreased, so has white line formation. Various methods have been used to control the stress, which tears enamel, composite, or the adhesive. Curing lights with ramp, soft, and pulse delay curing modes evolved but, unfortunately, these approaches to controlling polymerization shrinkage proved clinically ineffective in reducing marginal adaptation or marginal staining in clinical studies.[2,3]

Shrinkage and Strain

The C factor (ratio of bonded to unbonded surfaces in the preparation) and compliance (the ability of the remaining tooth to bend) determines the strain produced to the marginal areas by the shrinking composite resin.[4] Class I and Class V preparations have the greatest bonded-to-free surface ratio (5:1) and composite resin cured in these preparations produces the greatest strain. When a composite resin is irradiated with blue light from a curing unit, photons activate the photo-initiator (usually camphoroquinone), which initiates free radical polymerization of the composite. As the composite resin forms a polymer, it changes from a viscous gel to an elastic solid. During the polymerization process, as monomer links together to form a polymer, the polymer eventually stretches from one side of the preparation to the other side. As the modulus increases in the developing polymer and the chain stiffens, stain to the surround-

> “Universal adhesives can be applied using a total-etch, self-etch, or selective-etch technique.”

Table 1: Comparing Universal Adhesives.

	Scotchbond Universal	Prime and Bond Elect	All-Bond Universal
Low film thickness	5-7 µ	3-5 µ	< 10 µ
Compatible with chemical and dual-cured composites?	no, needs dual-cure activator	no, needs dual-cure activator	yes, no dual-cure activator needed
pH	2.7	2.5	3.2
Solvent	ethanol	acetone	ethanol
Refrigeration required?	no	recommended	no

ing tooth structure occurs. This stage in the polymerization reaction is called the *gel point*. Before the gel point, the developing polymer can flow from any free surface. On a Class I restoration, for example, this results in a meniscus on the occlusal surface. However, as the polymer continues to cross link the gel point is reached where the stress (force) created from the developing polymer creates strain (deformation) to the surrounding tooth, pulling tooth cusps together and deforming the marginal interface. Shrinkage occurs due to reduced molecular vibration of the units forming the polymer and is determined in large part by the filler volume of the composite, the degree of conversion of the monomer, and the amount of diluent added to the composite resin, which influence the amount of stress formed.

An incremental placement and curing of 2-mm layers of composite has been used since the late 1980s, but current work demonstrates that the strain developed while curing 2-mm increments of composite resin is similar to curing 4-mm increments in bulk-placed composites.[5] Many curing methods have been advocated to control or reduce polymerization shrinkage, including three-site polymerization, trans-enamel polymerization, ramp or soft curing and pulse delay; however, these methods were examined in a 2005 study[6] that reported that these different light-curing methods produced reduced shrinkage by a modest decrease in the final conversion rates of the composite resin.

Low and High Viscosity

Bulk-fill composites can be classified into two types: low and high viscosity. Low-viscosity materials like Venus Bulk Fill (Heraus Kulzer; Hanau, Germany), Filtek Bulk Fill (3M ESPE), and SureFil SDR (Dentsply Caulk) **(Figs 3a-3c)** are placed in 4-mm increments, have lower filler rates, and most wear more than highly filled composites.[7] Low-viscosity composites are generally used as dentin replacement layers or are recommended for small occlusal restorations. The first bulk low-viscosity flowable, SureFil SDR, covered the 4-mm layer of bulk-filled and cured SDR with a wear-resistant composite "enamel layer" to provide wear resistance of the restoration. This enamel layer produces the same polymerization strain as other composites. High-viscosity bulk placement materials such as Tetric EvoCeram Bulk Fill (Ivoclar Vivadent; Amherst, NY) and SonicFill (Kerr; Orange, CA) handle like highly filled composite resins, can be used to restore large preparations, and have 4-mm depths of cure depending upon the shade and curing light used. The most

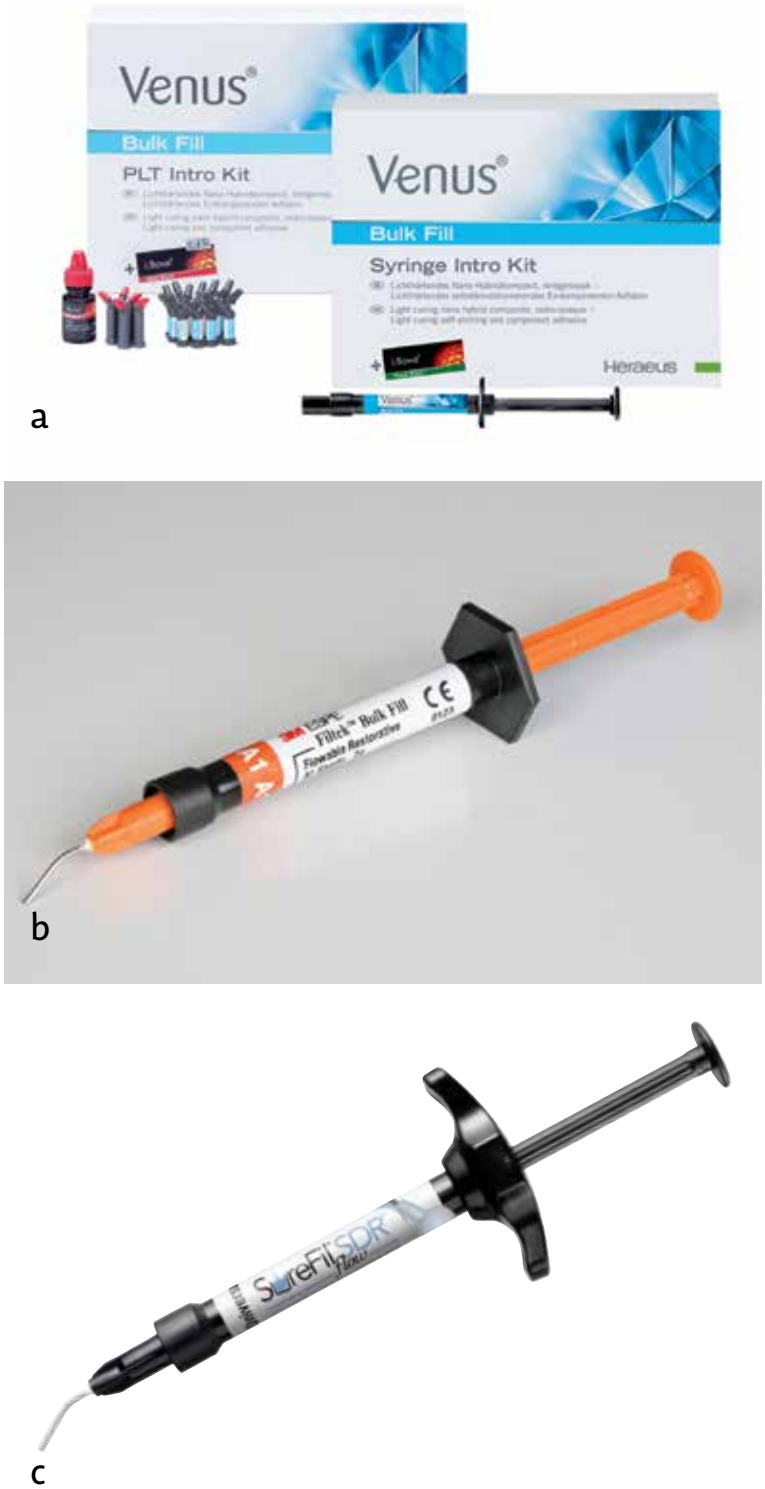

Figures 3a-3c: Low-viscosity bulk-fill composites.

Academy of General Dentistry™

Tune Up in Tennessee!

Join us for the Academy of General Dentistry (AGD) 2013 Annual Meeting & Exhibits, June 27 to 30, 2013, at the brand-new Music City Center in Nashville, Tenn.

Get an entire year's worth of continuing education (CE) in one great location.
This year's educational program includes:

- "Smile Design, Esthetic, and Occlusal Techniques," with Gerard J. Chiche, DDS
- "Treatment Planning the Worn Dentition," with John C. Cranham, DDS, PC
- "What's Wrong with My Pictures? Tips and Tricks for Great Patient Photographs," with Rita Bauer

Learn more and register today at
www.agd.org/nashville

In addition to the hottest topics in CE, your registration for the AGD 2013 Annual Meeting & Exhibits includes:

- "Death's Acres: Life as a Forensic Anthropologist," the opening session with keynote speaker William Bass III, PhD, founder of "The Body Farm" and co-author of the best-selling Body Farm mystery novels
- Presidential Concert: A Night at the Ryman Auditorium, an intimate evening at the historic Nashville venue featuring a special musical guest
- Access to the latest in dental products and technologies from hundreds of exhibitors

To learn more about the meeting, follow us on Facebook and Twitter! Look for #TuneUpYourCE.
See you this summer in Music City!

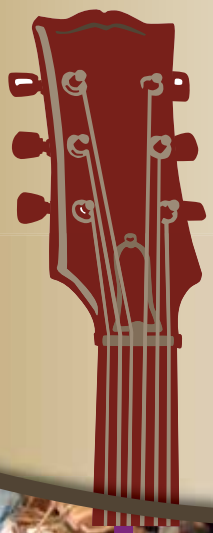

Tune Up in Tennessee!
AGD 2013 Annual Meeting & Exhibits
June 27 to 30, 2013
NASHVILLE

commonly used method to increase the depth of cure of a composite is by increasing composite translucency, which allows light to penetrate further. The depth of cure with bulk-filled composite resins can be achieved by adding additional camphoroquinone but this imparts a yellow color to the composite. Adding new photo-initiators like Ivocerin (Ivoclar Vivadent) increased the depth of cure for Tetric EvoCeram Bulk Fill, while combining this with a photo-inhibitor creates adequate working time. Although little clinical information is available on bulk-placed and cured composite resins, we have completed a three-year clinical examination of 100 SureFil SDR with very good clinical results. At this time the recommended low-viscosity bulk-fill resin is SureFil SDR **(Figs 4-7)**, while EvoCeram Bulk Fill is the choice for high-viscosity bulk-filled materials **(Figs 8-10)**.

Vital Pulp-Capping Materials

Vital pulp therapy is often used with direct and indirect pulp-capping procedures. Direct pulp-capping procedures are 10 to 15% less effective than indirect pulp-capping procedures. The most effective materials used for these procedures are calcium hydroxide-releasing materials like Dycal (Dentsply Caulk) or ProRoot MTA (Dentsply Tulsa Dental Specialties; Johnson City, TN). Recently, two new calcium silicate materials, Biodentine (Septodont; Lancaster, PA) and TheraCal LC (Bisco), similar in composition to MTA with sustained calcium hydroxide release, have been introduced. Both have lower cost than MTA and Biodentine has better mechanical properties than MTA.[8] According to our tests Biodentine has significantly greater compressive strengths at 35 minutes, 24 hours, and 28 days than Dycal or MTA. Biodentine can be placed directly over an exposed pulp and used to seal the cavity up to the cavosurface margin for six to seven months since it has approximately the same wear resistance as glass ionomer **(Figs 11-14)**. Biodentine is a powder/liquid system with the powder supplied in an amalgam-like capsule. The liquid is placed into the capsule and the mixture is triturated for 10 seconds. The capsule is removed and the material scooped out and placed directly over the exposed pulp. Biodentine's delivery is difficult and the 10-12 minute setting time before the material can be finished is significant. However, Biodentine's durability, seal, and effectiveness are impressive. Its durability allows the vital pulp procedure clinical time to determine whether it will be successful. TheraCal LC is a light-cured calcium silicate **(Fig 15)** that can be placed directly over the exposed pulp and light-cured in 1-mm increments.

Figure 4: Carious lesion on mesial occlusal (MO) #2.

Figure 5: Preparation, MO #2.

Figure 6: SDR and EsthetX initial placement.

Figure 7: Three-year recall on MO #2 (SDR and EsthetX HD).

Figure 8: Defective amalgam.

Figure 9: Preparation.

Figure 10: Completed Tetric EvoCeram Bulk Fill restoration.

Figure 11: Biodentine.

Figure 12: Exposure visible on #14.

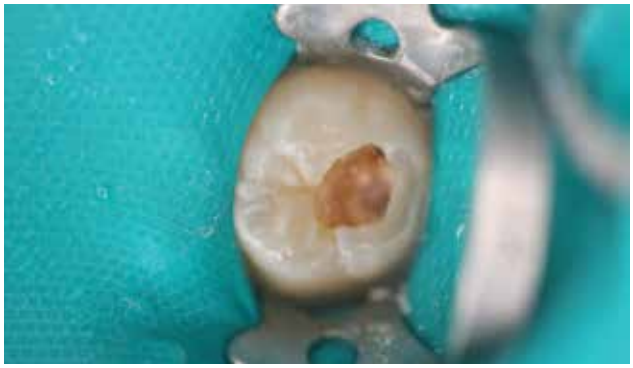

Figure 13: Biodentine placed over the exposure to seal the cavity.

Figure 14: Biodentine-sealed direct pulp cap at seven months.

Figure 15: TheraCal LC.

Generally this material is used as a base. Since it has a limited depth of cure it can be placed over the exposed pulp and a restorative material is placed over it. The TheraCal LC delivery system is the easiest of the calcium silicate materials to use due to its efficient syringe placement and is light-cured. Both TheraCal LC and Biodentine, like all calcium hydroxide-releasing materials, upregulate mesenchymal cells to form odontoblasts and stimulate new dentin formation. Both materials are very useful in an active clinical practice.

Preventive Materials

Caries Prevalence

Caries is the most common dental disease and the focus of preventive dental materials and strategies. Caries incidence and severity in the United States has been followed using the National Health and Nutrition Examination Survey (NHANES) and the National Institute of Dental and Craniofacial surveys using variations of the decayed, missing, and filled index.[9,10] The most current NHANES survey,[10] conducted between 1999 and 2004, reported that by age six, 51% of primary teeth were affected with dental decay. Dental caries affects 96% of adults aged 50 to 64 and root caries affects 21% of adults aged 50 to 64. These reports clearly demonstrate that our fight against tooth decay is not over.

Incidence of Recommended Preventive Measures

A survey of practitioners enrolled in Dental Practice-Based Research Network asked dentists to identify the percentage of their patients to whom they had administered or recommended dental sealants, in-office or at-home fluoride, chlorhexidine rinses, or xylitol gum.[11] The survey reported that 84% of children and 36% of adult patients received in-office fluoride, and 69.5% of children and 13.6% of adult patients received sealants. Xylitol gum was recommended to 8% of the children and 17.3% of the adults. Chlorhexidine rinse was prescribed to 35% of the children and 32.2% of adult patients. This demonstrates that a wide range of products and procedures are recommended as adjuncts for controlling caries; and one, xylitol, has recently been reported as ineffective in the adult.[12]

Risk Assessment

Clinicians should conduct a caries risk assessment to determine if a patient is at risk. For high caries-risk subjects, clinicians should weigh the balance between benefits and risks prior to implementing any preventive strategy. Because a patient's risk for caries can change, the form should be updated by assessing the subject's caries risk frequently. Only then will the dentist be able to accurately determine which preventive treatment to select. For patients with dry mouth, more than fluoride[13] is needed to reverse the demineralization produced by acid secreted by plaque bacteria using sucrose as an energy source. The secreted lactic acid removes calcium and phosphate from the tooth, producing a subsurface white spot lesion, which ultimately cavitates as the lesion progresses. Mi Paste™ Plus with RECALDENT™ (CPP-ACP)(GC America; Alsip, IL) and Clinpro 5000 (3M ESPE) **(Figs 16 & 17)** contain calcium, phosphate, and fluoride, which rematerialize dematerialized tooth structure by supplying the components necessary for remineralization.[14] Fluoride is necessary for remineralization but in salivary-deficient individuals, little calcium and phosphate is present in the saliva; this limits remineralization and makes calcium- and phosphate-containing preventive materials particularly useful. These materials can best be applied with a toothbrush, by tray, or by simply applying the paste directly to the teeth with a finger just before bedtime. They should not be rinsed after applying.

Lesion Treatments

Lesion treatments for enamel caries focus on remineralization using topical applications of fluoride or amorphous calcium phosphate and emphasizing oral hygiene procedures. However, the success of these treatments is dependent upon the patient's compliance, which is especially difficult in the proximal areas where plaque removal is difficult. Typically, most small proximal lesions observed are located entirely in enamel and only preventive measures are recommended rather than restoration of the lesion unless the lesion progresses. If the lesion continues, a larger lesion frequently develops. As the restoration breaks down, new caries forms around the restoration and the cycle of restoring and replacing the failed restoration begins. The restoration enlarges each time it is replaced until the tooth needs an indirect restoration. As these treatments progress through the life cycle of the tooth, the tooth pulp may be exposed; this often requires either extraction or root canal therapy. Both the loss of tooth structure and its replacement, or endodontic treatment and tooth restoration, involve multiple appointments and considerable expense. A procedure that neither depends upon patient compliance nor increases the lesion size would be a micro-invasive treatment such as resin infiltration of the subsurface lesion. A surface-infiltrating resin has been developed (Icon, DMG America; Englewood, NJ) to treat these small enamel or early dentin lesions **(Figs 18 & 19)**. The infiltration technique is a noninvasive system requiring no irreversible removal of tooth structure and eliminates drilling and most pain associated with tooth restoration. Evidence is building that this system stops or slows proximal carious lesion progression. A 2010 study[15] evaluated the effectiveness of resin-infiltrated carious proximal lesions for 18 months using standardized radiographs and digital subtraction. The researchers concluded that a resin infiltration into the inner half of enamel or the outer third of dentin is an effective way

Heraeus

Venus®

Family of Composites

The New Standard of Care.

With its unique monomer chemistry, the Venus line of composites offers an unprecedented combination of low shrinkage stress, high durability, and superior handling for esthetic brilliance without compromise. One proven chemistry, three viscosities — for all of your restorative needs, Venus Diamond, Venus Pearl, and Venus Diamond Flow may be used together or individually for long-lasting esthetic solutions.

PURCHASE 5 Refills of Venus branded composites
RECEIVE 2 of the same **FREE!**
1000804142

*Includes Venus Diamond®, Venus Diamond® Flow and Venus® Pearl.

TO REDEEM FREE PRODUCTS: Purchase products from an authorized Heraeus dealer on one invoice between 1/1/13 and 3/31/13. Write campaign code on your invoice and fax it to (877) 271-5211. Invoices can also be mailed to Heraeus, Attn: Free Goods Fulfillment, 300 Heraeus Way, South Bend, IN 46614. Invoice must be received by 4/30/13. All offers subject to change. Not to be combined with any other offers. Please allow 6–8 weeks from receipt of invoice for delivery. OFFER EXPIRES 3/31/13. *Refill equivalent is syringe or 20-pack PLT. Venus,® and Venus Diamond® are trademarks of Heraeus Kulzer GmbH.

Venus®
The New Esthetics

Figure 16: MI Paste Plus.

Figure 17: Clinpro 5000.

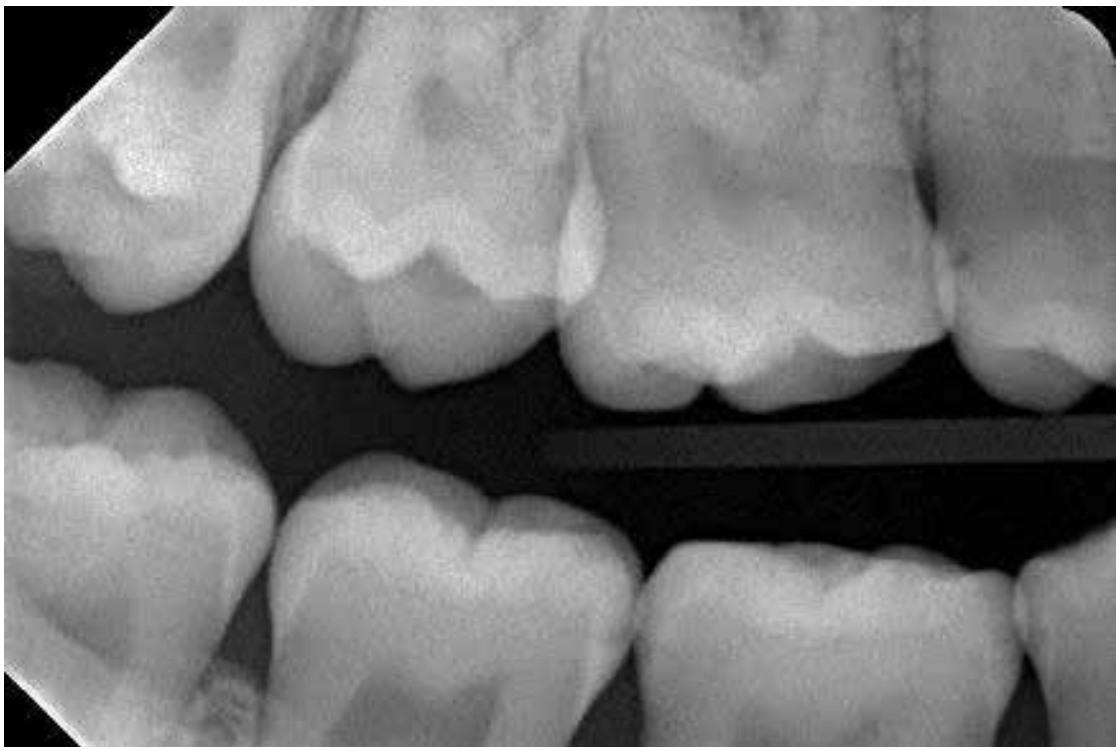

Figure 18: Mesial #31 and distal of #30—lesions that may be treated with Icon.

to reduce carious lesion progression. Another recent study,[16] using a radiographic comparison technique, reported that a caries-infiltrating resin was a more effective method for treating proximal enamel lesions than sealing or flossing over a two-year period. A third 2010 study[17,18] compared resin infiltration and fluoride varnish to fluoride varnish alone in primary molars after one year and concluded that resin infiltration and fluoride varnish was 35% more effective than fluoride varnish alone. These studies demonstrate that the resin-infiltration system may be a viable option for treating small carious lesions without relying upon patient compliance and with little patient discomfort.

Icon infusing resin is similar to a sealant and is applied to small carious lesions on the proximal and facial surfaces of teeth etched with hydrochloric (HCL) acid. This infusing resin penetrates and arrests the carious lesions. The tooth is isolated with a rubber dam, the proximal lesion is separated from the adjacent tooth and the HCL etch is applied for four minutes. After rinsing, the HCL etchant, Icon dry, an alcohol solution, is applied to remove excess water. This is dried and the Icon resin is applied **(Fig 20)**, light-cured, reapplied, and cured. Any excess resin is removed with scalers and disks.

Figure 19: Icon system for treating Class II lesions.

Figure 20: Applying the Icon infusing resin.

Conclusions

This is an exciting time in dentistry as new materials and techniques evolve that improve and simplify restorative dentistry. Universal adhesives (Scotchbond Universal, Prime and Bond Elect, and All-Bond Universal) promise to simplify bonding by using only one material for direct and indirect restorations and providing a substantial bond to ceramics, metal, and tooth structure. Bulk-filled composite resins shorten the time required to produce excellent esthetic posterior composite resin restorations. When bulk-filled composites are paired with "universal" adhesives, a simplified delivery system is produced that simplifies staff training. The ability to stimulate new tooth structure with calcium silicate materials like Biodentine and TheraCal LC may save teeth condemned to extraction. These vital pulp therapy materials are durable and, at a minimum, provide a longer evaluation time before electing to restore or provide root canal treatment for the compromised tooth. Preventive materials have moved from fluoride applications to pastes containing calcium, phosphate, and fluoride. Calcium concentration may be the most important element for remineralization of demineralized tooth structure. Both MI Paste™ Plus and Clinpro 5000 contain these essential building blocks for the tooth and are extremely helpful when treating the salivary-deficient patient.

References

1. Cakir D, Sergent R, Burgess JO. Polymerization shrinkage—a clinical review. Inside Dent. 2007;3(8):84-7.

2. Burgess, JO. Commentary on: Marginal adaptation and hardness of resin composite restorations activated by four energies. J Esthet Restor Dent. 2005;17(5):311.

3. Burgess, JO, Walker, RS, Porche, C, Rappold, A. Light curing—an update. Compend Contin Educ Dent. 2002;23(10):889-906.

4. Feilzer AG, De Gees AJ, Davidson CL. Setting stress in composite resin in relation to configuration of the restoration. J Dent Res. 1987;66:1636-9.

5. Shashank G, Beck P, Cakir D, Lemons J, Burgess J. Polymerization shrinkage strain produced by composite resins [abstract]. J Dent Res. 2013. Abstract no. 1115. IADR Seattle, WA.

6. Lu H, Stansbury JW, Bowman CN. Impact of curing protocol on conversion and shrinkage stress. J Dent Res. 2005;84(9):822-5.

7. Sawlani K, Beck P, Ramp LC, Cakir D, Burgess JO. In vitro wear of eight bulk placed and cured composites [abstract]. J Dent Res 2013. Abstract no. 174833. IADR Seattle, WA.

8. Bentley K, Janyavula S, Cakir D, Beck P, Ramp L, Burgess J. Mechanical and physical properties of vital pulp therapy materials [abstract]. J Dent Res. 2012. AADR Abstract no. 876.

9. Beltrán-Aguilar ED, Barker LK, Canto MT, Dye BA, Gooch BF, Griffin SO, Hyman J, Jaramillo F, Kingman A, Nowjack-Raymer R, Selwitz RH, Wu T. Centers for Disease Control and Prevention (CDC). Surveillance for dental caries, dental sealants, tooth retention, edentulism, and enamel fluorosis—United States, 1988-1994 and 1999-2002. MMWR Surveill Summ. 2005 Aug 26;54(No. SS-3):31-43.

10. Dye BA, Tan S, Smith V, Lewis BG, Barker LK, Thornton-Evans G, Eke PI, Beltrán-Aguilar ED, Horowitz AM, Li CH. Trends in oral health status: United States, 1988-1994 and 1999-2004. Vital Health Stat. 2007:11(248):1-92.

11. Riley JL 3rd, Gordan VV, Rindal DB, Fellows JL, Williams OD, Ritchie LK Jr, Gilbert GH. General practitioners' use of caries-preventive agents in adult patients versus pediatric patients: findings from the dental practice-based research network. J Am Dent Assoc. 2010;141(6):679-87.

12. Bader JD, Vollmer WM, Shugars DA, Gilbert GH, Amaechi BT, Brown JP, Laws RL, Funkhouser KA, Makhija SK, Ritter AV, Leo MC. X-ACT Collaborative Research Group. Results from the Xylitol for Adult Caries Trial (X-ACT). J Am Dent Assoc 2013;144(1):21-30.

13. Rozier RG, Adair S, Graham F, Iafolla T, Kingman A, Kohn W, Krol D, Levy S, Pollick H, Whitford G, Strock S, Frantsve-Hawley J, Aravamudhan K, Meyer D. Evidence-based clinical recommendations on the prescription of dietary fluoride supplements for caries prevention: a report of the American Dental Association Council on Scientific Affairs. J Am Dent Assoc. 2010;141(12):1480-9.

14. Walsh LJ. Evidence that demands a verdict: latest developments in remineralization therapies. Australasian Dent Pract. 2009;Mar/Apr:48-59.

15. Paris S, Meyer-Lueckel H. Infiltrants inhibit progression of natural caries lesions in vitro. J Dent Res. 2010;89(11):1276-80.

16. Martignon S, Tellez M, Santamaría RM, Gomez J, Ekstrand KR. Sealing distal proximal caries lesions in first primary molars: Efficacy after 2.5 years. Caries Res. 2010;44:562-70.

17. Ekstrand KR, Bakhshandeh A, Martignon S. Treatment of proximal superficial caries lesions on primary molar teeth with resin infiltration and fluoride varnish versus fluoride varnish only: efficacy after 1 year. Caries Res. 2010;44(1):41-6.

18. Martignon S, Tellez M, Ekstrand K, Lara JS, Gomez J, Cortes A. Progression of active initial-proximal lesions after infiltration, sealing or flossing instructions. J Dent Res. 2010;89:2519. **jCD**

> "The ability to stimulate new tooth structure with calcium silicate materials...may save teeth condemned to extraction."

Dr. Burgess is the assistant dean for clinical research, University of Alabama at Birmingham School of Dentistry.

Disclosure: Dr. Burgess receives grants/research support from 3M ESPE, Dentsply Caulk, GC America, Ivoclar, DMG, Kuraray Noritake, and VOCO.