Myths vs. REALITIES

Feldspathic Stacked Porcelain Veneers *and* Pressed Porcelain Veneers

Dario Adolfi, DDS, CDT
Mauro Fradeani, DDS

As responsible clinicians and ceramists, we are constantly searching for the best treatment options to deliver high-quality restorations to our patients. We all strive to create a delicate balance between hard and soft tissue for a synergistic outcome. New materials make it increasingly possible for us to present less invasive alternatives. In a quest for answers, the *jCD* asked distinguished educators Dr. Dario Adolfi and Dr. Mauro Fradeani to share their thoughts regarding the myths and realities of feldspathic stacked porcelain veneers and pressed porcelain veneers. Their comments will enlighten you, either providing another way of looking at this topic, or confirming what you already believe.

> **One of the advantages of this material is the potential to obtain high-quality restorations that achieve a perfect harmony between soft and hard tissues.**

Dr. Adolfi Dispels Myths Regarding Feldspathic Stacked Veneers

The use of laminate veneers is among the most documented approaches in the dental literature for improving smiles. One of the advantages of this material is the potential to obtain high-quality restorations that achieve a perfect harmony between soft and hard tissues. This is due to the physical properties of the ceramic, which remains stable over time—even inside an environment as adverse as the oral cavity. To achieve success and stability, bonding procedures must be planned and conducted carefully, leading to a perfect sealed interface between the tooth and ceramic.

To achieve a bonding interaction between dental hard tissue and ceramic, the structures must be capable of being altered to receive a material that combines the surfaces, thus creating a perfect interface.[1] The adhesive ability of the restorative material to be bonded to tooth structure is referred to as "biomimetic."[2]

Myth

Stacked feldspathic veneers lead to periodontal issues because they are usually over-contoured.

Reality

Bulky veneers should always be avoided, because they may appear unnatural.[3] Therefore, prominent cervical contours must be carefully flattened to avoid over-contouring the final restoration.[4]

Also, when the veneers are placed without preparation, periodontal problems can occur as a result of over-contoured teeth with unnatural emergence profiles.[5] For no-preparation veneers, the esthetic results are variable; some of these restorations can appear too bulky and over-contoured,[6] while others have relatively acceptable esthetics.[4,6]

A wax-up is indispensable for every esthetic dental plan. For cases where a minimal preparation is planned, the procedure must be done with the additive technique. Prior to planning a wax addition, the dentist must carefully consider the initial evaluation of the case, which addresses the teeth's characteristics, the patient's smile, patient's age, opposite arch, and gingival architecture.[7]

To maintain a tooth's original shape, a clinician is often required to remove a slight to moderate amount of enamel when making preparations.[8] Some clinicians feel that a more optimal esthetic potential can be achieved when teeth are prepared with a light chamfer, especially at the gingival margin, which arguably prevents over-contouring in that region **(Figs 1-2b)**.[8]

In the laboratory, it is very difficult to fabricate a veneer less than 0.3 mm thick.[6] Therefore, to preserve the health of the gingival tissues and prevent over-contouring, a slight 0.5-mm reduction of tooth surface has been found to work best.[8] Because feldspathic veneers are typically 0.5 mm, the lost tooth structure is replaced and the original emergence profile is nearly restored.[9] After cementation, the laminate veneers should mimic the patient's natural dentition **(Fig 3)**.

However, in a study comparing teeth restored with porcelain veneers, both with and without preparation, it was reported that there were no differences in terms of periodontal health.[10]

Figure 1: Preoperative image of the anterior teeth showing extensive composite restorations.

Figures 2a & 2b: Facial and incisal views of minimal preparations with a light chamfer finish line; this practice guarantees correct tooth morphology and a natural emergence profile.

Figure 4: When placing the 10 lithium disilicate veneers in sequence and using special illumination, the thinness of the restorations is evident.

Myth

Feldspathic veneers are weak porcelain restorations that are more prone to failure due to chipping and fracture than pressed veneers.

Reality

Many clinicians face difficulties during try-in and bonding procedures with feldspathic porcelain veneers. A major concern is their strength, which is only approximately 70 MPa to 90 MPa,[11] making feldspathic veneers more prone to failure before bonding than pressed veneers. The development and improvement of pressable lithium disilicate material with flexible strength of approximately 400 MPa has reintroduced the concept of less preparation for laminate veneers. Lithium disilicate permits the technician to build a pressed restoration as thin as 0.3 mm while still ensuring a strength of 400 MPa **(Fig 4)**.

This ceramic can be carefully reduced, using rubber wheels and special burs, to less than 0.2 mm with proper resistance. Consequently, it can be placed and bonded with much less risk compared to traditional porcelain, which is made via the refractory die technique.[1] The final morphology of the restorations is injected with lithium disilicate, and all the characterization (fixation) is performed. The color and fitting can be evaluated and modified during the try-in procedures, with low risk of compromising the strength or fitting after many bakes. After fixation, two layers of glaze powder are applied to protect the characterization. Lithium disilicate is indicated for veneers with conventional preparation or no preparation to improve the esthetics and reestablish the anterior guidance **(Figs 5a-6c)**. The disilicate-based materials maximize these benefits for laboratories and dentists.

Figures 5a & 5b: Enamel defects across the surfaces of the anterior maxillary and mandibular incisors. Note the diastemas between teeth and the discrete excess gingival tissue in the mandibular premolar areas.

Myth

Feldspathic porcelains are too translucent to block out discolored teeth.

Reality

Thin laminate veneers cannot easily mask severe staining and discoloration (such as severe tetracycline staining)[12] without adding thickness to the veneers. If thin veneers are constructed, the final result in these cases is often compromised due to the use of underlying opaque porcelain; the veneers typically exhibit a very high value and lack of vitality.[4]

Color discrepancy is due to the veneer's relative thinness and opaque quality; light passing through it can make the color of the underlying preparation show through.[7] If the patient requests a significant shade change, the dentist must overcome the color discrepancy by deepening the preparation and increasing the thickness of the restoration.[4,13,14] This enables the technician to block out the underlying tooth color and achieve the desired color change **(Figs 7 & 8)**.[12]

Myth

The contraction stress generated from curing the adhesive composite or cement used for bonding the restoration can fracture a feldspathic veneer.

Reality

Besides fixing a restoration in place, an important function of dental luting cements is to seal the gap between tooth and restoration. However, as a result of adhesion, curing contraction is hindered, creating stress.

Shrinkage stress in composite restorations, generated during setting, continues to be a major problem in adhesive dentistry.[15,16] Excessive shrinkage stress on the tooth cusps, caused by wall-to-wall contraction, may lead to cuspal distortion, marginal discrepancies, postoperative hypersensitivity, and microleakage.[17,18] Indirect, esthetic, bonded restorations can overcome these problems by limiting contraction stress of the polymerization reaction to the thin resin-cement layer.[19,20]

It is logical to assume that interfacial stresses will then be reduced for composites cured in cavities with minimally constrained surface areas.[21] A ceramic that is sufficiently and evenly thick, combined with a minimally thick luting composite, will provide the restoration with a favorable configuration and reduce the likelihood of cracks.

Figures 6a-6c: Final result after cementation. Note the tissue integration and importance of canine guidance to maintain occlusal stabilization.

Conclusion

Medium- to long-term maintenance of porcelain veneer esthetics is excellent, patient satisfaction is high, and feldspathic porcelain veneers and lithium disilicate material have no adverse effects on the gingival health of patients with optimal oral hygiene.

An optimal bonded restoration can be achieved, especially if the preparation is located completely in the enamel, correct adhesive procedures are carried out, and a suitable luting composite is selected.[22] Based upon their high esthetic value and minimal preparation requirements, these materials allow dentists and technicians to provide esthetic treatments that are much less invasive—which is precisely what patients want.[23]

Figure 7: A lateral incisor with severe discoloration after endodontic treatment.

Figure 8: This final result was achieved due to deep preparation, which produced a veneer with adequate thickness. Selecting an appropriate shade of luting resin cement is important to obtain satisfactory esthetic results.

References

1. Adolfi D, Andrade OS. Lithium disilicate veneers: a case report with no teeth preparation. Spectr Dialogue. 2011;10(9):18-35.
2. Magne P, Belser UC. Bonded porcelain restorations in the anterior dentition: a biomimetic approach. Hanover Park (IL): Quintessence Pub.; 2002.
3. Christensen GJ. Facing the challenges of ceramic veneers. J Am Dent Assoc. 2006 May;137(5):661-4.
4. Strassler HE. Minimally invasive porcelain veneers: indications for a conservative esthetic dentistry treatment modality. Gen Dent. 2007 Nov;55(7):686-94; quiz 95-6, 712.
5. DeLopez TE. Predictable pressed ceramic anterior restorations: clinical observations. Dent Today. 2002 Apr;21(4):68-73.
6. Christensen GJ. Has tooth structure been replaced? J Am Dent Assoc. 2002 Jan;133(1):103-5.
7. Gurel G. The science and art of porcelain laminate veneers. Hanover Park (IL): Quintessence Pub.; 2003.

8. McLaren EA. Porcelain veneer preparations: to prep or not to prep. Inside Dent. 2006;2(4):76-9.

9. DiMatteo AM. Prep vs. no-prep: the evolution of veneers. Inside Dent. 2009;5(6):72-9.

10. Yu X, Oullet D, Ibsen R. Perio evaluation of long-term prep versus non-prep porcelain veneer restorations. J Dent Res. 1998;77(Spec. Iss.):954.

11. Giordano R. A comparison of all-ceramic restorative systems. J Mass Dent Soc. 2002 Winter;50(4):16-20.

12. Javaheri D. Considerations for planning esthetic treatment with veneers involving no or minimal preparation. J Am Dent Assoc. 2007;138(3):331-7.

13. Dozic A, Kleverlaan CJ, Meegdes M, van der Zel J, Feilzer AJ. The influence of porcelain layer thickness on the final shade of ceramic restorations. J Prosthet Dent. 2003 Dec;90(6):563-70.

14. Cavanaugh RR, Croll TP. Bonded porcelain veneer masking of dark tetracycline dentinal stains. Pract Periodontics Aesthet Dent. 1994;6(1):71-9; quiz 80.

15. Bowen RL, Rapson JE, Dickson G. Hardening shrinkage and hygroscopic expansion of composite resins. J Dent Res. 1982 May;61:654-8.

16. Hansen EK. Contraction pattern of composite resins in dentin cavities. Scand J Dent Res. 1982 Dec;90:480-3.

17. Peumans M, Van Meerbeek B, Lambrechts P, Vanherle G. The five-year clinical performance of direct composite additions to correct tooth form and position. part I: esthetic qualities. Clin Oral Investig. 1997 Feb;(1):12-8.

18. Pincus CR. Building mouth personality. J South Calif Dent Assoc. 1938;14:125-9.

19. Simonsen RJ, Calamia JR. Tensile bond strength of etched porcelain. J Dent Res. 1983;62:297, abstract 1154.

20. Horn RH. Porcelain laminate veneers bonded to etched enamel. Dent Clin North Am. 1983 Oct;27:671-84.

21. Ferracane JL. Developing a more complete understanding of stresses produced in dental composites during polymerization. Dent Mater. 2005 Jan;21:36-42.

22. Peumans M, Van Meerbeek B, Lambrechts P, Vanherle G. Porcelain veneers: a review of the literature. J Dent. 2000;28:163-77.

23. McLaren EA, LeSage B. Feldspathic veneers: what are their indications? Compend Contin Educ Dent. 2011 Apr;32(3):44-9. **jCD**

> "An optimal bonded restoration can be achieved, especially if the preparation is located completely in the enamel, correct adhesive procedures are carried out, and a suitable luting composite is selected."

Dr. Adolfi is the director of Spazio Education in São Paulo, Brazil. He also has a private practice in São Paulo.

Disclosure: The author did not report any disclosures.

> **"Dentists must embrace the responsibility of understanding the myths and realities of the different ceramic materials available, their benefits, and their limitations."**

Dr. Fradeani Discusses the Realities of Pressed Porcelain Veneers

With the increase in cosmetic procedures, questions often arise regarding the least technique-sensitive yet most durable and esthetic veneering materials available. Depending upon the material in question, veneer preparations traditionally required anywhere from 0.3 mm to 1.5 mm of natural tooth reduction to provide successful restorations that appeared consistent with the surrounding dentition. Recently introduced materials, however, demonstrate many advantages compared with traditional materials. For instance, with some pressed ceramic materials, the clinician can provide a successful veneer restoration with a coping as thin as 0.16 mm.

Today's dentists often are too busy (or satisfied with the status quo) to invest the much-needed time to educate themselves about the myriad material properties, advantages, and nuances of each newly introduced material. However, to provide their patients with the most successful, minimally invasive treatments available, dentists must embrace the responsibility of understanding the myths and realities of the different ceramic materials available, their benefits, and their limitations.

Myth

Pressed veneers require more aggressive preparation than other restorative modalities.

Reality

Because a core is required upon which to layer porcelain and because porcelain can be layered from zero to virtually any thickness, it is true that pressed veneers have traditionally required more aggressive preparation. Until more recent materials were developed, blending pressable ceramic materials with surrounding dentition required extra room—and therefore tooth reduction—to provide space to esthetically apply veneering porcelain to the pressed ceramic.[1,2] To maintain the natural emergence profiles while achieving acceptable esthetics, more aggressive tooth preparation proved necessary.[1,3] While feldpathic veneers required only 0.3 mm to 0.5 mm reduction of natural tooth structure, some authors believe that pressed ceramics require a minimum of 0.75 mm.[1,4] However, many practitioners, including this author, who use such material, especially the more recent glass ceramics (lithium disilicate), observed that the monolithic version of this material can be thinned down to 0.2 mm to 0.3 mm without any clinical problem if it is bonded on enamel. Moreover, when considering veneer preparations, several factors must be considered, including space requirements, working thickness, and amount of dentin exposed.[5] As a result, case requirements vary from patient to patient and often veneer preparations—even for pressed ceramics—can be much thinner.

In many cases, pressed veneers are used to add volume to the original teeth. In fact, this author uses pressed veneers quite often to add volume when patients request a fuller, more prominent smile. In such cases, most of the time the thickness exceeds 1 mm. In these cases it is possible to easily gain enough space for both the coping and veneering material.

Myth

Pressed veneers lack the capability to produce the lifelike optical metamerisms that feldspathic porcelain can offer.

Reality

Prior to the development of the pressed ceramic veneer material available today, this was true. However, in the modern world of glass ceramics, there are numerous ingots available that allow blending of a veneer with the patient's surrounding natural dentition **(Figs 1-3)**. For instance, lithium disilicate ingots (IPS

Figure 1: Initial view showing an unsatisfactory esthetic and structural appearance.

Figure 2: The patient was treated with a full-mouth rehabilitation that required fabrication of six anterior veneers in the lower arch.

Figure 3: The final view shows a satisfactory esthetic result, with a more harmonious anatomy, better alignment, and overall esthetic and biological integration.

e.max, Ivoclar Vivadent; Amherst, NY) are available in high translucency, low translucency, medium opacity, and high opacity, as well as in values 1, 2, and 3. With such a variety of shades, translucencies, and opacities, it is easy to match the appropriate translucency, color, shade, and nuance to achieve a highly esthetic and prominent smile for the patient. In fact, when providing treatment for a posterior restoration, in most cases it is possible to choose a monolithic material and eliminate layering the coping and still obtain a superb result.

Although it is true that feldspathic porcelain offers outstanding optical qualities, its lack of strength must be considered. Feldspathic porcelain veneers demonstrate the lowest strength of all available veneer materials at 70 MPa to 90 MPa;[1,6] whereas the strength of leucite-reinforced glass-ceramic is approximately 180 MPa in vitro, which is much stronger; and that of lithium disilicate is approximately 400 MPa. Glass-ceramic porcelain is strong and durable, and with sufficient tooth structure and enamel to provide support and retention, failure rates due to fracture or breakage are extremely low.[7-10]

Myth

The cut-back technique to produce incisal characterization for pressed porcelain veneers is more prone to fracture than feldspathic veneer restorations.

Reality

In this author's experience, that has not proven true. In fact, pressable ceramics were developed to address the lack of strength in feldspathic veneer restorations.[1,2] It has already been established from clinical research that leucite-reinforced glass-ceramic (IPS Empress), the first of the new generation pressable ceramics, has demonstrated an outstanding success rate of approximately 95%.[9,10] Pressed porcelain veneers are strong and durable and suitable for a wide range of dental restorations.[1,2] Specifically manufactured with increased density, they demonstrate flexural strengths up to 180 MPa, resisting fracture and providing more durable restorations than feldspathic veneers.[1,2]

Due to its composition, higher density, and superior edge strength, a third generation of pressable ceramic material, such as lithium disilicate, boasts a strength of 400 MPa and can be finished thinner without chipping. Today, this author relies more and more upon lithium disilicate, which demonstrates more strength in vitro than leucite-reinforced glass-ceramic. Therefore, fracturing or chipping of pressable ceramic veneers fabricated with these materials is of very little concern.

Myth

Because of the addition of leucite crystals in pressed ceramic systems, it lessens the amount of silica for bonding, making pressed ceramic restorations less bondable than feldspathic.

Reality

In 1990, laboratory technician Giancarlo Barducci and this author were one of the first teams to test leucite-reinforced glass-ceramic (IPS Empress) in Europe. Bonding, even when using the techniques popular more than 20 years ago, never proved an issue. Data from many clinicians has proven that, regardless of whether clinicians bond feldspathic porcelain or pressed ceramic, as long as the adhesive step is performed properly, a durable and lasting bond will be obtained.[11] It is true that the concentration of leucite within the pressed ceramic correlates to the strength of bond between the resin composite cement and the etched porcelain.[11] In fact, porcelain manufactured with a high-leucite content was introduced in an effort not only to improve material properties but also to increase the strength of the bond between the porcelain and resin composite cement.[11] High-leucite content porcelain material demonstrates between 49% and 51% leucite concentration, while leucite content in feldspathic porcelain will vary from 20% to 30%.[11] When porcelain contains a high-leucite content, etching generates an increase in smaller micro-porosities that may provide a stronger bond to resin composite.[11]

Materials available today provide solutions to many challenges when restoring dentition, and dentists consider more than just the adhesive issue when choosing a material. There are several factors considered with each individual restoration. Among glass ceramics, lithium disilicate is four times stronger than feldspathic porcelain. Its use is recommended especially in cases where there is an insufficient quantity of enamel substrate, and when a considerable amount of tooth length is needed. Moreover, consider a technician who must fabricate six veneers with feldspathic porcelain, and the case must be delivered the next day. If something is wrong with the color, in most such cases, it cannot be corrected. Therefore, the restorations will need to be remade and the case will not be delivered on time. On the other hand, with a glass-ceramic restoration such as a leucite crystal or lithium disilicate ceramic, the color can be changed by relayering the restoration, and the case delivered on time. Clinically speaking, for the dentist, the technician, and the patient, it is much easier to finalize a case using glass-ceramic materials.

Additionally, studies have indicated that for feldspathic veneers to achieve a successful bond, at least 50% of the enamel is required to bond to the substrate, and at least 70% of the margin must be positioned within the enamel.[1,2] Today, with a strong material such as lithium disilicate, clinicians can remove less tooth structure and retain as much enamel as possible—also on the posterior areas—to create durable, completely enamel overlays or even full-crown design, as in the minimally invasive prosthetic procedure (MIPP) technique.[12] By reducing the thickness of the lithium disilicate in full anatomy of the posterior to 0.8 mm, it is possible to still bond onto the enamel. This provides enhanced restorative strength that can be compared to a posterior crown with 1.5 mm thickness that is cemented completely to dentin. Therefore, using a durable monolithic material with this technique maintains the structure and anatomy of the tooth while preserving the enamel and providing a much less invasive, yet successful, treatment.

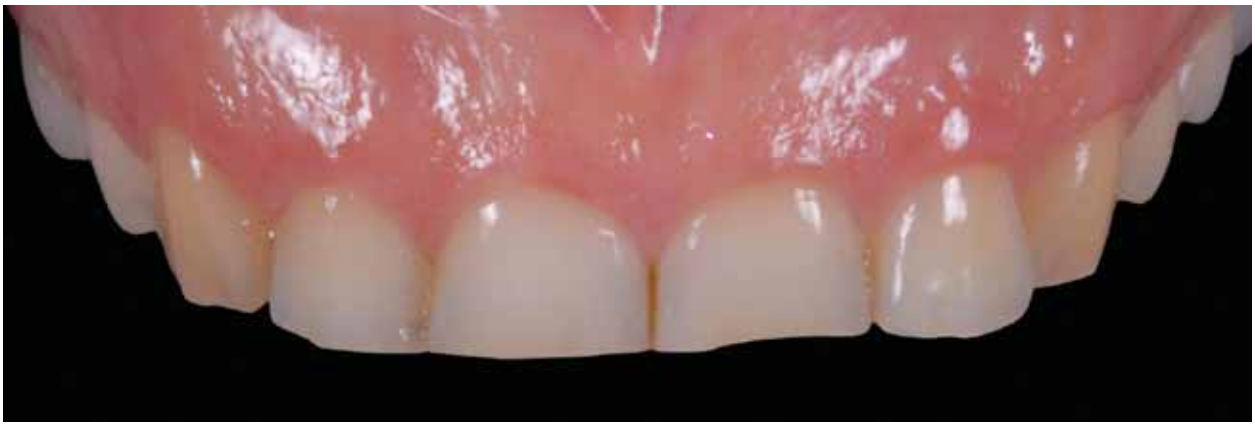

Figure 4: The patient exhibits a flat reverse incisal edge due to tooth attrition.

Figure 5: The tooth preparation shows complete maintenance of the enamel substructure, which will be fundamental in achieving the best bonding.

Figure 6: The thickness of the six anterior veneers exceeds 1 mm in some areas due to the addition of volume in the incisal and buccal areas.

Figure 7: The strength of the ceramic material played a very important role in this clinical case, where the final tooth length was optimized courtesy of a substantial amount of unsupported ceramic (4 mm).

Conclusion

With myriad dental materials available, dentists have an abundance of choices for restoring affected dentition. Contingent upon tooth location, treatment modality, and esthetics, as well as other circumstances, often more than one material is required for treatment. With the concept of minimally invasive dentistry guiding treatment today, multifaceted and versatile materials are continually being introduced. Earlier materials still serve successfully for certain indications, but when pressed ceramic materials are available, dentists can consider their many advantages. Although feldspathic porcelain is hailed for its esthetic properties, pressed ceramics demonstrate enhanced physical properties, stronger flexural strength, and fracture toughness **(Figs 4-7)**; provide durability and, now, enhanced esthetics; and have proven successful for many indications.

References

1. McLaren EA, LeSage B. Feldspathic veneers: what are their indications? Compend Contin Educ Dent. 2011 Apr;32(3):44-9.

2. McLaren EA, Cao PT. Ceramics in dentistry—part 1: classes of materials. Inside Dent. 2009;5(9):94-103.

3. Roulet JF, Degrange M. Adhesion: The silent revolution in dentistry. Hanover Park (IL): Quintessence Pub.; 2000.

4. Friedman MJ. A 15-year review of porcelain veneer failure—a clinician's observations. Compend Contin Educ Dent. 1998;19(6):625-30.

5. LeSage B, Wells D. Two viewpoints on prepared veneers and prep-less veneers. J Cosmetic Dent. 2011 Summer;27(2): 66-76.

6. Giordano R. A comparison of all-ceramic restorative systems. J Mass Dent Soc. 2002;50(4):16-20.

7. Cho GC, Donovan TE, Chee WW. Clinical experiences with bonded porcelain laminate veneers. J Calif Dent Assoc. 1998 Feb;26(2):121-7.

8. Strassler HE, Nathanson D. Clinical evaluation of etched porcelain veneers over a period of 18 to 42 months. J Esthet Dent. 1989 Jan;1(1):21-8.

9. Fradeani M. Six-year follow-up with Empress veneers. Int J Periodontics Restorative Dent. 1998;18:217-25.

10. Fradeani M, Redemagni M, Corrado M. Porcelain laminate veneers: 6- to 12-year clinical evaluation—a retrospective study. Int J Periodontics Restorative Dent. 2005 Feb;25(1):9-17.

11. Lopes MB, Sinhoreti MA, Correr Sobrinho L, Consani S. Comparative study of the dental substrate used in shear bond strength tests. Pesqui Odontol Bras. 2003 Apr-Jun;17(2):171-5. Epub 2003 Oct 10.

12. Fradeani M, Barducci G, Bacherini L, Brennan M. Esthetic rehabilitation of a severely worn dentition with minimally invasive prosthetic procedures (MIPP). Int J Periodontics Restorative Dent. 2012 Apr;32(2):135-47. **jCD**

Dr. Fradeani is associate editor of *The European Journal of Esthetic Dentistry*. A past president of the European Academy of Esthetic Dentistry and of the Italian Academy of Prosthodontics, he maintains a private practice specializing in esthetics and prosthetic rehabilitation in Pesaro, Italy.

Disclosure: Dr. Fradeani is a consultant for and receives material support from a number of companies, including Ivoclar Vivadent. He did not, however, receive any financial remuneration for this article.