Collaboration, Communication, and Conservative Protocol for Predictable Veneers


by Wade A Pilling, DMD
Meridian, ID
www.loveyoursmileidaho.com

Bradley L. Jones, AAACD
Boise, ID
www.secondonlytonature.com

Introduction

Porcelain restorations are usually the ultimate solution for most cosmetic dentistry patients. The ability to change the dimensions, color, contour, function, and characteristics of a patient's smile is unmatched by any other material. Porcelain restorations may be provided conservatively and still retain their strength and beauty[1]. By following the proper protocol, the dentist can remain in complete control throughout the entire process and be assured of the final outcome.

By following the proper protocol, the dentist can remain in complete control throughout the entire process and be assured of the final outcome.

Doing so is especially important today, when the use of the Internet means that patients have become far savvier than in the past. They are starting to realize that achieving the world's most beautiful smile requires a great team of two professionals: The clinician and the ceramist whose artistic skills fabricate the restorations.

Diagnosis and pre-planning are the most important steps to enable the clinician and the ceramist to visualize and determine the final results before a bur even touches the tooth. This is critical in preventing the well-known "prep and pray" technique.

Case Presentation

A 25-year-old female—a dental hygienist and Miss Idaho USA pageant contestant—presented with no significant findings and in excellent health (Figs 1 & 2). She had congenitally missing maxillary lateral incisors and

Figure 1: Preoperative full-facial view of the patient's natural smile.

had undergone orthodontics as a child to mesialize the canines and close the spaces.

Diagnostic records were taken and a comprehensive oral examination was completed. Records gathered included a panoramic radiograph with bitewings and selected periapicals. Also included were photographs, polyvinyl siloxane (PVS) impressions, facebow, and stickbite.[2]

Clinical Findings

Clinical evaluation revealed excellent periodontal health, which was expected. No decay was evident upon oral and radiographic examination. She presented with a few minor occlusal fillings and no pathological wear. She also presented with some previous contouring and composite bonding on her canines to make them appear more like laterals. She demonstrated a Class I molar relationship, but lacked canine relationship due to her mesialized canines. She also lacked immediate canine rise due to the premolars being in the canine position; this resulted in poor coupling due to their anatomy. The temporomandibular joint had no pain upon examination and no history of pain or sounds.[3]

The patient's esthetic examination revealed tooth size discrepancies due to malposition.

Esthetic Findings

The patient's esthetic examination revealed tooth size discrepancies due to malposition. Her tooth color was good, but she wanted veneers that would be even whiter. Due to her mesialized canines, she lacked central dominance. Her canines had a large cervical bulge that created a look of wide canines and thinner centrals. She exhibited uneven gingival heights such that the gingival margins sharply moved incisally as her smile transitioned from anterior to posterior (Fig 3).[4]

Treatment Plan

The treatment goals included providing the patient with a bigger smile, one with more pleasing tooth proportions and more ideal gingival heights. Another goal was to provide canine-protected occlusion. The treatment would include crown lengthening on the bicuspids to create better proportions, followed by some touch-ups using a diode laser. After a period of healing, eight indirect porcelain veneers would be placed to address the issues of tooth proportion and display.[5]

Before any treatment was initiated, PVS impressions were taken and the models mounted on an articulator. They were then waxed using an additive/reductive technique.

Because the patient was a hygienist and pageant contestant, she had certain expectations of how her new smile should look. The patient visited the laboratory multiple times to ensure that the restorations looked the way she wanted before any prep-

Figure 2: Preoperative 1:2 view of the patient's smile. Note the appearance of wide canines and narrow centrals.

Figure 3: Preoperative retracted view showing the uneven gingival architecture.

Figure 4: Following crown lengthening on the bicuspids, the patient demonstrated a new gingival architecture.

Figure 5: Occlusal view of the preparations on teeth ##4-13.

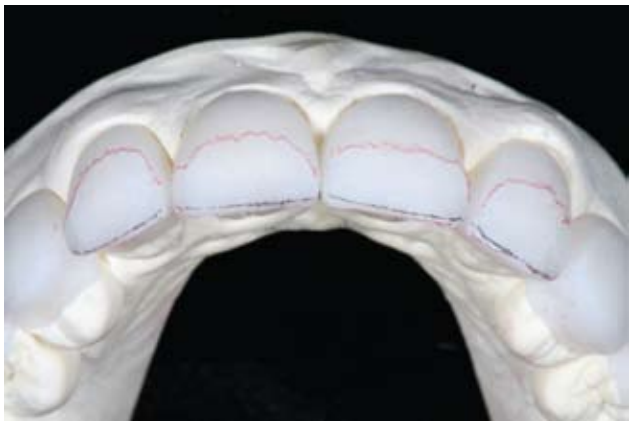

Figure 6: View of the initial .5-mm facial bevel back.

Figure 7: A tapered diamond was used to undercut under the halo.

Figure 8: Effects were brushed in, and halo material was placed on the facial incisal edge.

Figure 9: Enamel material was placed over the fired effects to full contour.

arations were initiated. She desired the bleach shade of Ivoclar Vivadent 020 (Amherst, NY) to match her adjacent bleached dentition. An integral part of the process, the patient communicated her desires about tooth shapes and contours, which she was later able to approve in the form of her provisionals.

A silicone putty matrix of the diagnostic wax-up was used to create the temporary restorations. A model and putty stent of the wax-up were made, which was used to create a mock-up in the patient's mouth so she could preview her new smile. After approval from her and verification from us, she was scheduled for her treatment appointment.

Armamentarium

- 4.3X magnification loupes (Designs for Vision; Ronkonkoma, NY)
- EOS Digital Rebel Camera (Canon USA; Lake Success, NY)
- Penta Quick Position PVS impression material (3M ESPE; St. Paul, MN)
- yellow stone
- facebow (Panadent; Grand Terrace, CA)
- semi-adjustable articulator (Panadent)
- AccuFilm articulating paper (Parkell; Edgewood, NY)
- Sil-Tech putty impression material (Ivoclar Vivadent; Amherst, NY)
- Imprint II and Imprint III impression material (3M ESPE)
- Optragate cheek and lip retractor (Ivoclar Vivadent)
- Protemp temporary material (3M ESPE)
- Luxa Glaze (Zenith/DMG; Englewood, NJ)
- Septocaine with 1:100,000 epinephrine (Septodont; New Castle, DE)
- Navagator diode laser (Ivoclar Vivadent)
- Diamond burs, Hornbrook Group Anterior Preparation Kit (Brasseler USA; Savannah, GA)
- Dialite ceramic polishers, Hornbrook Group Anterior Finishing Kit (Brasseler)
- Vita 3D master shade guide (Vident; Brea, CA)
- Superoxol hydrogen peroxide (EPR Industries Chemists; Pennsauken, NJ)
- Viscostat clear hemostatic agent (Ultradent Products; South Jordan, UT)
- Flexi Discs (3M ESPE)
- Consepsis chlorhexidine rinse (Ultradent)
- micro etcher (Danville Engineering; San Ramon, CA)
- Ultra-Etch 35% phosphoric Acid (Ultradent)
- Silane (3M ESPE)
- Single bond (3M ESPE)
- Solo bond (3M ESPE)
- Curing light light-emitting diode (LED) (3M ESPE)
- RelyX veneer cement, translucent shade (3M ESPE)
- #12 Bard Parker blade (Becton Dickinson; Franklin Lakes, NJ)
- DeOx oxygen-barrier gel (Ultradent)
- Ceri Saw (Den-Mat Corp; Santa Maria, CA)
- Glide Floss (Gore; Flagstaff, AZ)

Treatment

Surgery

The patient was referred to a periodontist for clinical crown lengthen-

Figure 10: View of the bisque bake with surface morphology.

Figure 11: Retraced postoperative view demonstrating the enhanced look of the patient's smile.

ing of the bicuspids and some minor recontouring of the canine roots in order make their emergence profile mimic that of a lateral incisor (Fig 4).[6] After eight weeks of healing, minor recontouring was completed using a diode laser. A probe was used to sound the bone so as not to invade the biological width. Another four weeks was allowed before initiating the preparations.

Preparation

Using the putty matrix made from the additive/reductive model, the mock-up was again reproduced intraorally. This matrix was trimmed and verified again and used as a guide for depth cuts so that the teeth were prepared with the final result in mind.

The patient was anesthetized with lidocaine with 1:100,000 epinephrine. A cheek and lip retractor was used during preparation. Depth cuts of 0.5 mm were placed on the facial of teeth ##4-13 (Fig 5).[7] The preparations were finished using diamond burs, and reduction was verified with a clear matrix. Impressions were taken using PVS impression material. Facebow and stickbite records were also taken. Temporary veneers were placed using the shrink-to-fit technique, the putty stent, and temporary material in a bleach shade. After about three minutes of curing, the stent was removed, after which the excess flash was removed. Margins were then polished and the bite adjusted.[8]

The treatment goals included providing the patient with a bigger smile, one with more pleasing tooth proportions and more ideal gingival heights.

Follow-Up

The patient was seen 48 hours later to evaluate the temporaries. After some minor adjustments and receiving her final approval, PVS impressions were taken of the temporaries to communicate to the laboratory the desired final results. Photographs were taken of the patient in temporaries to help convey her expectations.

Laboratory Fabrication

Wax was injected through a matrix made from the cast of the approved provisionals onto the lubricated and separated (but not trimmed) master dies. After the waxed restorations were finalized, they were separated and removed from the dies. The master dies then were trimmed so that the wax restorations' margins could be sealed.

Pressable ceramic (Pulse B00+, Jensen Industries; North Haven, CT) was used and, through the lost wax process, a natural 020 shade was achieved. These pressed-to-full contour restorations were then cut back and layered (Figs 6-10).[9]

Delivery

The patient arrived for delivery of the definitive restorations two weeks later. Each restoration was inspected on the model for esthetics, fit, and form. The patient was then lightly anesthetized with lidocaine with epinephrine 1:100,000. The temporaries were removed with hemostats, and the preparations were

Figure 12: Postoperative right lateral view of the patient's new smile.

then cleaned using an antimicrobial scrub and 30% hydrogen peroxide.

Each veneer was tried in separately to inspect fit, and then all together to evaluate contacts. They were then tried in with translucent try-in paste. At this point the patient again evaluated the restorations and gave her approval.

The veneers were then removed and cleaned, etched, and silanated. The teeth were also cleaned again and isolated using a split rubber dam. After the veneers were cleaned they were each treated with bonding agent and veneer cement and placed in a light safe box. The teeth then were etched using 37% phosphoric acid and bonded.

The veneers then were placed and fully seated using the tack-and-wave technique. Excess cement was cleaned and polished; margins were covered with oxygen-barrier gel and received a final light-cure. The occlusion was verified and adjusted.

The patient was seen 24 hours later for evaluation. Final photographs were taken two weeks later (Figs 11 & 12).

Conclusion

The patient loves her new smile and teeth and feels they fit her personality and idea of perfection. In delivering porcelain veneers in this case, we were able to correct all of the patient's concerns and achieve a great cosmetic result. Additionally, by following the proper protocol, the process was smooth and predictable.

References

1. Magne P, Belser U. *Bonded Porcelain Restorations in the Anterior Dentition: A Biomimetic Approach*. Hanover Park, IL: Quintessence Pub.; 2002.
2. Dawson PE. *Evaluation, Diagnosis, and Treatment of Occlusal Problems* (2nd ed.). St. Louis, MO: Mosby; 1989.
3. Okeson JP. *Management of temporomandibular disorders and occlusion* (3rd ed.). St. Louis, MO: Mosby Year Book; 1993.
4. Lee EA. Aesthetic crown lengthening: Classification, biologic rationale, and treatment planning considerations. *Pract Proced Aesthet Dent* 16(10):769-778, 2004.
5. Spear FM, Kokich VG. A multidisciplinary approach to esthetic dentistry. *Dent Clin North Am* 51(2):487-505, x-xi, 2007.
6. Kois JC. Altering gingival levels: The restorative connection, Part 1: Biologic variables. *J Esthet Dent* 6(1):3-9, 1994.
7. Broderson SP. Complete-crown and partial-coverage tooth preparation designs for bonded cast ceramic restorations. *Quintessence Int* 25(8):535-539, 1994.
8. Hornbrook DS. Provipont and Provilink. Maximizing aesthetics and function when fabricating provisional restorations. *Signature* 10-16, 1995.
9. O'Brien WJ. *Dental materials and their selection* (4th ed.). Hanover Park, IL: *Quintessence Pub.*; 2008.
10. Hornbrook DS. *Functional Anterior Esthetics* [hands-on live patient course]. Presented by the Hornbrook Group; Louisville, KY, 2005.

Acknowledgments

The authors thank their families and staff for their support; the patient, Melissa, for her confidence in their care; and Dr. Mike Davis for his periodontal surgery treatment. They also acknowledge Chad Transtrum, the photographer hired to take the cover photograph. Finally, they thank the Hornbrook Group for sharing the skills, knowledge, and training necessary to perform this kind of dentistry.[10]

AACD Acknowledgment

The American Academy of Cosmetic Dentistry recognizes Bradley L. Jones as an AACD Accredited Member who has donated laboratory cases to restore the smiles of Give Back A Smile™ survivors.